

# Brain Deficit Seen in Stuttering

BY AMY ROTHMAN SCHONFELD  
Contributing Writer

ATLANTA — Children who stutter have been found to have deficiencies in white-matter organization in a tract that interconnects the frontal speech/motor planning region and the posterior speech comprehension region, suggesting that inefficient connectivity among speech-relevant regions of the left hemisphere may be a possible neuroanatomical basis for stuttering, Soo-Eun Chang, Ph.D., reported in a poster at the annual meeting of the Society for Neuroscience.

Adults who stutter show the same tract abnormalities as do children, but, in addition, they show asymmetry in gray-matter volume, suggesting that the gray-matter findings in adults reflect neuroplastic changes secondary to a lifetime of stuttering.

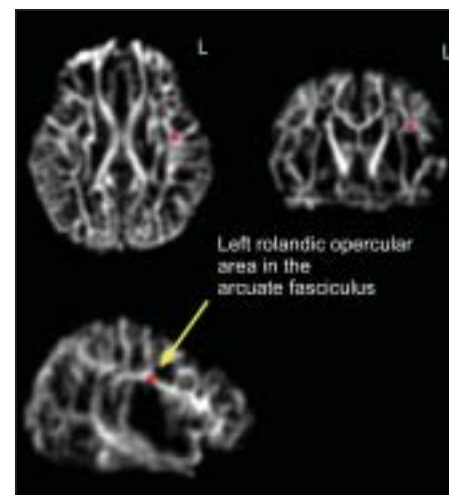
“What this shows is that the adult studies are compromised because there are two things going on: the original deficit, and then the neuroplasticity that is laid on top of that,” Christy L. Ludlow, Ph.D., section chief of the National Institute of Neurological Disorders and Stroke and a

anisotropy abnormality was not related to ongoing stuttering, because no difference was found in this region between the brains of children who recovered and those of children who continued to stutter.

The abnormality indicates a risk for stuttering, not whether there is a chance of recovery from stuttering. “This is a novel finding because there haven’t

been any studies to date looking at the brains of children who stutter. There have only been studies of adults who stutter,” she said.

“Our research suggests that some of the brain-imaging differences found in stuttering adults may be the result of a lifetime of coping with stuttering,” she said. ■



Children with stuttering (both persistent and recovered) had significantly less fractional anisotropy, a measure of white-matter integrity, in rolandic operculum than controls on DWI MRI studies.

COURTESY DR. SOO-EUN CHANG



Findings in stuttering adults may reflect neuroplastic changes from a lifetime of stuttering.

DR. CHANG

coauthor of the study, said in an interview. This gives us a clear picture of what the actual deficit is.”

In their study, 22 monolingual, right-handed boys aged 9-12 years underwent high-resolution, diffusion-weighted imaging (DWI) MRI studies.

The study children fell into three subgroups: normal fluent controls (seven), children who showed persistent stuttering (eight), and children who previously stuttered but had recovered and had been fluent for at least 2 years prior to scanning (seven).

Fractional anisotropy maps were calculated for each subject to delineate tracts; tract-based spatial statistics were also calculated, and regions of interest were analyzed.

When compared with normal controls, children who stutter had reduced white-matter integrity only in the left arcuate fasciculus (a tract that underlies the oral-facial motor regions), as measured by fractional anisotropy.

Studies by other investigators have shown that stuttering adults manifest increased gray-matter volume in the right hemisphere, whereas fluent adults show greater left hemisphere volume.

However, no such gray-matter asymmetry could be found in children, the investigators noted. “In fact, they show less volume in both sides of the brain in speech areas,” which suggests that the initial deficit is different from what people see in adults, said Dr. Ludlow.

The left rolandic operculum fractional

## NEW INDICATION FOR SEVERE AD



## NOW THE FIRST AND ONLY THERAPY FOR THE FULL SPECTRUM OF AD

Mild ■ Moderate ■ Severe

ARICEPT® is indicated for the treatment of dementia of the Alzheimer's type. Efficacy has been demonstrated in patients with mild to moderate Alzheimer's disease, as well as in patients with severe Alzheimer's disease.

Cholinesterase inhibitors have the potential to increase gastric acid secretion. Patients at risk for developing ulcers, including those receiving concurrent NSAIDs, should be monitored closely for gastrointestinal bleeding.

In clinical trials, syncopal episodes have been reported (2% for ARICEPT versus 1% for placebo).

In clinical trials, the most common adverse events seen with ARICEPT were nausea, diarrhea, insomnia, vomiting, muscle cramps, fatigue, anorexia, and ecchymosis. In studies, these were mild and transient.

Please see brief summary of prescribing information on adjacent page.

**ARICEPT**  
(donepezil HCl)

ONCE-A-DAY  
**ODT**<sup>™</sup>  
Orally Disintegrating  
Tablets (5-MG and 10-MG)

Eisai Eisai Inc.  
Teaneck, NJ 07666

Pfizer U.S. Pharmaceuticals  
New York, NY 10017

ARICEPT® is a registered trademark of Eisai Co., Ltd.  
AR279915 © 2006 Eisai Inc. and Pfizer Inc. All rights reserved.

ONCE-A-DAY  
**ARICEPT**  
(donepezil HCl)  
5-MG AND 10-MG TABLETS