

# New Device Described as Objective Test of Pelvic Floor Musculature

BY FRAN LOWRY  
Contributing Writer

FORT LAUDERDALE, FLA. — The Colpexin sphere, an intravaginal device for women with advanced genital prolapse that supports the prolapse above the levator musculature and helps patients strengthen their pelvic floor muscles, can also serve as a test to objectively assess pelvic floor muscle contractility and strength, Dr. G. Willy Davila said at a symposium on pelvic floor disorders sponsored by the Cleveland Clinic Florida.

An objective test of the pelvic floor musculature has long been needed, said Dr. Davila, chairman of the department of gynecology at the Cleveland Clinic in Weston, Fla. Until now, clinicians have had to rely on subjective methods, such as manual testing using the Brink classification system, which was first published in 1989.

"You can see from the date it was published that we really haven't done very much to improve our assessment of pelvic floor contractions," Dr. Davila said.

For the Colpexin sphere pull test to objectively assess pelvic floor musculature strength and tone, a tensiometer is attached to the sphere and then the patient is asked to contract her pelvic floor muscles. The force required to extract the device while the woman is resisting its removal is then measured, explained Dr. Davila, who has received research funding from and is a consultant for Adamed Inc., the maker of the Colpexin sphere.

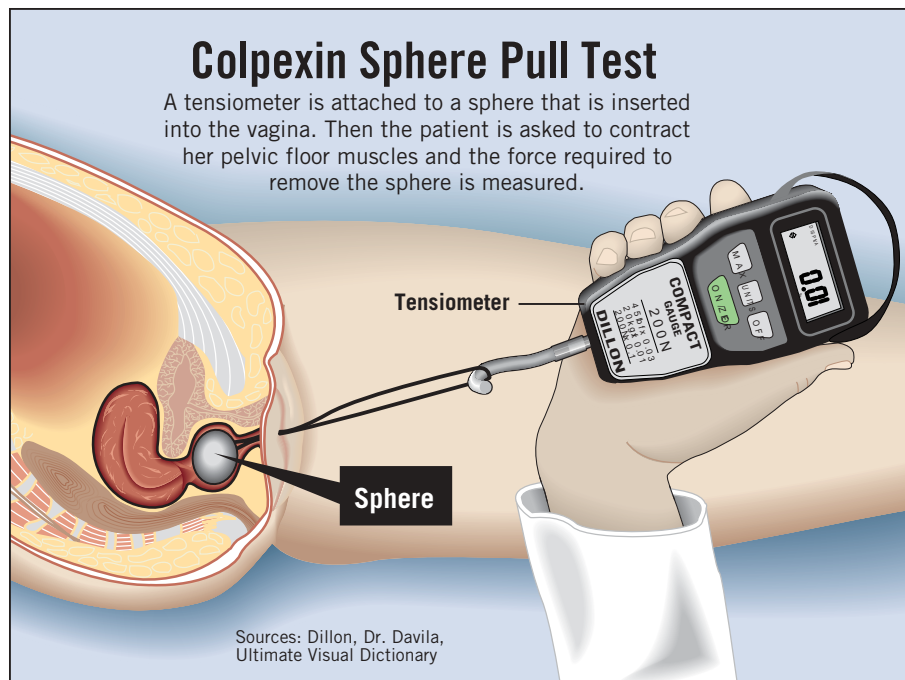
Early results with the Colpexin pull test show a significant improvement in contractile strength over a 16-week period in women with prolapse who performed Kegel exercises regularly with the sphere in place.

"This is the first time that we have had the ability to objectively evaluate pelvic floor strength and to measure improvement over time in our patients," he said.

The Colpexin device, which was developed in Poland, has just won Food and Drug Administration approval and will be marketed within a few months, Dr. Davila said.

He stressed the importance of evaluating pelvic floor muscular function, both before therapeutic intervention for prolapse and as a way of measuring the intervention's success.

"We spend a lot of time and energy in urodynamics with very sophisticated equipment, yet we don't spend a lot of time and energy evaluating their muscular function in the pelvic floor, which is probably equally important," he said. ■



# Consider Duration, Symptoms of Teen Breast Masses

BY MARY ELLEN SCHNEIDER  
Senior Writer

NEW YORK — When evaluating a breast mass in an adolescent, keep in mind that breast cancer is rare in this population and imaging should be limited, Dr. Patricia Simmons advised physicians at a gynecology conference sponsored by Mount Sinai School of Medicine.

Studies looking at the histopathology of young patients who have had surgery for a breast mass show that the most consistent finding is of fibroadenoma, though some showed fibrocystic changes, abscess, and infection, and in very rare cases, malignant diseases, said Dr. Simmons, a professor of pediatrics at the Mayo Clinic in Rochester, Minn.

In the rare case of a malignant mass, it is likely to be the type of tumor found more commonly in young patients, such as primary or metastatic rhabdomyosarcoma, metastatic neuroblastoma, or lymphoma, she said.

In those cases, patients did not discover the masses through self-breast exam but generally presented with constitutional symptoms such as fever, night sweats, and weight loss.

The clinical experience in breast masses in adolescents is largely anecdotal and the surgical experience is limited, Dr. Simmons said. But for the most part, breast masses in adolescent women are benign, cancer is rare, and when cancer occurs, it is generally not carcinoma, she said.

When looking at a breast mass in adolescents, physicians should consider the duration, the constitutional symptoms, and the risk factors for malignancy. Keep in mind that in young women, the risk factors are different, because the patient hasn't lived long enough to develop most of the factors considered in adults, Dr. Simmons said. The risk factors in adolescents are generally cancer history and whether the patient has had chest radiation.

During the physical exam, physicians should assess the mass size and character, breast skin changes, nodes, and organomegaly.

In cases in which the diagnosis is uncertain, imaging will be necessary. However, while a mammogram is the go-to test in adults, this type of imaging is ineffective in adolescents because the young breast is denser and firmer, Dr. Simmons said. An ultrasound will be much more sensitive, she said.

Surgery may be indicated in cases such as a recurring cyst that is symptomatic; a growing, disfiguring mass; suspected cystosarcoma phyllodes; suspected papilloma; suspected papillomatosis; or an abscess.

When considering surgery for a fibroadenoma, physicians should assess the course, the certainty of the diagnosis, any worrisome features, size and distortion, and tolerance, Dr. Simmons said. In a case in which the mass is distorting the breast, surgery is probably the right choice, because it is interfering with normal life, she said. However, she cautioned physicians not to opt for surgery just because the mass is worrisome to the mother.

"I think we need to arm our patients with the facts, and we should be able to alleviate anxiety if that anxiety is misplaced and not take [the fibroadenoma] out just because it's there," she said.

In many cases, it is fine to watch a fibroadenoma in an adolescent patient since most will be benign and not progressive, Dr. Simmons said. "We should be conservative with this population to preserve breast architecture and breast-feeding to the extent we can," she said. ■

# Pelvic Prolapse Linked to Higher Fracture Risk

BY KATE JOHNSON  
Montreal Bureau

TORONTO — Women with pelvic organ prolapse may be at increased risk for fracture, according to a new analysis of data from the Women's Health Initiative trial.

"As a clinician, if I see a woman who is early postmenopausal with moderate to severe prolapse, it would behoove me to get her bone density assessed to quantify her risk for fracture, because now I believe this woman is more likely to have some form of fragility phenomenon happening," said principal investigator Dr. Lubna Pal of Albert Einstein College of Medicine, New York.

The study, which she presented as a poster at the annual meeting of the Society for Gynecologic Investigation, was based on the hypothesis that collagen deficiencies may be a unifying explanation for both pelvic organ prolapse (POP) and enhanced fracture risk in postmenopausal women, Dr. Pal said in an interview.

There is a high incidence of both

prolapse and fractures in collagen-deficiency disorders such as Marfan syndrome and Ehlers-Danlos syndrome, she said. And the connection is biologically plausible, given that 90% of bone is collagen (thus making deficiency a risk factor for fracture) and that qualitative or quantitative deficiencies of tissue collagen may be more common in women with POP, than in women without.

The cross-sectional analysis included 11,096 postmenopausal women aged 60 years or more who were part of the entire WHI cohort. It found moderate to severe POP in 9% of the subjects and fragility fracture (fracture after age 55 years) in 19%.

After adjusting for confounders including age, body mass index, age at menopause, history of osteoporosis, late menarche, hormone replacement and oral contraceptive use, family history of fractures, smoking, nulliparity, and white race, the researchers found a statistically significant association between POP and fracture risk.

Women reporting moderate to severe POP were significantly more like-

ly to have reported ever breaking a bone, compared with women with absent or mild POP (45% vs. 41%), and were also more likely to have reported a fragility fracture (21% vs. 19%), although this association was not statistically significant.

When bone mineral density (BMD) was analyzed in this context, women with moderate to severe prolapse had significantly lower total body and total hip BMD, compared with women who had absent or mild POP. They also had lower lumbar spine BMD—although this difference did not reach significance.

"Maybe as clinicians we should be recognizing this association and focusing on bone health in women who demonstrate genital prolapse," Dr. Pal said.

"We would first of all tell them they are at risk for fracture; [second,] identify any bone problems [that] are treatable; and [third,] try to optimize their bone collagen or protein content with calcium, vitamin D, weight-bearing exercise, and protein intake," she suggested. ■