

## 5-FU Cream Underused In Basal Cell Carcinoma

BY BRUCE JANCIN  
Denver Bureau

KOLOA, HAWAII — Topical 5% 5-fluorouracil cream is a highly effective yet underutilized treatment option for superficial basal cell carcinomas, Dr. Leon H. Kircik said at the annual Hawaii dermatology seminar sponsored by Skin Disease Education Foundation.

It makes particularly strong sense in two patient subgroups in which surgery is not a good option: the frail elderly, and young appearance-oriented patients likely to go ballistic at the sight of the keloidal hypertrophic scar that so often occurs following excision of a skin cancer on the chest, shoulders, or upper back, said Dr. Kircik, a dermatologist in private practice in Louisville.

Topical 5% 5-fluorouracil (5-FU) earned Food and Drug Administration approval for treatment of basal cell carcinoma (BCC) more than 3 decades ago at the same time it received an indication for actinic keratosis.



The pivotal clinical trial demonstrated a 93% histologic cure rate in 113 biopsy-proven superficial basal cell carcinomas.

Dr. Kircik recently conducted a confirmatory trial of his own. It involved 29 patients with 31 biopsy-proven BCCs treated with topical 5% 5-FU b.i.d. for up to 12 weeks. Patients were followed via office visits at 3-week intervals.

Histologic cure was documented in 90% of the lesions. The average time to cure was 10.5 weeks. Four BCCs were cured by week 6, 5 by week 9, and 19 by week 12. At each office visit, most patients said they had no pain at all; the rest characterized the pain as mild. Dr. Kircik rated hypopigmentation and scarring as none to minimal at each visit and erythema as mild to moderate. The most impressive measure of patient satisfac-

tion was that nearly everyone indicated a willingness to repeat the therapy in the future. "That's a pretty good sign," the dermatologist said.

The 90% cure rate with 5-FU in his study is similar to the 93% rate in the older trial. It's comparable as well to the 93% and 90% cure rates with curettage and excision, respectively, reported in large patient series. "The 75%-80% success rate quoted in the package labeling for imiquimod 5% cream is not even close," Dr. Kircik noted. He characterized frail elderly patients with superficial BCC as "perfect" candidates for a topical therapy with a high cure rate.

"I myself as a Mohs micrographic surgeon know the difficulty of taking these patients from the wheelchair and putting them into the surgical chair. Some of them are on Coumadin, some have pacemakers. And it can be very difficult in these patients to use lidocaine with epinephrine," he said.

In the past, the expense of several months of topical therapy was prohibitive for many elderly patients. Under the new Medicare Part D, however, the cost of a course of Efudex is covered, with only minimal out-of-pocket expense to the patient.

The other setting in which Dr. Kircik always considers Efudex is in young people leery of scarring. "These are the sort of patients I sometimes send to the plastic surgeon because I don't want to be the one who's going to be giving them that scar. When you have a non-scarring topical treatment with a 90%-93% cure rate, I think that's a good indication."

Dr. Kircik is a consultant to Valeant Pharmaceuticals International, which markets Efudex.

SDEF and this news organization are wholly owned subsidiaries of Elsevier. ■

**'The 75%-80% success rate quoted in the package labeling for imiquimod 5% cream is not even close.'**

DR. KIRCIK

## Tumor Thickness Can Predict Nodes in Merkel Cell Carcinoma

BY JANE SALODOF MACNEIL  
Southwest Bureau

SAN DIEGO — Tumor thickness correlates with sentinel lymph node status in Merkel cell carcinoma and merits further investigation as a prognostic factor, Dr. Michael D. Alvarado reported in a poster at a symposium sponsored by the Society of Surgical Oncology.

Dr. Alvarado, of the H. Lee Moffitt Cancer Center & Research Institute in Tampa, Fla., presented a retrospective study of 62 Merkel cell carcinoma patients who underwent sentinel lymph node (SLN) biopsies at the center.



Investigators confirmed low recurrence rates in patients with negative SLN status, but found that patients with thicker tumors were more likely to have positive nodes.

Dr. Alvarado said that physicians at the cancer center began documenting thickness in 1998 to see whether it could be used to help stage patients, as is done in melanoma. "For Merkel cell carcinoma, no one really measures thickness," he said. "The staging system is based on the diameter of the tumor and whether or not the nodes are positive."

The study reviewed 62 patients who underwent SLN biopsies between 1994 and 2004. Among them, 41 patients had tumor thickness measurements available for review. Investigators found that 18 of the 41 patients (44%) had positive SLN. These patients also had thicker tumors. The average thickness was 8.9 mm in patients with positive nodes vs. 5.5 mm in those with negative nodes.

No positive nodes were found in five patients with

tumors 2 mm or less in thickness, but "as you increase the thickness, the rate of positive sentinel lymph node goes up," Dr. Alvarado said. (See box.)

He reported two nodal recurrences in the group of patients with tumors 2.1-4.9 mm in thickness and one regional recurrence in a patient whose tumor was in the 5-10 mm group.

One patient with a tumor thicker than 10 mm had a local recurrence. A third nodal recurrence occurred in a patient for whom tumor thickness had not been recorded.

All three patients with nodal recurrences had negative SLN status. The two local/regional recurrences were in

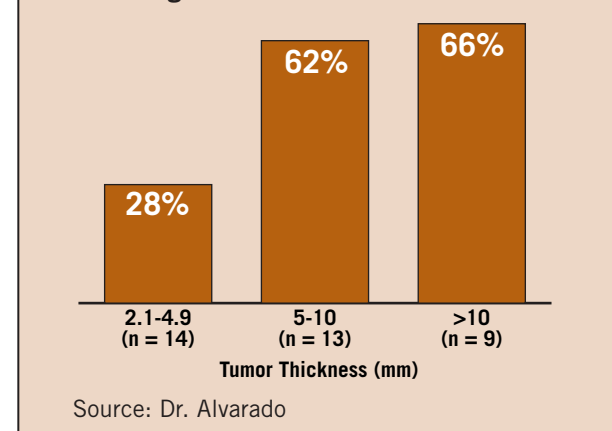
SLN-positive patients, one of whom had radiation to both the primary and nodal basins and one of whom did not receive radiation therapy.

In an interview at the meeting, Dr. Alvarado said that further investigation is needed to determine which patients need SLN biopsy. Although Merkel cell carcinoma is often deadly if it recurs, Dr. Alvarado said that physicians must also be concerned about morbidity from the SLN procedure and the overtreatment of patients who are not likely to have a recurrence. ■

**'As you increase the thickness [of the tumor], the rate of positive sentinel lymph node goes up.'**

DR. ALVARADO

Percentage of Patients With Positive Nodes



## A Black Dot Sign Appears to Flag Early Basal Cell Carcinoma

BY BETSY BATES  
Los Angeles Bureau

LOS CABOS, MEXICO — Jet-black dots that resemble marks from a ballpoint pen may be an easily overlooked sign of basal cell carcinoma, Dr. Jennifer L. Vesper said at the annual meeting of the Noah Worcester Dermatological Society.

Dr. Vesper first noticed the tiny black dots on a 51-year-old female patient's forehead in the vicinity of a suspicious lesion that turned out to be basal cell carcinoma (BCC).

Once she was attuned to looking for them, she began to notice the dots on other patients as well.

"I came to realize even a focus of black pigment, often showing up as a very dark black dot, may be the first sign of basal cell carcinoma," she said.

Since that first patient in 1996, she has documented the dots as a presenting sign of BCC in 14 patients.

"I may or may not see erythema or pearliness upon stretching of the skin," said Dr. Vesper, a dermatologist in private practice in Bradenton, Fla.

In one patient who presented with a typical BCC with focal black dots on the abdomen, Dr. Vesper noticed more small, ink-black, "slightly papular" dots on the patient's chest on otherwise normal-appearing skin. She and the patient agreed that if the abdominal lesion proved to be BCC, another biopsy would be taken of the chest.

The second biopsy confirmed BCC on the chest.

Dr. Vesper examined an 89-year-old patient with a history of three episodes of BCC and found several lesions dotted with pinpoint black pigment. When she biopsied six of the lesions, two revealed pigmented BCC, and three showed superficial BCC. Three of the lesions had clear margins. The patient had no history of radiation or arsenic exposure. Histology of clinically uniform-appearing lesions may show various patterns, including pig-

mented keratinous microcysts, one dot of pigment in a central necrotic tumor nest, pigment in melanophages but not in tumor, or pigment within a tumor and melanophages. Differential diagnosis may include melanoma, compound nevi, angiokeratoma, solar elastosis, or even open comedones.

A biopsy is prudent unless a patient has many dotted lesions, of which some have proved to be BCC, in which case the patient may opt to just have them all removed.

In one case, the biopsy of a lesion with jet-black dots initially came back with a diagnosis of solar elastosis, but after a section, the diagnosis was revised to BCC.

Dr. Vesper reviewed a recent publication chronicling "pigmented speckling" as a distinguishing feature of BCC in 17 patients, 15 of whom had tumors on the head and neck (*Dermatol. Surg.* 2004;30:1553-5). Although these cases were more focused than cases she has seen, she said the report likely reflects her same observations. ■