

Small Thyroid Nodules May Pose High Ca Risk

Preliminary data suggest a possible rise in the risk of papillary carcinoma in nodules of 1 cm or less.

BY PATRICE WENDLING
Chicago Bureau

CHICAGO — Solid thyroid nodules smaller than 1 cm in diameter tend to carry a greater risk of papillary carcinoma than do larger nodules, Dr. Nagesh Ragavendra reported at the annual meeting of the Radiological Society of North America.

The results of this study using fine-needle nonaspiration need to be confirmed in larger investigations as the study was too small to establish statistical significance. But the trend was marked: The risk was 16% for thyroid nodules 1 cm or less in diameter compared with 8% for nodules 1.1 cm or more, Dr. Ragavendra said.

Surprisingly, the study also found that

capsular invasion is relatively common in solid thyroid nodules, said Dr. Ragavendra, professor of radiology and chief of the ultrasound section at the University of California at Los Angeles.

Five of the larger-sized nodules had capsular invasion; two had nodal metastases, he reported.

The biopsies were performed under ultrasound guidance on 598 focal thyroid nodules in 466 consecutive patients using the fine-needle nonaspiration technique with on-site cytologic examination.

With this technique, cells are extracted with a 25-gauge needle that is repeatedly and rapidly advanced into and withdrawn from the nodule. The needle is not connected to external suction, as is the case with traditional fine-needle aspiration, Dr. Ragavendra explained.

Neither technique has been established as superior in the cytopathologic investigation of thyroid nodules. But fine-needle nonaspiration provides specimens that offer larger numbers of cells and have better preserved cytomorphology, he said.

The sample tends to be less blood tinged with nonaspiration than with aspiration fine-needle biopsy. Further, nonaspiration allows continuous monitoring of the position of the needle tip, thus ensuring proper sampling of the area of interest, Dr. Ragavendra added.

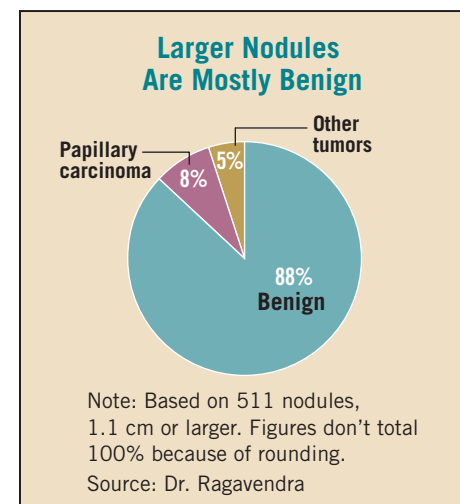
Of the 511 nodules that were 1.1 cm in diameter or larger, histology revealed that 448 (88%) were benign, 39 (8%) were papillary carcinoma, and 24 (5%) were other tumors.

Of the 87 nodules 1 cm or less, 67 (77%) were benign, 14 (16%) were papillary carcinoma, and 6 (7%) were other tumors, he said.

The study does not resolve the long-

standing debate as to which thyroid nodules should be biopsied. But those with some cystic components tend to be benign, Dr. Ragavendra said.

At UCLA, all solid nodules, whether hypoechoic or isoechoic, are candidates for fine-needle biopsy, he said. ■



CLINICAL CAPSULES

Local Anesthesia for Thyroidectomy

Outpatient thyroidectomies performed with local anesthesia on eligible patients can achieve clinical results and patient satisfaction comparable with those done under general anesthesia, according to results of a prospective, randomized clinical trial.

Researchers at Texas A&M University in Temple, Tex., monitored 58 patients at Scott & White Memorial Hospital in Temple who underwent thyroidectomies in 2000-2001. The patients' ages ranged from 19 to 80 years; 53 (91%) were women. Half (29 patients) received local anesthesia while half had general anesthesia (Arch. Surg. 2006;141:167-73).

The researchers found statistically significant differences in the amount of time patients in the two groups spent in post-surgical care: Those who received local anesthesia spent 4 minutes in the postanesthesia care unit, compared with 80 minutes for those treated under general anesthesia. The combined time spent in the postanesthesia care unit and the day surgery unit for those treated under local anesthesia was 165 minutes, compared with 229 minutes for those under general anesthesia.

As a result of the earlier discharge, researchers estimated the per-patient savings at \$315 for those treated with local anesthesia.

The researchers found no statistically significant differences in the number of patients undergoing either procedure who were admitted to the hospital after surgery or in the 30 days after initial discharge, the number of complications, or the overall satisfaction with their surgery or anesthesia management.

EBRT for Local Control of Thyroid Ca

High-dose external beam radiotherapy was effective in controlling locally advanced, differentiated thyroid cancer in a retrospective study of 42 patients.

There is little information on the efficacy of external beam radiotherapy

(EBRT) as adjuvant therapy in such patients, so the treatment is controversial.

"Retrospective outcome studies remain the most reliable way of assessing therapeutic efficacy but are hampered by significant heterogeneity in diagnostic evaluation, staging, and treatment strategies that have evolved over time. Accordingly, the indications for EBRT for differentiated thyroid cancer remain poorly defined," said Dr. Kenyon M. Meadows and his associates at the University of Florida, Gainesville (Am. J. Otolaryngol. 2006;27:24-8).

Dr. Meadows and his associates reviewed the records and assessed outcomes in all 42 patients who were treated for advanced or recurrent thyroid cancer with adjuvant high-dose EBRT at their university between 1962 and 2003; median patient age was 58 years.

Ten patients died from thyroid cancer during a mean follow-up of 7 years, while 16 died from unrelated causes. The rate of local or regional recurrence at 5 years was 0% for patients who had no gross residual disease when they underwent EBRT and 30% for those who did have gross residual disease at the time of EBRT.

Five-year cause-specific survival was 90% for patients who had no gross residual tumor when they underwent EBRT and 69% for those who did have gross residual disease at the time of EBRT. Five-year survival free of distant metastases was 82% for those who had no evidence of metastasis when they underwent EBRT.

These findings "confirm the efficacy of EBRT despite the negative patient selection bias inherent in these retrospective analyses," the investigators said.

The findings also are in line with the results of several other recent studies, which "have consistently shown a favorable impact on local-regional control." This contrasts with early reports suggesting that "EBRT was either ineffective or even associated with a worse outcome," the researchers noted.

Cardiac Effects of Hyperthyroidism

Subclinical hyperthyroidism was linked to atrial fibrillation but not to other clinical cardiovascular conditions or deaths in a new study.

The research, conducted by Dr. Anne R. Cappola from the University of Pennsylvania in Philadelphia and her colleagues, examined the link between unrecognized thyroid dysfunction and cardiovascular risk, including atrial fibrillation, coronary heart disease, cerebrovascular disease, and death (JAMA 2006;295:1033-41).

The subjects were a subgroup of 3,233 participants in the population-based, longitudinal Cardiovascular Health Study. They were community-dwelling older adults with a mean age of 73 years. At baseline, 82% were euthyroid, 15% had subclinical hypothyroidism, 1.6% had overt hypothyroidism, and 1.5% had subclinical hyperthyroidism. Individuals with overt hyperthyroidism or thyrotoxicosis were excluded.

The study found no differences in cardiovascular events at baseline between the euthyroid group and any of the three groups with thyroid dysfunction. But over the 12.5-year follow-up period, subjects with subclinical hyperthyroidism had a greater incidence of atrial fibrillation than did euthyroid subjects (67 vs. 31 events per 1,000 person years). After adjustment, this risk was nearly double (hazard ratio, 1.98).

The data support treatment of subclinical hyperthyroidism when it is detected. "If endogenous subclinical hyperthyroidism is detected, older individuals may benefit from treatment to prevent atrial fibrillation."

The authors disagree with an earlier expert panel report that cited insufficient evidence to treat patients with TSH levels of 0.1-0.45 mU/L and recommended treating only those with TSH levels below 0.1 mU/L (JAMA 2004;291:228-38).

Thyroidectomy Safe for Grave's

Total thyroidectomy can be performed more safely than many clinicians realize,

and offers more durable results for people with Grave's disease than do antithyroid drugs or radioiodine, according to Dr. Kaare J. Weber of Mount Sinai School of Medicine, New York, and his associates.

The researchers reviewed the records of all 48 patients who underwent total thyroidectomy for Grave's disease at their hospital between 1993 and 2005. All but 7 of the patients were women, and the mean age was 40 years.

After a mean of 40 months follow-up post thyroidectomy, there were no recurrences of hyperthyroidism. In contrast, relapse rates of 20%-75% are cited in the literature for medical therapy, Dr. Weber and his associates said (Am. J. Surg. 2006;191:400-5).

Of the 20 patients who had mild or severe ophthalmopathy before surgery, 11 showed marked improvement or resolution of eye disorders and the remaining 9 showed either improvement or stabilization. In contrast, radioiodine treatment has been associated with the onset or exacerbation of ophthalmopathy, they said.

Eight patients (17%) were found to have papillary cancer of the thyroid at surgery. "These patients would not have received appropriate treatment for their coexisting cancer if they were treated only with antithyroid drugs and/or radioiodine," the investigators noted.

No patients suffered permanent laryngeal nerve injury from the procedure. Complications included three cases of transient hypocalcemia and one case of temporary right vocal cord paralysis. Only one patient developed permanent hypoparathyroidism, and that case "followed a previous failed [thyroid] exploration at another institution," they said.

These results demonstrate that total thyroidectomy now can be performed safely, with little of the morbidity and mortality that occurred when the procedure was first developed years ago. In addition, thyroidectomy addresses potentially cancerous nodules, as medical and radioiodine therapies do not, they said.

—From staff reports