

# Gender Differences Seen in Foot, Ankle Melanoma

BY BETSY BATES

Los Angeles Bureau

SAN DIEGO — Melanoma of the foot and ankle occurred far more commonly in women than it did in men, but men were more likely to have thicker tumors that were associated with a worse prognosis, Dr. Hugh T. Greenway said at the annual meeting of the California Society of Dermatology and Dermatologic Surgery.

In a review of 63 cases seen over 20 years at the Scripps Clinic in La Jolla, Calif., patients were the first to draw attention to melanoma lesions in 44 cases. Physicians spotted them in seven cases, and both were credited in five, Dr. Greenway reported.

There was no association between trauma and melanoma in the series.

Possible factors contributing to the disease remain unclear, said Dr. Greenway, who heads the clinic's division of Mohs/dermatologic surgery.

Sunburns, the binding pressure of shoes, and perhaps exposure to unfiltered radiation from fitting devices at Buster

Brown shoe stores in the 1950s and 1960s may be contributing to melanoma of the lower extremities.

In all, foot and ankle melanoma constituted 4% of all melanoma cases diagnosed at Scripps over 2 decades, occurring in 47 women and 16 men. The mean age at diagnosis was 58 years.

Melanomas occurring on the foot and ankle are more often misdiagnosed than melanomas on any other anatomic site, Dr. Greenway said. In his series, 10 cases, or 16%, were originally misdiagnosed.

"We're used to seeing benign conditions of the foot," he said, noting that some melanoma lesions may be dismissed as verrucae, toenail onychomycosis, subungual hematomas, tinea pedis, or ischemic ulcers.

"For the most part, prognosis is not good," with 5-year survival ranging from 52% to 71% in previous series, noted Dr. Greenway.

The Scripps series showed a 4-year survival of 80%, with disease-free survival in 73% (46 patients). One reason for the high survival of Scripps patients could be that 24 of the 63 cases were melanoma in situ.

"The real key [to generally poor survival statistics] is that we don't pick these up as early as we do melanoma on other parts of the skin surface," he said.

People don't regularly examine their feet, and the process becomes even more difficult with age and infirmities. In addition, some clinicians don't even have pa-

tients remove their socks during skin examinations, said Dr. Greenway.

Women may be diagnosed with less-thick melanomas because they pay more attention to their feet than men do and they are also more likely to get pedicures, he speculated.

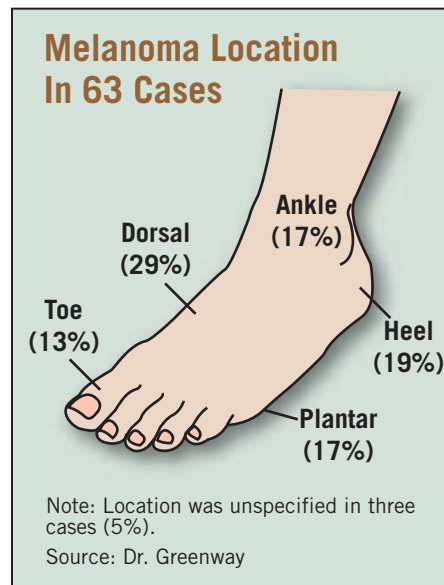
Presumably these cases are diagnosed earlier.

Many patients, however, have trouble remembering how long the lesions have been on their feet or ankles, perhaps accounting for the failure of Dr. Greenway's group to find an association between tumor thickness and duration.

In 10 cases, a biopsy underestimated the Breslow thickness of the tumor. Seven of these cases were upstaged during the treatment process, which consists of surgery, consideration of sentinel node examination, a metastatic and oncology evaluation, and follow-up.

Disease-free survival was significantly worse in the Scripps series for thicker tumors, a higher stage, males, and tumors initially misdiagnosed.

Increased surveillance did not improve survival in the series, he noted. ■



## Melanocytic Imposters May Masquerade as Melanoma in Situ on Sun-Damaged Skin

BY BETSY BATES

Los Angeles Bureau

SAN DIEGO — An accurate diagnosis of melanoma in situ is often lifesaving, but its histology can be difficult to distinguish from benign histologic findings, Dr. Philip E. LeBoit said at the annual meeting of the California Society of Dermatology and Dermatologic Surgery.

Numerous and prominent melanocytes on sun-damaged facial skin, particularly those that are near the eyelids, can easily be confused with those seen in melanoma in situ, as can enlarged melanocytes stimulated by a recent excision, said Dr. LeBoit, professor of clinical pathology and dermatology at the University of California, San Francisco.

Dr. Barbara Gilchrest and her associates first highlighted the presence of "actinic melanocytosis" when they reported many years ago that the basal layer of sun-damaged skin in patients of all ages contains twice the expected number of melanocytes (J. Invest. Dermatol. 1979;73:141-3). That finding was recently confirmed and elaborated upon in a recent study by Dr. Ali Hendi and associates.

"So it's not just an increase in the prominence or an increase in the size of melanocytes due to the macules around them in sun-damaged skin. There's actually an increase in number," Dr. LeBoit said.

If dyschromia or solar lentigos further confuse the picture on facial skin, where

there are more melanocytes than on other parts of the body, "nature is confounding you," he said.

Dr. LeBoit offered the following clues, which he said should heighten the suspicion that a lesion is a melanoma in situ, rather than an artifact of skin that has been damaged by the sun:

- ▶ The presence of irregular intervals between melanocytes.
- ▶ Nests, which may be present in melanoma in situ, but not in actinic melanocytosis. Levels may be required to show them.
- ▶ Pagetoid spread, which also may require levels to be visualized.

**'It's not just an increase in the prominence or an increase in the size of melanocytes due to the macules around them in sun-damaged skin. There's actually an increase in number.'**

- ▶ Prominent dendrites, which are sometimes, though not necessarily always, present in melanoma in situ. Dr. LeBoit cautioned, however, that dendrites may be seen more prominently in dark-skinned patients.

- ▶ More irregular pigmentation.
- ▶ More marked adnexal involvement, except in the case of lentigo melanoma. (In actinic melanocytosis, large melanocytes may extend more deeply or symmetrically in the follicular infundibula and acrosyringia.)

Immunohistochemical studies using HMB-45 or Ki-67(MIB-1) stains are of little use in distinguishing melanoma in

situ from actinic melanocytosis, he pointed out.

The results of recent studies from Italy also suggest that the use of immunoperoxidase stains in this context can lead to the "overdiagnosis" of melanoma in situ, said Dr. LeBoit, who founded and codirects the university's dermatopathology service.

A more reliable alternative is to simply biopsy the contralateral side of sun-exposed facial skin, he suggested.

"If you find the exact same picture, then that's just what the patient's face looks like," he said.

The second dilemma he posed—that is, distinguishing melanoma in situ from recently excised skin—also has a fairly simple solution, as it turns out.

Dr. LeBoit explained that all biopsies stimulate a release of cytokines during the wound-healing process, which in turn activates melanocytes, especially on facial skin.

"Even the best dermatopathologists in the world sometimes cannot tell melanocyte activation by the wound-healing process from the very edge of a melanoma in situ," he asserted.

His solution? Wait to reexcise.

"Once you've gotten a clinically evident melanoma in situ out, although the patient may be anxious, there is no medical reason to bring them in the next day to do a reexcision," Dr. LeBoit said.

"You can wait a month. At that point, you will have no enlargement of melanocytes to confuse the picture," he commented. ■

## Nail Squamous Cell Carcinoma Varies In Presentation

MANCHESTER, ENGLAND — Squamous cell carcinoma of the nail unit is often misdiagnosed and its painful course protracted because clinical features can resemble more mundane conditions such as paronychia, Dr. Mohamed Alrawi said at the annual meeting of the British Association of Dermatologists.

A retrospective study of 20 patients seen between 1997 and 2005 has identified three patterns of presentation in this rare condition, and wider recognition of these patterns could help expedite diagnosis, Dr. Alrawi said. The clinical patterns were:

- ▶ Type 1, in 10 (50%) patients, was a frank nodule or tumor with or without nail loss.
- ▶ Type 2, seen in six (30%), was a mild to moderate warty periungual lesion with nail splitting and skin fissures.
- ▶ Type 3, found in four (20%), was a recurrent discharge from beneath the nail with putative onychomycosis.

In all patients, less than 50% of the surface area of the distal phalanx was affected, said Dr. Alrawi of Bristol Dermatology Centre, Bristol (England) Royal Infirmary.

One patient had bone involvement. Histologic evaluation showed invasive disease in 15 patients, 5 with in situ squamous cell carcinoma. The thumb was the most commonly affected digit, involved in seven of the patients. The index finger was affected in four patients, the middle finger in three, and the ring and little fingers in one each.

A total of 14 patients reported pain as the primary symptom, and only 2 were asymptomatic, he said. In seven patients, the carcinoma was associated with human papillomavirus, with six involving type 16.

—Nancy Walsh