



A SUPPLEMENT TO

Family Practice News®



SKIN DISEASE
EDUCATION
FOUNDATION
an Elsevier business

Emerging Insights and New Therapeutic Opportunities: Acne and Atopic Dermatitis

**The Importance of Vehicle and Skin
Barrier Function in Acne Vulgaris**

**Evolving Therapy in
Atopic Dermatitis**

**Combination Therapy
Considerations in Acne Vulgaris**

**Nonsteroidal Treatment of
Atopic Dermatitis**



FACULTY

Emil A. Tanghetti, MD, Chair

Clinical Professor of Dermatology
University of California, Davis, School of Medicine
Medical Director
Center for Dermatology and Laser Surgery
Sacramento

Lawrence F. Eichenfield, MD

Professor of Pediatrics and Medicine (Dermatology)
University of California, San Diego, School of Medicine
Children's Hospital
San Diego

Leon Kircik, MD

Clinical Associate Professor
Department of Dermatology
Indiana University
Indianapolis
Medical Director
Physicians Skin Care, PLLC
Louisville, Ky.

James Turner, MD, PhD

Clinical Professor
Division of Dermatology
Department of Medicine
University of Tennessee
Memphis

**Produced in affiliation with the 30th Annual
Hawaii Dermatology Seminar™**

President, Elsevier/IMNG
Alan J. Imhoff

Vice President,
Medical Education
Sylvia H. Reitman, MBA

Program Manager,
Medical Education
Malika Wicks

Clinical Editors
Lori A. Saslow
Joanne M. Still

Graphic Design
CGI DEZINE, Inc.

Production Specialist
Rebecca Slebodnik

The articles in this supplement are based on presentations made during Skin Disease Education Foundation's 30th Annual Hawaii Dermatology Seminar, a continuing medical education program, held February 13, 2006, in Kauai, Hawaii. The symposium titled *Emerging Insights and New Therapeutic Opportunities for Acne and Atopic Dermatitis* was produced in part by Physician Resources, LLC.

This educational supplement to FAMILY PRACTICE NEWS was supported by



The supplement was produced by the medical education department of International Medical News Group. Neither the Editor of FAMILY PRACTICE NEWS, the Editorial Advisory Board, nor the reporting staff reviewed or contributed to its contents. The opinions expressed in this supplement are those of the faculty and do not necessarily reflect the views of the supporter or the Publisher.

Copyright © 2006 Elsevier, Inc. All rights reserved. No part of this publication may be reproduced or transmitted in any form, by any means, without prior written permission of the Publisher. Elsevier, Inc. will not assume responsibility for damages, loss, or claims of any kind arising from or related to the information contained in this publication, including any claims related to the products, drugs, or services mentioned herein.



**INTERNATIONAL
MEDICAL NEWS
GROUP**

Emerging Insights and New Therapeutic Opportunities: Acne and Atopic Dermatitis

Topic Highlights

Introduction 3

The Importance of Vehicle and Skin Barrier Function in Acne Vulgaris 3

Emil A. Tanghetti, MD, Chair

Clinical Professor of Dermatology, University of California, Davis, School of Medicine
Medical Director, Center for Dermatology and Laser Surgery, Sacramento

Combination Therapy Considerations 6 in Acne Vulgaris

Leon Kircik, MD

Clinical Associate Professor, Department of Dermatology, Indiana University, Indianapolis
Medical Director, Physicians Skin Care, PLLC, Louisville, Ky.

Evolving Therapy in Atopic Dermatitis 8

Lawrence F. Eichenfield, MD

Professor of Pediatrics and Medicine (Dermatology), University of California
San Diego, School of Medicine
Children's Hospital, San Diego

Nonsteroidal Treatment of Atopic Dermatitis 10

James Turner, MD, PhD

Clinical Professor, Division of Dermatology, Department of Medicine
University of Tennessee, Memphis

TARGET AUDIENCE

This activity is intended for healthcare professionals, including dermatologists and pediatricians, who are involved in the treatment of patients with acne vulgaris or atopic dermatitis.

FACULTY AND UNAPPROVED/OFF-LABEL USE DISCLOSURES

Faculty/authors must disclose any significant financial interest or relationship with proprietary entities that may have a direct relationship to the subject matter. They must also disclose any discussion of investigational or unlabeled uses of products.

Dr Eichenfield has received clinical grants from Astellas Pharma US, Inc., Connetics Corporation, Dermik Laboratories, Ferndale Laboratories, Inc., Galderma Laboratories, L.P., GlaxoSmithKline, Hill Dermaceuticals, Inc., and Novartis Pharmaceuticals Corporation. He is also a consultant to Connetics and Novartis. He has stated that he will reference the unlabeled/unapproved uses of the following drugs: Mimyx cream for atopic dermatitis, MAS063D (Atopiclair) for atopic dermatitis, and a probiotic, *Lactobacillus fermentum*, for atopic dermatitis.

Dr Kircik has received funding as an investigator, consultant, advisor, or speaker from Abbott Laboratories, Allergan Inc., Amgen, Inc., Astellas Pharma US, Inc., Berlex Inc., Biogen Idec Inc., Centocor, Inc., Connetics Corporation, Dermik Laboratories, Dowpharma, Ferndale Laboratories, Inc., Galderma Laboratories, L.P., Genentech, Inc., GlaxoSmithKline, HealthPoint Ltd., Medicis Pharmaceutical Corporation, Novartis Pharmaceuticals Corporation, Nucryst Pharmaceutical Corporation, QLT Inc., SkinMedica, Stiefel Laboratories, Inc., 3M Pharmaceuticals, Valeant Pharmaceuticals International, and Warner-Chilcott, PLC. He has stated that he will reference the unlabeled/unapproved uses of the following drugs: clindamycin 1%/benzoyl peroxide 5% gel (Duac Topical Gel) for acne.

Dr Tanghetti has received funding for clinical grants from and is a consultant to Allergan Inc., and Stiefel Laboratories, Inc.

Dr Turner is a consultant to Stiefel Laboratories, Inc. He has stated that he will reference the unlabeled/unapproved uses of the following drugs: Mimyx cream for atopic dermatitis and clindamycin 1%/benzoyl peroxide 5% gel.

Introduction

In this supplement, which is based on an educational symposium held at Skin Disease Education Foundation's 30th Hawaii Dermatology Seminar, the faculty discusses the clinical management of patients with acne vulgaris and atopic dermatitis (AD). Both conditions present a significant challenge to dermatologists due to their complex pathogenesis and range of clinical expression. Because of the widespread prevalence and chronicity of acne and AD, it is necessary to provide patients with treatments that are effective and well tolerated. Paramount to these goals is the effectiveness of the vehicle formulation in protecting skin barrier function. Attention to barrier function allows the beneficial effects of treatment regimens for acne and AD to be maximized.

A number of studies focusing on acne therapy demonstrate the importance of skin rehydration and maintaining the integrity of the skin barrier. In the studies presented, the two most effective gels used to treat acne contain the active ingredients clindamycin 1% and benzoyl peroxide (BPO) 5%. One gel provides the clindamycin/BPO combination in a drug-delivery vehicle containing the emollients glycerin 4% and dimethicone 1%. The second gel contains the active agents without emollients. The advantages of combination therapy and the importance of vehicle to enhance barrier function are discussed.

The complex etiology of AD is reviewed and the importance of skin barrier function is emphasized. Standard therapies for AD include emollients, corticosteroids (topical and systemic), antibiotics, antihistamines, and bathing regimens. Topical calcineurin inhibitors have been added as second-line agents in the treatment of AD. Newer additions to the AD treatment armamentarium are presented, including a nonsteroidal cream that provides stratum corneum repair, skin hydration, lipid modification, and alleviation of AD symptoms. A discussion of a new glycyrrhetic acid-based formulation with anti-inflammatory and antipruritic properties is included. Encouraging results with probiotics are also presented.

The treatment of barrier dysfunction as an evolving area of therapy for both acne vulgaris and AD is addressed in the following pages. The pathogenesis of these disorders and treatment regimens typically contribute to the disruption of the epidermal barrier. The faculty underscores the importance of hydration of the stratum corneum with moisturizing agents to re-establish the integrity of skin barrier function, which ultimately improves the tolerability of acne and AD therapy and optimizes treatment outcomes.

The Importance of Vehicle and Skin Barrier Function in Acne Vulgaris

Emil A. Tanghetti, MD, Chair

Restoring hydration to the stratum corneum is an important consideration when treating patients with acne vulgaris. Vehicle and skin barrier function are related to tolerability, patient compliance and, ultimately, to the efficacy of acne treatment. While therapy must be individualized, the role of vehicle and effective maintenance of the skin barrier should be considered. Promoting normal barrier function and using vehicles containing moisturizers will enhance therapeutic outcomes.

The integrity of the skin barrier in acne is critically important. Changes in barrier function can occur in a number of ways, and

may result from any condition that significantly alters the epidermis. Barrier function is disrupted by certain conditions such as atopic dermatitis, psoriasis, and acne. In addition, treatments with soaps, surfactants, and medications used for a variety of skin disorders disrupt barrier function, and environmental factors such as sunburn, low temperature, and low humidity change the way skin functions and may lead to excessive dryness. Topical retinoids—the mainstay of acne therapy—alter skin barrier function and may result in irritation.^{1,2}

Barrier disruption, characterized by dryness (xerosis) and peeling, occurs when the water content of the stratum

corneum decreases below 10%.³ Skin barrier dysfunction is demonstrated by increased transepidermal water loss from the stratum corneum and a decrease in lipids in the stratum corneum.⁴ The resulting dehydration affects the mechanism of drug absorption through the skin, and a damaged epidermis may lead to overabsorption of topical medication, causing additional barrier damage.

Tolerability of Topical Retinoids

Leyden⁵ examined the facial tolerability of various topical retinoids in a series of randomized, split-face studies involving

253 healthy patients. The retinoids used were tazarotene 0.05% cream, tazarotene 0.1% cream, tazarotene 0.1% gel, adapalene 0.1% gel, adapalene 0.1% cream, tretinoin 0.02% emollient cream, tretinoin 0.05% emollient cream, tretinoin 0.1% cream, and tretinoin 0.1% microsphere gel. Four variables were evaluated—retinoid concentration, vehicle, skin sensitivity, and individual retinoid compound—to determine the influence of each on tolerability. Each patient used one topical retinoid on one side of the face once daily for 29 days. Moisturizer use was not allowed. The patients were evaluated at baseline and at days 7, 14, 21, and 29. As expected, all retinoid formulations increased dryness scores for all patients. Patients with normal skin experienced significantly lower levels of irritation compared to those with “sensitive skin” (defined as a history of skin sensitivity).

The study indicated that while concentration and vehicle do affect facial tolerability, skin sensitivity with impaired stratum corneum function also plays an important role. In the summary, the author noted that retinoids alter barrier function, and the effects are greater in patients with sensitive skin compared to those with normal skin.

Role and Characteristics of Vehicle

For greatest efficacy in acne treatment, a vehicle should deliver medication in an active, stable form. Ideally, the vehicle should not irritate the skin, should be aesthetically pleasing to patients to enhance compliance, and should deliver medication to specifically designated sites. Finally, the ideal vehicle should promote repair and enhancement of skin barrier function (Table 1).

Table 1. Role of Vehicle in Topical Acne Medications

The ideal vehicle should:

- deliver medication in an active, stable form
- not irritate the skin
- be aesthetically pleasing
- deliver medication to the proper skin site(s)
- repair and enhance the barrier characteristics of the skin

In addition to efficacy and safety, several important factors are desirable in a topical medication. The ideal vehicle allows the patient to spread the medication evenly over the skin, depositing an even, thin film. In addition, to avoid contamination of the medication, a tube dispenser offers an advantage over a jar. Finally, it is an advantage if the medication can be dispensed from a container that delivers the proper amount of medication.

For greatest efficacy in acne treatment, a vehicle should deliver medication in an active, stable form.

Enhancing Barrier Function

Currently, key areas of focus for both clinicians and researchers are the composition of various acne treatments, their effect on skin function, and the potential for skin irritation. For example, benzoyl peroxide (BPO) and topical retinoids are inherently drying, and this drying effect is accentuated in patients with sensitive skin. Improved acne medication vehicles help reduce or minimize the drying effect of some of these medications.

Improvement of the barrier function of the skin involves rehydration of the stratum corneum. This can be accomplished via two pharmaceutical approaches. The first is to add an occlusive moisturizing agent to the vehicle to trap water and inhibit loss of moisture. The second approach is to use a humectant agent to attract moisture to the stratum corneum from the lower epidermal and dermal layers. Occlusive agents act as skin moisturizers by reducing the evaporation of water into the atmosphere. Typically, occlusives are oily substances such as hydrocarbon oils and waxes and vegetable and animal fats, which may be comedogenic in some patients. Silicone products such as dimethicone and cyclomethicone are commonly used in acne vehicles because they are “oil-free” agents that are hypoallergenic, noncomedogenic, and fragrance-free.³ As noted, humectants draw water to the stratum corneum from the deeper layers of the epidermis and dermis. Humectants include a number of

agents such as glycerin, sodium lactate, urea, and propylene glycol. The substances most widely used today, glycerin and urea, are well tolerated and effective. Table 2 lists the most commonly used occlusive moisturizers and humectants.

Vehicle Affects Tolerability

Using an occlusive agent alone will not draw moisture to the epidermis, and a humectant alone will increase transepidermal water loss. Therefore, the most effective vehicle for acne therapy should combine both a humectant and an occlusive agent.

An optimum vehicle also should not produce adverse sensory stimuli such as a burning sensation. Patients find products that “burn” very difficult to use and will often stop using such a product within a day or two.

Antibacterial activity is another consideration in topical acne treatment. Clindamycin is an excellent topical antimicrobial agent and is less drying than other topical agents, such as BPO. However, clindamycin recently has become less effective because of the emergence of bacterial

Table 2. Moisturizing Agents³

Occlusive Moisturizers

Retard evaporation of water to atmosphere:

- Hydrocarbon oils and waxes (petrolatum, mineral oil, squalene, paraffin)
- Vegetable and animal fats (cocoa butter, lanolin)
- Silicone (dimethicone, cyclomethicone)
- Others (fatty acids, fatty alcohol, polyhydric alcohols, wax esters, vegetable waxes, phospholipids, sterols)

Humectants

Draw water from deeper layers of epidermis and dermis to the stratum corneum:

- Glycerin
- Sodium lactate
- Urea
- Propylene glycol
- Others, including some vitamins and proteins

resistance; fortunately, the addition of BPO seems to prevent such bacterial resistance.⁶ Thus, the combination of these antibiotic agents in a single formulation would provide sufficient antibacterial coverage with a reduced risk for increasing infections, with the added benefit of being less drying than BPO alone.

Two studies compared the tolerability of two water-based combination gels containing clindamycin 1% and BPO 5%, one gel with the emollients 4% glycerin and 1% dimethicone and the other without emollients.

The first of these studies, by Fagundes and colleagues,⁷ was a randomized, evaluator-blinded, split-face trial. The patients were between 15 and 25 years of age, all with mild acne. A total of 61 patients completed the weeklong study. Local tolerance was graded by a blinded evaluator and by patients at baseline and at the end of 1 week.

The results of the study demonstrated that the emollient-based gel was better tolerated, with substantially less dryness ($P=0.059$) and significantly less peeling ($P=0.045$) and burning ($P=0.034$) among the patients using the emollient-based product. There was no significant difference in erythema between the two groups.

In the second tolerability study, the two combination gels, with and without emollients, were evaluated in 52 patients (mean age 21 years) with mild to moderate acne.⁸ Each patient used one gel for 2 weeks, followed by a 2-week washout period when all acne medications were discontinued. After the washout period, the patients used

the second gel for 2 weeks. The investigators determined the degree of peeling and observed dryness. Both factors, which are manifestations of barrier dysfunction, were judged as “worse” or as “the same or improved” compared to baseline. The patients also evaluated dryness before and during the use of each gel.

After 2 weeks, the patients reported that use of the gel with emollients was associated with significantly less dryness and peeling ($P<0.05$) and said they experienced significantly better local tolerability with the emollient-containing formulation ($P<0.05$).

Improving Tolerability of Retinoid Therapy

The benefit of moisturizer-containing vehicles was demonstrated in patients with mild to moderate acne during retinoid therapy. In a 12-week study,⁹ 121 patients received tazarotene with vehicle only ($n=61$) or a combination product containing tazarotene plus clindamycin, BPO, and an emollient (T+CBE). At week 12, there were differences in peeling and dryness that were seen between tazarotene alone and T+CBE combination which did not achieve statistical significance.⁹ However, at week 4, patients who received the T+CBE formulation experienced significantly less peeling ($P<0.05$) (Figure).

This last finding is particularly important because, during the first 4 to 6 weeks of retinoid therapy, skin barrier dysfunction—and associated patient discomfort—is highest due to retinization. After this period, barrier function improves and dryness and peeling often diminish significantly.

This study suggests that using a T+CBE combination medication improves tolerability during retinoid therapy. Poor tolerability often leads to cessation of use of effective topical therapy during the first 4 weeks of retinoid treatment, when symptoms of barrier dysfunction are most likely to be bothersome. Improving tolerability may lead to enhanced compliance during this crucial time.

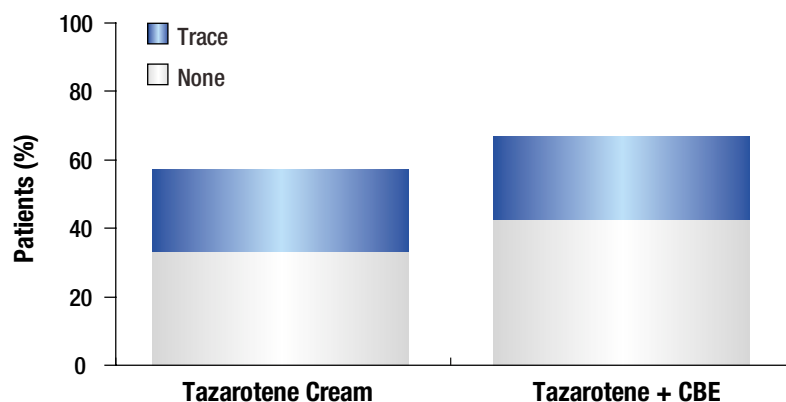
Summary

Attention to improved barrier function is essential for successful treatment and outcomes in patients with acne vulgaris and other dermatologic disorders. To enhance hydration, a vehicle that combines an occlusive agent and a humectant moisturizer is ideal. Combination therapy for acne, with the addition of moisturizers such as dimethicone and glycerin, enhances barrier function and will improve treatment outcomes. This is especially important during treatment with topical retinoids. Clinicians should consider the choice of active ingredients as well as vehicle, as both are equally important in the successful management of patients with acne vulgaris. ■

References

1. Jappe U. Pathological mechanisms of acne with special emphasis on *Propionibacterium acnes* and related therapy. *Acta Derm Venereol.* 2003;83:241-248.
2. Effendy I, Weltfreund S, Patil S, Maibach HI. Differential irritant skin responses to topical retinoic acid and sodium lauryl sulphate: Alone and in crossover design. *Br J Dermatol.* 1996;134:424-430.
3. Draelos ZD. Therapeutic moisturizers. *Dermatol Clin.* 2000;18:597-607.
4. Jorizzo J. Lamellar preparations as adjunctive therapy in the treatment of atopic dermatitis. Poster presented at: 63rd Annual Meeting of the American Academy of Dermatology; February 19, 2005; New Orleans, La. Poster P721.
5. Leyden J, Grove G, Zerweck C. Facial tolerability of topical retinoid therapy. *J Drugs Dermatol.* 2004;3: 641-651.
6. Warner GT, Plosker GL. Clindamycin/benzoyl peroxide gel: A review of its use in the management of acne. *Am J Clin Dermatol.* 2002;3:349-360.
7. Fagundes DS, Fraser JM, Klauda HC. Difference in the irritation potential and cosmetic acceptability of two combination topical acne gels: Combined results of two comparative studies. *Today's Ther Trends.* 2003;21:269-275.
8. Tanghetti E, Gold M, Fraser J. A two-center patient preference study comparing two acne gels. Poster presented at: 63rd Annual Meeting of the American Academy of Dermatology; February 18-22, 2005; New Orleans, La. Poster P108.
9. Tanghetti E, Abramovits W, Solomon B, Loven K, Shalita A. Tazarotene versus tazarotene plus clindamycin/benzoyl peroxide in the treatment of acne vulgaris: A multicenter, double-blind, randomized parallel-group trial. *J Drugs Dermatol.* 2006;5:256-261.

Figure. Tazarotene/Vehicle vs. Tazarotene + CBE Combination: Peeling at Week 4⁹



$P<0.05$ between groups for distribution of all grades of peeling
CBE=clindamycin/benzoyl peroxide/emollient combination

Combination Therapy Considerations in Acne Vulgaris

Leon Kircik, MD

Acne vulgaris is one of the most common skin disorders seen in clinical practice. The most successful strategy to treat acne requires careful patient evaluation and combination treatment.

Etiology and Pathogenesis

Acne vulgaris affects approximately 85% of Americans.¹ The cause of acne vulgaris is unknown, but various factors have been implicated in its pathogenesis. The primary change in acne lesions is an alteration in the pattern of keratinization within the follicle. Normally, keratinous material in the follicle is loosely organized. There are a large number of lamellar granules and relatively few keratohyaline granules. In comedones, the keratinous material becomes more dense, lamellar granules decrease, and keratohyaline granules increase.

In addition, individuals with acne have larger sebaceous glands and increased sebum production. Sebum is comedogenic, and sebum induces inflammation.² Also, patients with acne have decreased levels of linoleic acid.³ This decrease leads to localized essential fatty acid deficiency of the follicular epithelium, which may result in follicular hyperkeratosis and decreased epithelial barrier function.³

Other factors affecting sebaceous glands include insulin-like growth factors, growth hormone, androgens and estrogens, peroxisome proliferator-activated receptors, and melanocortins.

The inflammatory process associated with *Propionibacterium acnes* is an important underlying mechanism in acne. Several mechanisms have been identified that are associated with *P. acnes* (Table 1).⁴⁻⁹

Other factors that contribute to increased inflammation include interleukin (IL)-1, IL-1 receptor, and IL-1 receptor antagonist. Toll-like receptors (TLRs) also are involved in the inflammatory processes.⁹ It appears that in acne lesions, TLR-2 is expressed on the surface of

Table 1. Inflammation and *P. acnes*

Propionibacterium acnes induces inflammation in the following ways:

- Releases lipases, proteases, and hyaluronidases
- Secretes chemotactic factors⁵⁻⁷
- Activates both classical and alternative complement pathways^{8,9}
- Stimulates cytokine release by monocytes

P. acnes = *Propionibacterium acnes*

polymorphonuclear neutrophils (PMNs) surrounding the follicle. Proinflammatory cytokines (IL-1 β , IL-8, and tumor necrosis factor- α) released by PMNs upon activation with *P. acnes* may produce inflammation.

Rationale for Combination Therapy

Because many factors are related to the pathogenesis of acne, combination therapy appears to be the most effective therapeutic approach.¹⁰ Combination therapy targets multiple pathologic processes, establishes synergy among individual agents, and overcomes limitations associated with monotherapy. Increasing efficacy, improving

patient compliance, enhancing tolerability, and minimizing complications are the goals for combination therapy.

Synergy among available acne combination therapies results when there is significant overlap in the mechanistic activities of the agents. Table 2 summarizes the mechanism of action of both topical and oral agents. When used in combination, these therapies have overlapping mechanism of actions that enhance therapeutic efficacy.

Normalization of follicular epithelial shedding is the primary mechanism of action of topical retinoids and salicylic acid.¹¹ Benzoyl peroxide (BPO) and azelaic acid act primarily to reduce the number of *P. acnes* organisms, and both agents have comedolytic properties.¹¹ Topical antibiotics act to reduce *P. acnes*;^{11,12} so using a topical retinoid along with a topical antibiotic/BPO combination—each with a different mechanism of action—effectively addresses multifactorial pathogenesis of acne vulgaris.

BPO is available in over-the-counter and prescription formulations in strengths ranging from 2.5% to 10%. BPO monotherapy is most useful for treating mild acne.¹¹ Its mechanism appears to be related to bactericidal effects and comedolytic activity.^{11,13} Irritation, dry skin, and bleaching

Table 2. Acne Therapy: Mechanism of Actions

	Decreases Sebum Production	Normalizes Keratinization or is Keratinolytic	Decreases <i>P. acnes</i>	Decreases Inflammation
Topical therapy				
Antibiotics			*	*
Retinoids		*		*
BPO		*	*	*
Azelaic acid		*	*	
Oral therapy				
Antibiotics			*	*
Isotretinoin	*	*	*	*
Estrogens/antiandrogens	*			
Spironolactone	*			

BPO = benzoyl peroxide; *P. acnes* = *Propionibacterium acnes*.

of skin or fabrics may occur, and some patients find these side effects intolerable.¹³ Contact dermatitis has been reported but is relatively rare.¹¹

Topical retinoids such as tretinoin, adapalene, and tazarotene can all be used to treat comedonal and inflammatory lesions. They can be used as monotherapy or with topical antibiotics—that is, given alone or in combination (alternating) with topical antibiotics to enhance efficacy. All of these topical agents normalize keratinization; however, adapalene and tazarotene appear to have additional anti-inflammatory properties.¹¹ Adverse effects include skin irritation, particularly with higher-concentration formulations. Also, retinoids typically are associated with photosensitivity and acne flare during the early weeks of therapy.^{11,14}

Efficacy of Antibiotic/BPO Combinations

BPO therapy is effective for patients with acne, and, in some cases, BPO monotherapy is more effective in the reduction of *P. acnes* than is topical clindamycin or erythromycin alone. The highest reduction in *P. acnes* is achieved with the clindamycin/BPO combination; the combination offers slightly better reduction of *P. acnes* as compared to BPO alone, with the added benefit of inhibiting the development of erythromycin- and clindamycin-resistant *P. acnes* strains.¹⁵

Two pivotal studies examined the effects of clindamycin/BPO combination gel. The treatment arms used were clindamycin 1%/BPO 5% gel, clindamycin 1% gel, BPO 5% gel, and vehicle.¹⁶ The two studies were double-blind, randomized, vehicle-controlled trials in which patients were treated for 10 weeks with twice-daily application of the agent. A total of 767 subjects with moderate to moderately severe acne completed the studies.

The results of the studies demonstrated that the clindamycin/BPO combination was more effective than BPO, clindamycin, or vehicle alone. One of the studies showed that combination therapy outperformed other treatment arms for both noninflammatory and inflammatory lesions.¹⁶

In two subsequent trials, Lookingbill and colleagues¹⁷ also evaluated the clindamycin/BPO combination versus the use of single agents and vehicle. The study was an 11-week, double-blind, randomized, parallel, vehicle-controlled trial with once-nightly application of the study drug. The four treatment arms were clindamycin

1%/BPO 5% gel with moisturizers, (Duac) clindamycin 1% gel, vehicle, and BPO 5% gel. Three hundred thirty-four subjects with acne between 13 and 30 years of age completed the studies. The investigators found that all three active treatments outperformed vehicle with differences that were statistically significant ($P \leq 0.004$). In addition, both the combination therapy and BPO alone were significantly superior to clindamycin alone ($P \leq 0.01$).

The data from Lookingbill and colleagues¹⁷ also showed that combination therapy was superior in reducing noninflammatory lesions. A mean reduction of 36% in noninflammatory lesions was shown in patients ($n=95$) who used the clindamycin/BPO combination in a moisturizing vehicle. In the BPO monotherapy group ($n=92$), the reduction in noninflammatory lesions was 30% ($P < 0.02$). The group using only clindamycin ($n=89$) had a mean reduction of 9% in noninflammatory lesions ($P < 0.02$).

A total of five pivotal trials studied the efficacy of clindamycin 1%/BPO 5% in a moisturizer vehicle. The clindamycin/BPO combination was compared to clindamycin 1%, BPO 5%, and vehicle alone. The pooled results demonstrated a significant decrease in the inflammatory lesion count with the clindamycin/BPO combination in a moisture vehicle. In three of the five studies (studies 1, 2, and 5), the reduction of inflammatory lesions was statistically significant ($P < 0.05$) as compared to the monotherapy treatment arms.¹⁸

Tolerability of Clindamycin/BPO With Retinoids

Tanghetti and colleagues¹⁹ presented data on the use of retinoids with clindamycin/BPO in a moisturizing vehicle. The study, comparing clindamycin 1%/BPO 5% plus tazarotene 0.1% gel versus tazarotene 0.1% gel alone, was double-blind, randomized, and parallel in design. Patients ($n=121$) with moderate to severe acne were treated for 12 weeks with a once-daily application of medication.

The results indicated that the combination of tazarotene and clindamycin/BPO in a moisturizer vehicle achieved superior reduction ($P \leq 0.01$) in open and closed comedones compared with tazarotene alone from week 4 through week 12 of the study. In addition, a subanalysis of patients with the most severe acne revealed a greater reduction in papule and pustule count in patients receiving combination therapy ($P=0.055$).¹⁹

One of the most important findings was that patients were better able to tolerate retinoid therapy when using an agent with a vehicle containing moisturizer. The group receiving combination therapy at week 4 experienced less peeling ($P < 0.05$) than did the group treated with tazarotene alone.¹⁹ It appears that the moisturizer vehicle enhances efficacy of combination therapy, and tolerability of therapy increases. The clindamycin 1%/BPO 5% gel studied was formulated with an occlusive moisturizer (dimethicone) and a humectant moisturizer (glycerin). (See Dr Tanghetti's article on page 4 for additional discussion of occlusive and humectant agents.) Ease of use is enhanced by the gel's packaging, which makes it easy for patients to dispense the appropriate amount of medication.

Summary

Acne management with combination therapy has become the standard of care for many patients. It represents an important strategic approach to acne treatment by targeting more than one main underlying pathologic process. Current data support the enhanced efficacy of combination therapy. In addition to high efficacy, combination therapy minimizes development of bacterial resistance. The ideal approach for many patients is combination therapy using an effective vehicle to enhance compliance and tolerability. ■

References

1. American Academy of Dermatology. The Stubborn Truth About Acne. Available at: <http://www.aad.org/public/News/NewsReleases/stubborn.htm>. Accessed January 26, 2006.
2. Harris HH, Downing DT, Stewart ME, Strauss JS. Sustainable rates of sebum secretion in acne patients and matched normal control subjects. *J Am Acad Dermatol*. 1983;8:200-203.
3. Downing DT, Stewart ME, Wertz PW, Strauss JS. Essential fatty acids and acne. *J Am Acad Dermatol*. 1986;14:221-225.
4. Puhvel SM, Sakamoto M. The chemoattractant properties of comedonal components. *J Invest Dermatol*. 1978;71:324-329.
5. Webster GF, Leyden JJ. Characterization of serum-independent polymorphonuclear leukocyte chemotactic factors produced by *Propionibacterium acnes*. *Inflammation*. 1980;4:261-269.
6. Puhvel SM, Sakamoto M. Cytotoxin production by comedonal bacteria (*Propionibacterium acnes*, *Propionibacterium granulosum* and *Staphylococcus epidermidis*). *J Invest Dermatol*. 1980;74:36-39.
7. Webster GF, Leyden JJ, Norman ME, Nilsson UR. Complement activation in acne vulgaris: In vitro studies with *Propionibacterium acnes* and *Propionibacterium granulosum*. *Infect Immun*. 1978;22:523-529.
8. Webster GF, Leyden JJ, Nilsson UR. Complement activation in acne vulgaris: Consumption of complement by comedones. *Infect Immun*. 1979;26:183-186.
9. Kim J, Ochoa MT, Krutzik SR, et al. Activation of toll-like receptor 2 in acne triggers inflammatory cytokine responses. *J Immunol*. 2002;169:1535-1541.
10. Thiboutot D. New treatments and therapeutic strategies for acne. *Arch Fam Med*. 2000;9:179-187.

Continued on page 12

Evolving Therapy in Atopic Dermatitis

Lawrence F. Eichenfield, MD

Atopic dermatitis (AD) is a chronic, inflammatory, pruritic skin disease with multiple clinical presentations. AD often is associated with increased serum immunoglobulin E (IgE) synthesis and a personal or family history of atopic disease. AD may be related to other atopic diseases such as asthma, allergic rhinitis, and urticaria. The incidence of the disease is rising; in 2004, Krafchik¹ reported that the prevalence was 10% to 12% in children and 0.9% in adults.

AD has a complex etiology that includes immunologic responses, susceptibility genes, environmental triggers, and compromised skin barrier function. Traditional therapy includes general skin care measures, emollients, and antiinflammatory therapy. Recent additions to the AD armamentarium target xerosis and the compromised epidermal barrier of AD. A recently cleared non-steroidal cream appears to have antiinflammatory properties and to provide stratum corneum repair, skin hydration, lipid modification, and alleviation of AD symptoms. In addition, a glycyrrhetic acid-based formulation with antipruritic and antiinflammatory properties is now available, as are probiotic supplements, which have demonstrated promise in infants with moderate to severe AD.

Causes of Atopic Dermatitis: Immunology and Bacterial Triggers

Although the cause of AD is still unknown, a great deal of progress has been made in understanding the disease. Genetic and environmental factors influence the skin “hyperreactivity” of AD, and it is more likely to develop in children if one or both parents have ever had the disorder, asthma, or hay fever.² Increased IgE levels and peripheral eosinophilia are seen in some patients with AD; other disorders characterized by these changes include asthma, food allergy, and allergic rhinitis.^{3,4} Individuals may have different immunologic triggers, which may include xerosis, irritants and contactants, various foods, airborne allergens, stress, climate, and microorganisms.⁵

AD is associated with dysfunction of the immune system. A set of inflammatory cells—specifically, Langerhans’ cells and inflammatory dendritic epidermal cells—have been found in skin lesions of patients with AD and contribute to an augmented inflammatory response to a variety of stimuli.⁶ Patients with AD exhibit excessive T-cell activation in response to antigens. Allam and colleagues⁶ note that soluble factors appear to dominate the cellular infiltrate of lesions in AD patients, with interleukin-16, RANTES (regulated on activation, normal T-cell expressed and secreted chemokine), MCP4 (macrophage/monocyte chemoattractant protein-4), and eotaxin shown in lesional skin.

Individuals may have different immunologic triggers, which may include xerosis, irritants and contactants, various foods, airborne allergens, stress, climate, and microorganisms.

The immunodysregulation that occurs with AD promotes inflammation, and it appears to be a systemic problem. Increased IgE levels are seen in the majority of patients with AD, while others have normal serum IgE levels.⁶ The pathogenesis of AD also includes dysregulation of phosphodiesterase (PDE) and cyclic nucleotide dysregulation. Elevated PDE appears to be an early change in the disease and may partially explain increased inflammatory reactivity.⁷

Bacterial colonization and infection, typically caused by *Staphylococcus aureus* and *Streptococcus pyogenes*, is common in patients with AD. *S. aureus* is present on the skin of most patients with AD,¹ and a staphylococcal infection can be a trigger for AD flares, as well as serve as a superantigen stimulant. In patients with evidence of secondary bacterial infection (such as erythema, honey-colored crusting, or pustules), topical or oral antibiotics may be helpful.⁷

An increasing problem that may have an impact on AD care is an infection resistant to antibiotic therapy, particularly community-acquired methicillin-resistant *S. aureus* (MRSA). The prevalence of MRSA varies regionally in the United States, and dictates optimum therapy for bacterial infections in patients with AD. For example, in Houston, Texas, where the prevalence of MRSA is high, bleach baths are a standard treatment for patients with AD. In most parts of the country, antibiotic therapy with a cephalosporin, dicloxacillin, or amoxicillin/clavulanate is recommended as first-line therapy for non-life-threatening, secondary skin infections. If an infection does not respond to treatment or if the patient presents with cellulitis, abscesses, or has a history of MRSA, then it is prudent to change the therapeutic approach. Bacterial cultures and sensitivity testing are suggested and, based on the results, treatment with clindamycin, trimethoprim/sulfamethoxazole, or another antibiotic to which the bacteria are sensitive is recommended. The oral, bacteriostatic agent linezolid is an alternative. If the infection is severe or life-threatening, intravenous vancomycin may be used.

The influence of allergy triggers on patients with AD is controversial. Allergic reactions to food, dust mites, and other factors are more common in AD patients compared to individuals without AD. Sensitivity to allergens is considered a trigger of eczematous dermatitis in a subset of children with the disease.⁷ Manifestations of allergy also include contact urticaria, generalized urticaria, nasal congestion, wheezing, and gastrointestinal effects.⁸ When clinical allergy is suspected, a radioallergosorbent test or referral to an allergist is recommended.

Skin Barrier Dysfunction

Patients with AD have abnormalities in skin barrier function. These abnormalities include increased transepidermal water loss, decreased stratum corneum moisture content, and other associated characteristics (Table).⁷

Research has identified some key mechanisms of epidermal barrier function and dysfunction in AD. One factor in the development of AD in some patients appears to be related to stratum corneum chymotryptic enzyme (SCCE).⁹ SCCE serves as a protease that can damage epidermal cell-cell adhesion. Inhibitors occur naturally in the skin to block proteases from destroying barrier function. In a subset of patients, barrier dysfunction appears to be mediated by variations in the SCCE gene, causing increased SCCE activity that “over-powers” the protease inhibitors. Researchers continue to explore how barrier dysfunction and breaks in the skin allow an entryway for antigens that may trigger the inflammatory response.

Historically, there are variations in expert recommendations for bathing in patients with AD. Some recommend the avoidance of baths and frequent application of emollients to moisturize the skin. Other experts emphasize the usefulness of bathing for hydrating skin in AD, suggesting bathing once to several times a day for several minutes in warm water followed by topical medication and moisturizer application. Some recent studies have compared methods of bathing and skin care, and the results of these investigations should be published soon.

Clearly, a trend in AD therapy is to target xerosis and compromised epidermal barrier function. Researchers are exploring selected emollients and vehicles that will enhance barrier function. The trend in this field is toward the use of new formulations and prescription products that are going through the US Food and Drug Administration approval process as “devices.”

Table. Barrier Function Abnormalities Associated With Atopic Dermatitis⁷

- Increased transepidermal water loss
- Decreased stratum corneum moisture content
- Increased permeability to hydrophilic substances
- Decreased lipids/ceramides
- Decreased barrier to infectious agents
- Decreased endogenous humectants
- Likely increased epicutaneous antigen absorption

Efficacy of Nonsteroidal Prescription Creams

N-Palmitoylethanolamine (PEA) nonsteroidal cream, (MimyX) appears to be a useful agent in the treatment of AD. It contains natural lipids, including olea europaea, palm glycerides, hydrogenated lecithin, and squalene. The active agent, PEA, is a naturally occurring essential fatty acid with antiinflammatory properties. PEA does not contain emulsifiers that may disrupt the epidermis. Further, it appears to improve stratum corneum repair and promote skin hydration, and it may modify lipids in the skin.

A large study of more than 2,400 patients with AD demonstrated the efficacy and tolerability of PEA nonsteroidal cream.¹⁰ This was an international, open-label, prospective, observational, cohort study of patients with mild to moderate AD. Over 38 days, the use of PEA cream resulted in decreased itching, dryness, erythema, lichenification, and excoriation. According to the investigators, 62% of patients who used PEA cream were able to decrease their use of concurrent topical corticosteroids, 34% discontinued using topical corticosteroids, 20% decreased their use of concurrent topical immunomodulators, and 39% discontinued using antihistamines. Sixty percent of patients reported sleep improvement, and tolerability of PEA cream was high.¹⁰

Hydrolipidic cream, another nonsteroidal agent, also may be useful in treating AD. The active agent, glycyrrhetic acid, appears to have anti-inflammatory and anti-itch properties. Glycyrrhetic acid has been shown to inhibit 11 β -hydroxysteroid dehydrogenase, an enzyme responsible for glucocorticosteroid metabolism. Inhibiting this enzyme prevents inactivation of natural hydrocortisone. In addition, glycyrrhetic acid indirectly potentiates the effect of topical corticosteroids on an individual's endogenous corticosteroids.¹¹ Hydrolipidic cream also contains sodium hyaluronate, which hydrates the skin. However, clinicians and patients are advised that this agent contains shea butter, which is extracted from shea nuts, so individuals who are allergic to nut oil may react to this compound.

In a 5-week study of 30 adult patients with mild to moderate AD, hydrolipidic cream was compared to vehicle (an emollient base minus active ingredients).¹²

Compared to vehicle alone, the hydrolipidic cream significantly improved the outcome variables including total body affected area, Eczema Area and Severity Index (EASI) score, and itch score.¹² In a recently completed double-blind, randomized study of 218 patients, hydrolipidic cream significantly improved the EASI score and itch score and the need for rescue medication was decreased.¹³

Probiotics also have been studied and have been stated to be beneficial in patients with AD. A recent study from Perth, Western Australia, investigated the effects of probiotics on moderate or severe AD in 53 young children between 6 and 18 months of age.¹⁴ The patients were given a probiotic (*Lactobacillus fermentum*) or placebo, twice daily for 8 weeks. The final evaluation was done at week 16. The results were measured by the Severity Scoring of Atopic Dermatitis (SCORAD) index. Reduction in the SCORAD index was significant in the probiotic group compared to the placebo group ($P=0.03$).¹⁴ At week 16, more children receiving probiotics ($n=24$, 92%) had a SCORAD index that was better than baseline as compared to children in the placebo group ($n=17$, 63%) ($P=0.01$). At the end of the study, more children in the probiotic group had mild AD ($n=14$, 54%) than in the placebo group ($n=8$, 30%). However, the placebo response is very high (10.2) in this study. It seems that while the decrease in the SCORAD in the probiotic group was significant as compared to baseline, unlike the placebo group, there was no statistical difference in improvement between the two groups. Further studies will be useful to assess the utility of this intervention.

Summary

There is an evolving understanding of AD and increasing knowledge of how atopy may be triggered in a subset of patients. Treatment of AD includes education, hydration of the skin, and antiinflammatory therapies. Nonsteroidal creams are new agents that may be effective treatment alternatives and are well tolerated by patients. Probiotic supplements may show promise in infants with AD. Barrier function is critically important in treatment decisions regarding AD, since stratum corneum repair, skin hydration, and lipid modification help alleviate symptoms. Treatment of barrier dysfunction continues to be an evolving area of therapeutic interest. ■

Continued on page 12

Nonsteroidal Treatment of Atopic Dermatitis

James Turner, MD, PhD

Atopic dermatitis (AD) is a chronic, cyclic, relapsing skin disorder prevalent in infants and young adults.^{1,2} It is the most common skin disease in childhood. Although patients often improve as they get older, AD is a disease that persists in 0.9% of adults.^{3,4} The prevalence of AD has increased two- to threefold over the past decade.⁵ Currently, more than 15 million people in the United States have AD symptoms.⁶

Individuals with AD experience disruption of skin barrier function that leads to increased antigen absorption. This contributes to increased transepidermal water loss (TEWL) and worsening of AD symptoms.^{5,7,8} Standard therapies, including emollients, corticosteroids, and topical calcineurin inhibitors (TCIs), are important in the management of this disease. New, nonsteroidal agents are a significant and effective addition to the treatment regimens used to repair and maintain skin barrier function.

Symptoms and Impact of Atopic Dermatitis

The inflammation of AD typically involves flexural and extensor areas of the skin. The areas most commonly affected are the face, inside the elbows, behind the knees, and on the hands and feet. The cycle of AD causes the skin to become especially itchy, leading to scratching, which then causes redness, swelling, cracking, crusting, and scaling.⁶ Flares as well as remissions are common.

Because AD is a visible disease, patients are at risk for psychological difficulties and low self-esteem.⁹ Similar to psoriasis and other severe eczematous processes, AD can have extreme effects on a patient's social interactions, success at work, sexual relationships, and overall quality of life.¹⁰ Family members and other caregivers experience significant burdens from the disease as well, including lack of sufficient, uninterrupted sleep and adverse effects on family dynamics and functioning.¹⁰

AD often is the first step in what has become known as the “atopic march” toward other allergic conditions, such as asthma and allergic rhinitis, which occur in the majority of patients with AD.⁵ These comorbidities further increase the psychosocial and economic burdens on patients and families.

Immune Response of Atopic Dermatitis

AD is characterized by cutaneous hyper-reactivity to environmental triggers,^{1,5} and most patients with the disease have an exaggerated immunoglobulin E (IgE) response, particularly during onset or flare of AD.¹¹ The persistent response can continue beyond the initial trigger, which may involve IgE hyperproduction and subsequent mast cell degranulation. Multiple receptor interactions influence the immune response to AD triggers.^{5,11,12} After cross-linking with an allergen, IgE binds Langerhans' cells, basophils, and mast cells, which then release various cytokines, including histamine.¹¹ Fatty acids in the skin, such as *N*-palmitoylethanolamine (PEA), bind to mast cells to regulate their activity,¹² and cytokines bind to vascular receptors to influence inflammation.⁵ Replenishing PEA in atopic skin may lead to decreased

inflammation.⁷ The results of preclinical studies regarding specific pharmacologic actions of PEA support hypotheses about its antiinflammatory effects (Figure).⁷

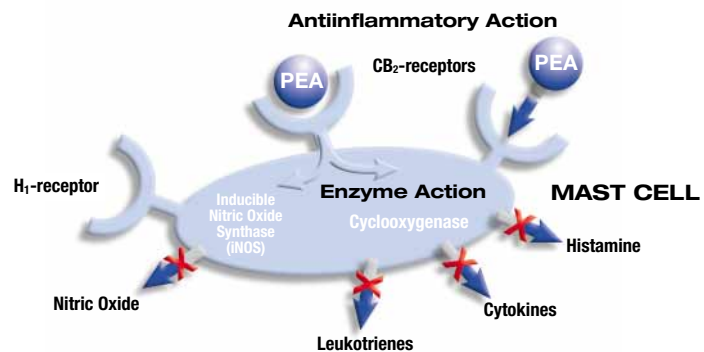
Disruption of Skin Barrier Function

An absence or deficiency of normally occurring skin lipids disrupts and reduces the physical function of the skin barrier.^{5,7,13,14} This allows entry of various irritants, allergens, and pathogens that aggravate and exacerbate the disease process.^{5,7} This increases patients' vulnerability to environmental triggers. In addition, skin barrier dysfunction increases TEWL in affected and clinically normal skin.⁸ It causes chronic exacerbation of the most common symptoms of AD (dryness, itching, and burning).

Current Management Recommendations

The goal of AD treatment is to target underlying skin abnormalities such as xerosis, pruritus, superinfection, and inflammation, and to prevent flares. Available treatments include emollients, topical and systemic corticosteroids, antibiotics, antihistamines, and, less often, ultraviolet light therapy. More recently, TCIs—tacrolimus and pimecrolimus—have been added to the AD armamentarium.

Figure. How *N*-Palmitoylethanolamine (PEA) Works



PEA binds to cannabinoid CB₂ receptors to downregulate mast-cell activation.¹³ Berdyshev and colleagues¹⁴ demonstrated that PEA inhibits the synthesis of interleukin-4 (IL-4), IL-6, and IL-8. This finding is of interest because atopic dermatitis (AD) skin lesions are often associated with abnormally high levels of IL-4.¹⁵

The most important step in treating AD effectively is rehydration of the stratum corneum. Eichenfield and colleagues¹ reported that regular bathing provides beneficial hydration of the skin and debridement of crust when complemented with a moisturizing cleanser, followed immediately by the application of a topical medication and/or emollient to seal in water absorbed by the skin during bathing. In addition, lubrication increases the rate of healing and establishes a barrier against further drying and irritation (Table).^{1,6}

Topical Corticosteroids

Topical corticosteroids have long been considered first-line therapy for AD. Once the disease is controlled, topical corticosteroids should be used intermittently, typically twice a week, to control flares.¹ Combination therapy with nonsteroidal topical immunomodulatory agents—that is, TCIs—is common. The goal is to taper the use of topical corticosteroids so that patients use nonsteroidal agents alone.

The potential for side effects, complicated by patients' fears of corticosteroid use, necessitates safer topical treatment options.¹⁵ In a questionnaire-based study of 200 dermatology outpatients with atopic eczema ranging in age from 4 months to 68 years, 73% of respondents were concerned about using topical corticosteroids on their own or their child's skin, and 24% admitted to having been noncompliant with treatment because of safety concerns.¹⁶ These results underscore the need for safer therapeutic alternatives to improve compliance, limit steroid use, and extend periods of remission.^{5,15}

Topical Calcineurin Inhibitors

Tacrolimus and pimecrolimus are nonsteroidal topical immunomodulatory agents that suppress T-lymphocyte activity

and inhibit calcineurin in the skin.¹⁷ These TCIs are recommended for second-line, short-term, intermittent treatment of AD in cases in which corticosteroids would be needed to control the disease.¹⁸ Tacrolimus 0.03% ointment is indicated for moderate to severe AD and pimecrolimus 1% cream is indicated for mild to moderate AD in patients over 2 years of age. TCIs are particularly effective in treating facial and intertriginous areas of the body where there is a greater risk of topical corticosteroid-induced atrophy.^{19,20} The most commonly reported side effects of these agents are burning, stinging, and itching in the initial stages of treatment.^{3,19-22} A topical corticosteroid may be added to therapy to minimize discomfort.

The goal of [atopic dermatitis] (AD) treatment is to target underlying skin abnormalities such as xerosis, pruritus, superinfection, and inflammation, and to prevent flares.

In March 2005, a black-box warning was issued by the US Food and Drug Administration for tacrolimus and pimecrolimus resulting from animal studies showing an increased risk of skin cancer. Although it will take years to accurately assess cancer risk in humans, physicians should counsel patients regarding sun avoidance and appropriate use of sunscreens.^{1,18}

Phototherapy, Antihistamines, and Antibiotics

Eichenfield and colleagues¹ found that phototherapy is effective in adult AD patients, but efficacy and safety data in the pediatric population are limited. Data regarding the efficacy of oral antihistamines are inconclusive. Antihistamines may provide relief of pruritus through unknown mechanisms and, thus, may help patients sleep. Topical or oral antibiotics are effective in treating secondary bacterial infections, but long-term use of antibiotics is not recommended.

Nonsteroidal Cream Device

PEA nonsteroidal cream (PEA cream) represents a new class of corticosteroid-free, TCI-free topical therapy for AD patients. There are no restrictions on patient age or duration of treatment with the use of PEA cream. This nonsteroidal cream has been shown to relieve the major symptoms of

AD, including xerosis, pruritus (and associated excoriation), scaling, erythema, and lichenification.²³ It repairs the skin barrier dysfunction common to AD patients, thereby helping to prevent exposure to environmental triggers.^{3,23} PEA cream mimics the lamellar structure of the skin barrier and replenishes the skin with natural lipids, including PEA.²⁴ The addition of PEA cream to a corticosteroid treatment regimen reduces the risk of relapse in patients with chronic AD.²⁵

In a large-scale study,²³ PEA cream was shown to be effective in managing AD symptoms in 923 pediatric patients between 2 and 12 years of age. The study demonstrated significant corticosteroid-sparing effects. Many patients discontinued topical corticosteroids or were able to use less potent corticosteroid agents and formulations. PEA cream was well tolerated by patients and was shown to be safe and effective.

In a recent study,²⁵ the efficacy of PEA cream plus emollient was compared to that of emollient alone (as the control) in reducing the risk for relapse in patients with chronic AD. In this multicenter, investigator-blinded, vehicle-controlled trial, efficacy and start of flare was determined by assessment of erythema, pruritus, and papulation/induration/edema. The patients in group 1 applied the nonsteroidal cream/emollient combination on one side of the body and emollient alone on the opposite side. In group 2, application of agents on each side of the body was reversed. The study included 74 chronic AD patients, 7 to 61 years of age. Topical steroids were administered only in the event of flare.

The results showed that addition of the nonsteroidal cream/emollient resulted in an extended median time until flare. The median time to flare was 43 days for skin treated with PEA nonsteroidal cream/emollient and 29 days for skin treated with emollient only. Differences in duration of flare were not significant. There was a 25% greater incidence of flare with emollient only versus skin treated with nonsteroidal cream ($P < 0.051$). No serious adverse events were reported.²⁵

Summary

AD is a chronic, relapsing disease that has extreme effects on the quality of life of patients and their families. Patients with AD typically have skin barrier dysfunction that leads to worsening of AD symptoms. Standard therapies include emollients, corticosteroids, and TCIs.

Continued on page 12

Table. Recommendations for Bathing and Emollients^{1,6}

Regular bathing can cleanse and hydrate the skin and debride crust, but in order to be effective, the patient must follow a strict bathing regimen:

- Bathe once daily for several minutes in warm water
- Use a moisturizing cleanser
- Avoid antibacterial cleansers
- Pat or air dry and immediately apply topical medication and/or an occlusive emollient

Combination Therapy Considerations in Acne Vulgaris *Continued from page 7*

- Bershad SV. The modern age of acne therapy: A review of current treatment options. *Mt Sinai J Med.* 2001;68:279-286.
- Leyden JJ. Therapy for acne vulgaris. *N Engl J Med.* 1997;336:1156-1162.
- Oh CW, Myung KB. An ultrastructural study of the retention hyperkeratosis of experimentally induced comedones in rabbits: The effects of three comedolytics. *J Dermatol.* 1996;23:169-180.
- Layton AM. Optimal management of acne to prevent scarring and psychological sequelae. *Am J Clin Dermatol.* 2001;2:135-141.
- Leyden JJ. The evolving role of *Propionibacterium acnes* in acne. *Semin Cutan Med Surg.* 2001;20:139-143.
- Warner GT, Plosker GL. Clindamycin/benzoyl peroxide gel: A review of its use in the management of acne. *Am J Clin Dermatol.* 2002;3:349-360.
- Lookingbill DP, Chalker DK, Lindholm JS, et al. Treatment of acne with a combination clindamycin/benzoyl peroxide gel compared with clindamycin gel, benzoyl peroxide gel and vehicle gel: Combined results of two double-blind investigations. *J Am Acad Dermatol.* 1997;37:590-595.
- Physicians' Desk Reference. Montvale, NJ: Medical Economics Co; 2006; 3214.
- Tanghetti E, Abramovits W, Solomon B, Loven K, Shalita A. Tazarotene versus tazarotene plus clindamycin/benzoyl peroxide in the treatment of acne vulgaris: A multicenter, double-blind, randomized parallel-group trial. *J Drugs Dermatol.* 2006;5:256-261.

Evolving Therapy in Atopic Dermatitis *Continued from page 9*

References

- Krafchik BR. Atopic dermatitis. *eMedicine.* 2004. Available at: <http://www.emedicine.com/derm/topic38.htm>. Accessed February 27, 2006.
- National Institute of Arthritis and Musculoskeletal and Skin Diseases. *Handout on Health: Atopic Dermatitis.* 2003. Available at: <http://www.niams.nih.gov/hi/topics/dermatitis>. Accessed February 27, 2006.
- Boguniewicz M, Leung DY. Atopic dermatitis. *J Allergy Clin Immunol.* 2006;117(2 Suppl):S475-S480.
- Leung DY, Boguniewicz M, Howell MD, Nomura I, Hamid QA. New insights into atopic dermatitis. *J Clin Invest.* 2004;113:651-657.
- Abramovits W. Atopic dermatitis. *J Am Acad Dermatol.* 2005;53(1 Suppl):S86-S93.
- Allam JP, Bieber T, Novak N. Recent highlights in the pathophysiology of atopic eczema. *Int Arch Allergy Immunol.* 2005;136:191-197.
- Eichenfield LF, Hanifin JM, Luger TA, Stevens SR, Pride HB. Consensus conference on pediatric atopic dermatitis. *J Am Acad Dermatol.* 2003;49:1088-1095.
- Leung DY, Boguniewicz M. Triggers of Atopic Dermatitis. In: Eichenfield LF, Leung DY, eds. *The Eczemas.* New York: Summit Communications; 2004: pp 55-67.
- Vasilopoulos Y, Cork MJ, Murphy R, et al. Genetic association between an AACC insertion in the 3'UTR of the stratum corneum chymotryptic enzyme gene and atopic dermatitis. *J Invest Dermatol.* 2004;123:62-66.
- Data on file, Stiefel Laboratories, Inc., Coral Gables, Fla.
- Teelucksingh S, Mackie AD, Burt D, McIntyre MA, Brett L, Edwards CR. Potentiation of hydrocortisone activity in skin by glycyrrhetic acid. *Lancet.* 1990;335:1060-1063.
- Belloni G, Pinelli S, Veraldi S. A randomised, double-blind, vehicle-controlled study to evaluate the efficacy and safety of MAS063D (Atopiclair) in the treatment of mild to moderate atopic dermatitis. *Eur J Dermatol.* 2005;15:31-36.
- Data on file, Chester Valley Pharmaceuticals, Inc., Malvern, Pa.
- Weston S, Halbert A, Richmond P, Prescott SL. Effects of probiotics on atopic dermatitis: A randomised controlled trial. *Arch Dis Child.* 2005;90:892-897.

Nonsteroidal Treatment of Atopic Dermatitis *Continued from page 11*

Attention to vehicle and barrier function is essential in the search for a safe and effective treatment regimen for AD. A new nonsteroidal cream with antiinflammatory properties has shown benefits in treating AD, including repair and restoration of disrupted skin barrier and replenishment of skin lipid levels.²⁵ It is a safe, effective, and well-tolerated therapy for AD patients of all ages and it reduces the need for additional therapies.²³ Adding PEA nonsteroidal cream to corticosteroid therapy leads to longer remissions, has a corticosteroid-sparing effect,^{23,25} and represents a significant advance in current treatment options for AD. ■

References

- Eichenfield LF, Hanifin JM, Luger TA, Stevens SR, Pride HB. Consensus conference on pediatric atopic dermatitis. *J Am Acad Dermatol.* 2003;49:1088-1095.
- Moore MM, Rifas-Shiman SL, Rich-Edwards JW, et al. Perinatal predictors of atopic dermatitis occurring in the first six months of life. *Pediatrics.* 2004;113:468-474.
- Hoare C, Li Wan Po A, Williams H. Systematic review of treatments for atopic eczema. *Health Technol Assess* [serial online]. 2000;4. Available at: <http://www.ncchta.org/execsumm/summ437.htm>. Accessed January 15, 2006.
- Krafchik BR. Atopic dermatitis. *eMedicine.* 2004. Available at: <http://www.emedicine.com/derm/topic38.htm>. Accessed January 15, 2006.
- Leung DY, Boguniewicz M, Howell MD, Nomura I, Hamid QA. New insights into atopic dermatitis. *J Clin Invest.* 2004;113:651-657.
- National Institute of Arthritis and Musculoskeletal and Skin Diseases. *Handout on Health: Atopic Dermatitis.* 2003. Available at: <http://www.niams.nih.gov/hi/topics/dermatitis>. Accessed January 15, 2006.
- Jorizzo JL. The palmitoylethanolamide family: A new treatment choice for atopic dermatitis? Poster presented at: 63rd Annual Meeting of the American Academy of Dermatology; February 18-22, 2005; New Orleans, La. Poster P729.
- Werner Y, Lindberg M. Trans epidermal water loss in dry and clinically normal skin in patients with atopic dermatitis. *Acta Derm Venereol.* 1985;65:102-105.
- Beltrani VS, Boguniewicz M. Atopic dermatitis. *Dermatol Online J* [serial online]. 2003;9. Available at: <http://www.medscape.com/viewarticle/451667>. Accessed January 15, 2006.
- Carroll CL, Balkrishnan R, Feldman SR, Fleischer AB Jr, Manuel JC. The burden of atopic dermatitis: Impact on the patient, family, and society. *Pediatr Dermatol.* 2005;22:192-199.
- Abramovits W. Atopic dermatitis. *J Am Acad Dermatol.* 2005;53(1 Suppl):S86-S93.
- Lambert DM, Vandevoorde S, Jonsson KO, Fowler CJ. The palmitoylethanolamide family: A new class of anti-inflammatory agents? *Curr Med Chem.* 2002;9:663-674.
- Macheleidt O, Kaiser HW, Sandhoff K. Deficiency of epidermal protein-bound omega-hydroxyceramides in atopic dermatitis. *J Invest Dermatol.* 2002;119:166-173.
- Sator PG, Schmidt JB, Hönigsmann H. Comparison of epidermal hydration and skin surface lipids in healthy individuals and in patients with atopic dermatitis. *J Am Acad Dermatol.* 2003;48:352-358.
- DiRuggiero DC, Smith J. Atopic dermatitis: Employing a new treatment paradigm. *Skin & Aging.* 2004;5:58-67.
- Charman CR, Morris AD, Williams HC. Topical corticosteroid phobia in patients with atopic eczema. *Br J Dermatol.* 2000;142:931-936.
- Ashcroft DM, Dimmock P, Garside R, Stein K, Williams HC. Efficacy and tolerability of topical pimecrolimus and tacrolimus in the treatment of atopic dermatitis: Meta-analysis of randomised controlled trials. *BMJ.* 2005;330:516.
- FDA Public Health Advisory. Elidel (pimecrolimus) cream and Protopic (tacrolimus) ointment. March 10, 2005. Available at: http://www.fda.gov/cder/drug/advisory/elidel_protopic.htm. Accessed January 17, 2006.
- American Academy of Dermatology Meeting Report. Summary of new information presented at: 60th Annual Meeting of the American Academy of Dermatology; February 2002; New Orleans, La. Available at: <http://www.cmwebed.com/derm/aadmtng.htm>. Accessed January 17, 2006.
- Russell JJ. Topical tacrolimus: A new therapy for atopic dermatitis. *Am Fam Physician.* 2002;66:1899-1902.
- Campbell ML. Tacrolimus bests pimecrolimus for treatment of AD. *Dermatology Times* [serial online]. 2004. Available at: <http://www.dermatologytimes.com/dermatologytimes/article/articleDetail.jsp?id=124891>. Accessed January 17, 2006.
- Spagnola C. Atopic dermatitis. *eMedicine.* 2004. Available at: <http://www.emedicine.com/ped/topic2567.htm>. Accessed January 17, 2006.
- Eberlein-Koenig B, Eicke C, Reinhardt H-W, Ring J. Adjuvant treatment of atopic eczema: assessment of an emollient containing N-palmitoylethanolamine (ATOPA). Abstract submitted for presentation at: 64th Annual Meeting of the American Academy of Dermatology; March 2006; San Francisco, Calif.
- Llorca MA, Dorado Bris JM, Sáenz de Santamaría MC, Añeri Más V, Garay Arconada, Pérez Muñelo A. Evaluation of the activity of a moisturizing and restoring-action preparation, with lamellar structure, as adjuvant in the treatment of atopic dermatitis and xerotic skin. *Rev Intern Dermatol Dermocosm.* 2003;6:425-430.
- Data on file, Stiefel Laboratories, Inc., Coral Gables, Fla.