

1-MINUTE CONSULT

MOSTAFA AHMED, MD

Research Fellow, Department of Pulmonary, Allergy, and Critical Care Medicine, Respiratory Institute, Cleveland Clinic, Cleveland, OH; Assistant Lecturer, Department of Chest Diseases, Faculty of Medicine, Assiut University, Assiut, Egypt

RAED A. DWEIK, MD

Director of Pulmonary Vascular Diseases Program, Department of Pulmonary, Allergy, and Critical Care Medicine, Respiratory Institute, Cleveland Clinic; Professor, Cleveland Clinic Lerner College of Medicine of Case Western Reserve University, Cleveland, OH

ADRIANO R. TONELLI, MD

Staff, Department of Pulmonary, Allergy, and Critical Care Medicine, Respiratory Institute, Cleveland Clinic; Assistant Professor, Cleveland Clinic Lerner College of Medicine of Case Western Reserve University, Cleveland, OH

Q: What is the best approach to a high systolic pulmonary artery pressure on echocardiography?

A: The incidental finding of high systolic pulmonary artery pressure on echocardiography is common. What we should do about it varies according to clinical presentation, comorbidities, and results of other tests, including assessment of the right ventricle. Thus, the optimal approach ranges from no further investigation to right heart catheterization and, in some cases, referral to a pulmonary hypertension center.

■ THE TWO MEASUREMENTS COMPARED

Although it raises concern, the finding of high systolic pulmonary artery pressure is not enough to diagnose pulmonary hypertension. In fact, several other conditions are associated with high systolic pulmonary artery pressure on echocardiography (Table 1). The diagnosis must be confirmed with right heart catheterization.¹

Echocardiography provides an estimate of the systolic pulmonary artery pressure that is calculated from other values, whereas right heart catheterization gives a direct measurement of the mean pulmonary artery pressure, which is necessary for diagnosing pulmonary hypertension. The two values are correlated, but the differences are noteworthy.

■ WHAT IS PULMONARY HYPERTENSION?

Pulmonary hypertension is defined by a resting mean pulmonary artery pressure 25 mm Hg or greater during right heart catheterization.¹ The large number of conditions associated with pulmonary hypertension can be divided into five groups²:

- Group 1, pulmonary artery hypertension
- Group 2, pulmonary hypertension associated with left heart disease

- Group 3, pulmonary hypertension due to chronic lung disease or hypoxia
- Group 4, chronic thromboembolic pulmonary hypertension
- Group 5, pulmonary hypertension due to unclear multifactorial mechanisms.²

Pulmonary artery hypertension (group 1) is a syndrome characterized by a restricted flow of small pulmonary arteries that can be idiopathic, heritable, or induced by anorexigens, connective tissue disease, congenital heart disease, portal hypertension, human immunodeficiency virus (HIV), or schistosomiasis.^{2,3} In spite of significant advances in therapy in the last 3 decades, pulmonary artery hypertension continues to lead to right heart failure and death,⁴ and the diagnosis has adverse prognostic implications. Therefore, it is essential to be attentive when reviewing the echocardiogram, since an elevated systolic pulmonary artery pressure may be an important clue to pulmonary hypertension.

■ ESTIMATED PRESSURE: HOW HIGH IS TOO HIGH?

There is no consensus on the optimal cutoff of echocardiographic systolic pulmonary artery pressure to trigger a further evaluation for pulmonary hypertension.

A retrospective evaluation of nearly 16,000 normal echocardiograms found that the 95% upper limit for systolic pulmonary artery pressure was 37 mm Hg.⁵

European guidelines⁶ propose that pulmonary hypertension is unlikely if the estimated systolic pulmonary artery pressure is 36 mm Hg or lower, possible if it is 37 to 50 mm Hg, and likely if it is higher than 50 mm Hg.⁶

The 2009 consensus document of the

Approaches range from no further testing to right heart catheterization to referral

TABLE 1

Causes of elevated systolic pulmonary artery pressure on echocardiography

| Echocardiographic limitations | Constitutional factors | High cardiac output states | Elevated right ventricular afterload |
|---|---------------------------|--|--------------------------------------|
| Inadequate tricuspid regurgitant jet envelope | Age older than 50 | Pregnancy | Pulmonary hypertension |
| Poor estimation of right atrial pressure | Obesity | Anemia | Pulmonary embolism |
| Doppler gain too high | Decreased blood viscosity | Cirrhosis | Unilateral pneumonectomy |
| | Small right atrium | Hyperthyroidism | |
| | | Arteriovenous fistula | |
| | | Beriberi | |
| | | Skeletal disorders (osteitis deformans, polyostotic fibrous dysplasia, multiple myeloma) | |

American College of Cardiology Foundation and American Heart Association³ recommends a systolic pulmonary artery pressure greater than 40 mm Hg as the threshold to suggest further evaluation in a patient with unexplained dyspnea.

Converting the systolic pulmonary artery pressure to the mean pressure

Although not validated to use with echocardiography, the most accurate estimate of mean pulmonary artery pressure was shown in one study⁷ to be obtained with the equation:

$$0.61 \times \text{systolic pulmonary artery pressure} + 2 \text{ mm Hg}$$

Using this formula, a systolic pulmonary artery pressure of 37 mm Hg would correspond to a mean pulmonary artery pressure of 24.6 mm Hg. A systolic pulmonary artery pressure of 40 mm Hg would correspond to a mean pulmonary artery pressure of 26.4 mm Hg.

Estimated systolic pulmonary artery pressure depends on several variables

Systolic pulmonary artery pressure is estimated using the simplified Bernoulli equation⁸:

$$4 \times \text{tricuspid regurgitation jet velocity}^2 \text{ (m/s)} + \text{right atrial pressure (mm Hg)}$$

Tricuspid regurgitation is present in over 75% of the normal population. The regurgitation velocity across the tricuspid valve must be measured to estimate the pressure gradient

between the right ventricle and the right atrium. The right atrial pressure is estimated from the diameter of the inferior vena cava and the degree of inspiratory collapse with the sniff test. As the right atrial pressure increases, the inferior vena cava dilates and inspiratory collapse decreases.⁸ If there is no gradient across the right ventricular outflow tract or pulmonary valve, the right ventricular systolic pressure is equal to the systolic pulmonary artery pressure.

Since tricuspid regurgitation velocity is squared and then multiplied by 4, small deviations of this measurement lead to markedly different systolic pulmonary artery pressure values. To avoid this problem, the tricuspid regurgitation velocity needs to be looked at in multiple echocardiographic views to find the best alignment with the flow and an adequate envelope.

Many causes of high estimated systolic pulmonary artery pressure

Table 1 shows conditions associated with a high estimated systolic pulmonary artery pressure. Echocardiographic limitations, constitutional factors, and high cardiac output states can lead to an apparent elevation in systolic pulmonary artery pressure, which is not confirmed later during right heart catheterization.

Systolic pulmonary artery pressure increases with age and body mass index as a result of worsening left ventricular diastolic dysfunction.

There is no consensus on the optimal echocardiographic cutoff to trigger further testing for pulmonary hypertension

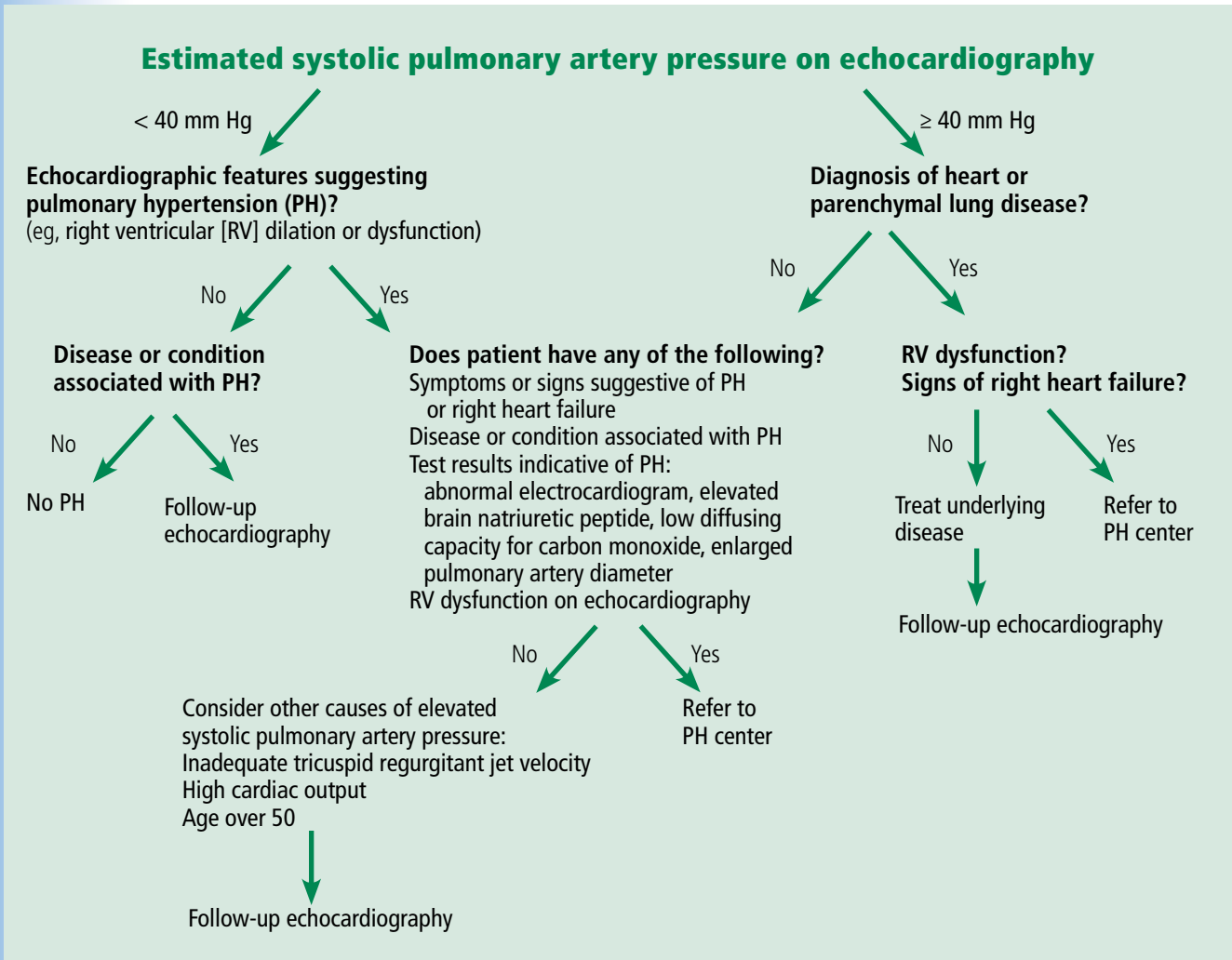


FIGURE 1. An algorithmic approach to the assessment of systolic pulmonary artery pressure on echocardiography.

Adapted in part from the diagnostic approach to pulmonary hypertension recommended by the Fifth World Symposium on Pulmonary Hypertension (reference 6).

tion.⁸ In fact, an estimated pressure greater than 40 mm Hg is found³ in 6% of people over age 50 and in 5% of people with a body mass index greater than 30 kg/m². It can also be high in conditions in which there is an increase in cardiac output, such as pregnancy, anemia (sickle cell disease, thalassemia), cirrhosis, and arteriovenous fistula.

The estimated systolic value often differs from the measured value

Studies have compared the systolic pulmonary artery pressure measured during right heart catheterization with the estimated value on echocardiography.^{9,10} These studies noted a reasonable degree of agreement between the

tests but a substantial variability.

Both underestimation and overestimation of the systolic pulmonary artery pressure by echocardiography were common, with 95% limits of agreement ranging from minus 40 mm Hg to plus 40 mm Hg.^{9,10} A difference of plus or minus 10 mm Hg in systolic pulmonary artery pressure between echocardiography and catheterization was observed in 48% to 51% of patients with pulmonary hypertension, particularly in those with higher systolic pulmonary artery pressure.^{9,10}

An important reason for overestimation of systolic pulmonary artery pressure is the inaccurate estimation of the right atrial pressure by echocardiography.^{9,10} Indeed, this factor

may account for half of the cases in which the systolic pulmonary artery pressure is overestimated.¹⁰ Although the traditional methods to estimate the right atrial pressure have been revisited,^{8,11} this estimation is less reliable for intermediate pressure values, for patients on mechanical ventilation, and for young athletes.⁸

Other explanations for the variability between measured and estimated systolic pulmonary artery pressure include suboptimal alignment between the Doppler beam and the regurgitant jet, severe tricuspid regurgitation, arrhythmias, and limitations inherent to the simplified Bernoulli equation.¹² The estimated value is particularly inaccurate in patients with advanced lung disease, possibly owing to lung hyperinflation and alteration in the thoracic cavity and position of the heart—all factors that limit visualization and measurement of the tricuspid regurgitant jet.¹³

■ OTHER SIGNS OF PULMONARY HYPERTENSION ON ECHOCARDIOGRAPHY

Echocardiography provides information that is useful in assessing the accuracy of the estimated systolic pulmonary artery pressure, particularly right ventricular size and function.

As pulmonary hypertension progresses, the right ventricle dilates, and its function is compromised. Therefore, it is important to determine the right ventricular size and function by using objective echocardiographic findings such as right ventricular diameters (basal, mid, apical) and area, right ventricular fractional area change, tricuspid annular plane systolic excursion, myocardial performance index, and the pulsed tissue Doppler tricuspid annular peak systolic excursion velocity.⁸

Other echocardiographic features that suggest pulmonary hypertension include a dilated right atrial area, flattening of the interventricular septum, notching of the right ventricular outflow tract flow, and dilation of the main pulmonary artery. Interestingly, left ventricular diastolic dysfunction of the impaired relaxation type (grade I) is commonly observed in pulmonary hypertension¹⁴; however, more advanced degrees of diastolic dysfunction, ie, pseudonormalization (grade II) or restrictive left ventricular filling (grade III),¹⁵

particularly when associated with a left atrial enlargement, suggest pulmonary hypertension associated with left heart disease and not pulmonary artery hypertension.

■ WHAT TO DO IF ECHOCARDIOGRAPHY INDICATES PULMONARY HYPERTENSION

An algorithm showing the approach to an elevated systolic pulmonary artery pressure on echocardiography is presented in **Figure 1**.

In the appropriate clinical setting, if the systolic pulmonary artery pressure is 40 mm Hg or greater or if other echocardiographic variables suggest pulmonary hypertension, our practice is to proceed with right heart catheterization.

Clinical variables that suggest pulmonary hypertension include progressive dyspnea, chest pain, presyncope-syncope, lower extremity edema, hepatomegaly, jugular vein distention, hepatojugular reflux, sternal heave, loud second heart sound (P2), murmur of tricuspid or pulmonary regurgitation, and right ventricular third heart sound.¹⁶ These are of particular interest when associated with conditions known to cause pulmonary hypertension,² such as connective tissue disease, portal hypertension, congenital heart disease, HIV infection, and certain drugs and toxins.

Other tests that raise suspicion of pulmonary hypertension are an electrocardiogram suggesting a dilated right atrium or ventricle, an elevated brain natriuretic peptide level, a low carbon monoxide diffusing capacity on pulmonary function testing, and an enlarged pulmonary artery diameter on imaging.

Given the high prevalence of pulmonary hypertension, the Fifth World Symposium on Pulmonary Hypertension recommended first considering heart or parenchymal lung disease when an echocardiogram suggests pulmonary hypertension.⁶ If there are signs of severe pulmonary hypertension or right ventricular dysfunction, referral to a center specializing in pulmonary hypertension is recommended. Referral is also appropriate when there is no major heart or lung disease and the echocardiogram shows an elevated systolic pulmonary artery pressure, particularly when the clinical presentation or results of other testing suggest pulmonary hypertension.

If there are signs of severe pulmonary hypertension or RV dysfunction, referral to a pulmonary hypertension center is recommended

■ TAKE-HOME POINTS

In the appropriate context, a high systolic pulmonary artery pressure on echocardiography suggests pulmonary hypertension, but right heart catheterization is needed to confirm the

diagnosis. Estimating the systolic pulmonary artery pressure with echocardiography has limitations, including false-positive results, predominantly when the pretest probability of pulmonary hypertension is low. ■

■ REFERENCES

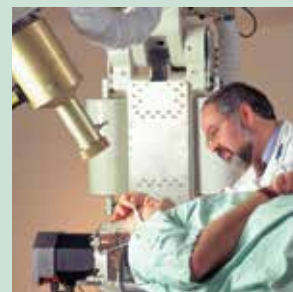1. Hoyer MM, Bogaard HJ, Condliffe R, et al. Definitions and diagnosis of pulmonary hypertension. *J Am Coll Cardiol* 2013; 62(suppl D):D42–D50.
2. Simonneau G, Gatzoulis MA, Adatia I, et al. Updated clinical classification of pulmonary hypertension. *J Am Coll Cardiol* 2013; 62(suppl D):D34–D41.
3. McLaughlin VV, Archer SL, Badesch DB, et al; American College of Cardiology Foundation Task Force on Expert Consensus Documents; American Heart Association; American College of Chest Physicians; American Thoracic Society, Inc; Pulmonary Hypertension Association. ACCF/AHA 2009 expert consensus document on pulmonary hypertension a report of the American College of Cardiology Foundation Task Force on Expert Consensus Documents and the American Heart Association developed in collaboration with the American College of Chest Physicians; American Thoracic Society, Inc.; and the Pulmonary Hypertension Association. *J Am Coll Cardiol* 2009; 53:1573–1619.
4. Tonelli AR, Arelli V, Minai OA, et al. Causes and circumstances of death in pulmonary arterial hypertension. *Am J Respir Crit Care Med* 2013; 188:365–369.
5. McQuillan BM, Picard MH, Leavitt M, Weyman AE. Clinical correlates and reference intervals for pulmonary artery systolic pressure among echocardiographically normal subjects. *Circulation* 2001; 104:2797–2802.
6. Galiè N, Hoyer MM, Humbert M, et al; ESC Committee for Practice Guidelines (CPG). Guidelines for the diagnosis and treatment of pulmonary hypertension: the Task Force for the Diagnosis and Treatment of Pulmonary Hypertension of the European Society of Cardiology (ESC) and the European Respiratory Society (ERS), endorsed by the International Society of Heart and Lung Transplantation (ISHLT). *Eur Heart J* 2009; 30:2493–2537.
7. Chemla D, Castelain V, Provencher S, Humbert M, Simonneau G, Herve P. Evaluation of various empirical formulas for estimating mean pulmonary artery pressure by using systolic pulmonary artery pressure in adults. *Chest* 2009; 135:760–768.
8. Rudski LG, Lai WW, Afilalo J, et al. Guidelines for the echocardiographic assessment of the right heart in adults: a report from the American Society of Echocardiography endorsed by the European Association of Echocardiography, a registered branch of the European Society of Cardiology, and the Canadian Society of Echocardiography. *J Am Soc Echocardiogr* 2010; 23:685–713.
9. Rich JD, Shah SJ, Swamy RS, Kamp A, Rich S. Inaccuracy of Doppler echocardiographic estimates of pulmonary artery pressures in patients with pulmonary hypertension: implications for clinical practice. *Chest* 2011; 139:988–993.
10. Fisher MR, Forfia PR, Chamera E, et al. Accuracy of Doppler echocardiography in the hemodynamic assessment of pulmonary hypertension. *Am J Respir Crit Care Med* 2009; 179:615–621.
11. Brennan JM, Blair JE, Goonewardena S, et al. Reappraisal of the use of inferior vena cava for estimating right atrial pressure. *J Am Soc Echocardiogr* 2007; 20:857–861.
12. Giardini A, Tacy TA. Non-invasive estimation of pressure gradients in regurgitant jets: an overdue consideration. *Eur J Echocardiogr* 2008; 9:578–584.
13. Arcasoy SM, Christie JD, Ferrari VA, et al. Echocardiographic assessment of pulmonary hypertension in patients with advanced lung disease. *Am J Respir Crit Care Med* 2003; 167:735–740.
14. Tonelli AR, Plana JC, Heresi GA, Dweik RA. Prevalence and prognostic value of left ventricular diastolic dysfunction in idiopathic and heritable pulmonary arterial hypertension. *Chest* 2012; 141:1457–1465.
15. Nagueh SF, Appleton CP, Gillebert TC, et al. Recommendations for the evaluation of left ventricular diastolic function by echocardiography. *J Am Soc Echocardiogr* 2009; 22:107–133.
16. Barst RJ, McGoan M, Torbicki A, et al. Diagnosis and differential assessment of pulmonary arterial hypertension. *J Am Coll Cardiol* 2004; 43(suppl S):405–475.

ADDRESS: Raed A. Dweik, MD, Department of Pulmonary, Allergy, and Critical Care Medicine, Respiratory Institute, A90, Cleveland Clinic, 9500 Euclid Avenue, Cleveland, OH 44195; dweikr@ccf.org



LET US HEAR FROM YOU

- Let us hear your opinions about the *Cleveland Clinic Journal of Medicine*.
- Do you like current articles and sections?
- What topics would you like to see covered and how can we make the *Journal* more useful to you?



PHONE 216.444.2661
 FAX 216.444.9385
 E-MAIL ccjm@ccf.org
 WWW <http://www.ccjm.org>

CLEVELAND CLINIC JOURNAL OF MEDICINE
 Cleveland Clinic
 1950 Richmond Rd., TR404
 Lyndhurst, Ohio 44124