

Synchronous presentation of advanced rectal and intermediate-risk prostate cancers: a multidisciplinary approach

John M. Watkins, MD,¹ Edward Wos, MD,² Douglas Berglund, MD,³ Karna Colby, MD,⁴ Tarek A. Dufan, MD,¹ and Nadim Koleilat, MD⁵

¹Bismarck Cancer Center; Departments of ²Hematology and Oncology, MedCenter One Health Systems; ³Surgery, MedCenter One Health Systems; ⁴Pathology, MedCenter One Health Systems; ⁵Urology, MedCenter One Health Systems, Bismarck, ND

Primary prostate and colorectal carcinomas represent the most common primary cancers in men in the United States;¹ however, rarely do the two cancers present within the same patient, and only anecdotal reports have identified synchronous presentation.²⁻⁶ Although a primary surgical approach has been described in most of those reports,²⁻⁴ we here report the successful use of preoperative chemoradiotherapy followed by rectal tumor resection in the community setting for a patient with synchronous presentation of primary prostate and rectal carcinomas.

Case presentation

A 76-year-old man with a good performance status but a relevant medical history of coronary artery disease after stent placement, paroxysmal atrial fibrillation (off warfarin, on 81 mg of aspirin daily), mitral valve repair, and abdominal aortic aneurysm repair presented to his primary care physician with complaints of right groin discomfort consistent with recurrence of a previously repaired hernia. He also described incidental painless, small-volume blood mixed with stools occurring 3 to 4 times a week, always associated with constipation and hard bowel movements. Examination did not demonstrate a hemorrhoid, fissure, or mass; however, the results of a Guaiac test were positive.

The patient was referred to his surgeon for combined right inguinal herniorrhaphy and colonoscopy. Hernia repair was completed without complication; however, the colonoscopy re-

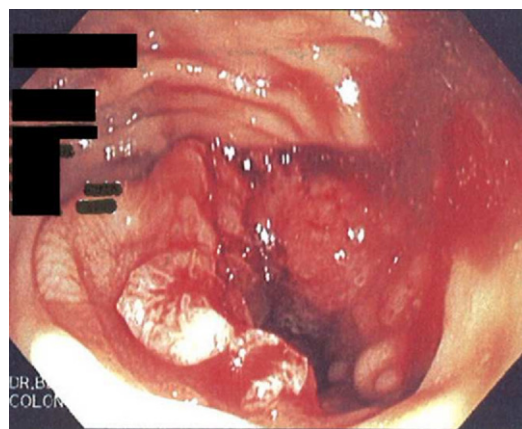


FIGURE 1 A rectal mass was noted near the midrectal valve during the colonoscopy.

sults showed a mass at the level of the midrectal valve (Figure 1). Tests on a biopsy showed an invasive, moderately differentiated adenocarcinoma (Figure 2).

A work-up included CT scans of the chest, abdomen, and pelvis. Scans for the pelvis were suspicious for perirectal fat stranding and two small (< 1 cm) perirectal lymph nodes (Figure 3a); otherwise, abdominal and liver fields were clear, as were osseous structures. Of note was that the left lobe of the prostate was prominent on CT scan, with a somewhat discrete region of contrast enhancement (Figure 3b). A 2.4-cm pleura-based, right lower-lobe opacity was also noted; however, the patient was a lifelong nonsmoker and had a recent history of infection, so based on the radiographic characteristics, this finding was considered to be a resolving scar. PET/CT imaging demon-

Manuscript received August 8, 2011; accepted August 11, 2011.

Correspondence: John M. Watkins, MD, Bismarck Cancer Center, 500 North 7th Street, Bismarck, ND 58501; e-mail: john.m.watkins.md@hotmail.com.

Disclosures: None of the authors reports actual or potential financial conflicts with respect to this manuscript.

Commun Oncol 2012;9:67-72 © 2012 Elsevier Inc. All rights reserved. doi:10.1016/j.cmonc.2011.12.008

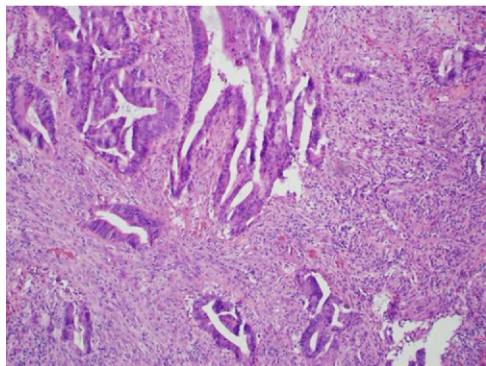


FIGURE 2 A histopathological image of the biopsied rectal mass showed an invasive, moderately differentiated adenocarcinoma.

strated uptake only within the rectal primary node and questionably an adjacent node. The patient had an MRI scan to further delineate the primary tumor and pelvic lymphatics; there was a suggestion of loss of plane along the muscularis propria extending into the perirectal fat and also two lymph nodes (< 1 cm) with a seemingly suspicious morphology. The patient was referred to medical and radiation oncology specialists, who recommended a preoperative chemoradiotherapy approach to address the rectal primary tumor.

During a pretreatment physical examination, a digital rectal examination suggested asymmetric bilateral prostate enlargement, with nodular induration involving the left base and midgland. Because chemotherapy and pelvic radiotherapy had been recommended, a serologic work-up was performed and included a prostate-specific antigen (PSA) measurement because of the physical examination and radiographic findings. The carcinoembryonic antigen (CEA) value was 2.0 ng/mL, and the PSA value was elevated at 10.1 ng/mL (it had been 6.1 ng/mL a year earlier, with a negative biopsy result at the time). Of note was that the patient had been on daily finasteride at the time of both PSA evaluations. Transrectal ultrasonography-guided biopsies of the prostate were recommended because of the progressive rise in PSA level and the suspicious findings.

Pathologic evaluation showed an adenocarcinoma within three of the six sampled core regions, with the highest Gleason score of 4 + 3 (Figure 4). A multidisciplinary team of specialists discussed the management options and recommended definitive radiotherapy to the prostate (without hormonal therapy), with concurrent chemoradiotherapy to the rectal primary tumor and regional lymphatics.

Following CT-based simulation, an intensity-modulated radiotherapy (IMRT) plan was designed to cover the sites of established disease, as well as those at risk of harboring

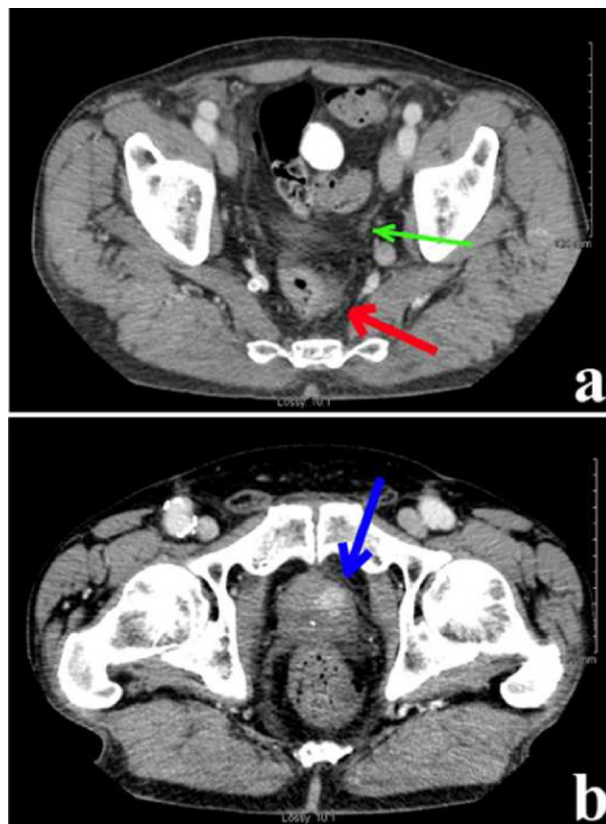


FIGURE 3 Staging CT scan images demonstrate (a) the cranial edge of the rectal primary (red arrow), a suspicious perirectal lymph node (green arrow), and (b) contrast enhancement within the prostate (blue arrow).

metastatic disease, while minimizing the dose to adjacent uninvolved organs such as the bladder, femoral heads, and small bowel. The patient began radiotherapy to the prostate (1,800 cGy over 10 once-daily fractions); that treatment was followed by continuation of radiotherapy to the prostate, seminal vesicles, rectal primary tumor, and pelvic lymphatics through 25 additional fractions over 5 weeks (4,500 cGy to the aforementioned sites; 6,300 cGy cumulatively to the prostate). Thereafter, the patient received a 3-fraction boost to the rectal primary tumor, the seminal vesicles, and the prostate (5,040 cGy to the rectal primary tumor; 6,840 cGy to the seminal vesicles and prostate) followed by completion of dose to the prostate to 7920 cGy cumulative dose (Figure 5).

Chemotherapy involved 5-fluorouracil (225 mg/m² daily for 7 days, by continuous infusion), initiated at fraction 11 (the first treatment to the rectal primary tumor and the pelvic lymphatics) and discontinued after completion of the dose to the rectal primary tumor. The patient tolerated the treatment very well, with improved rectal bleeding during treatment (none by the midpoint of

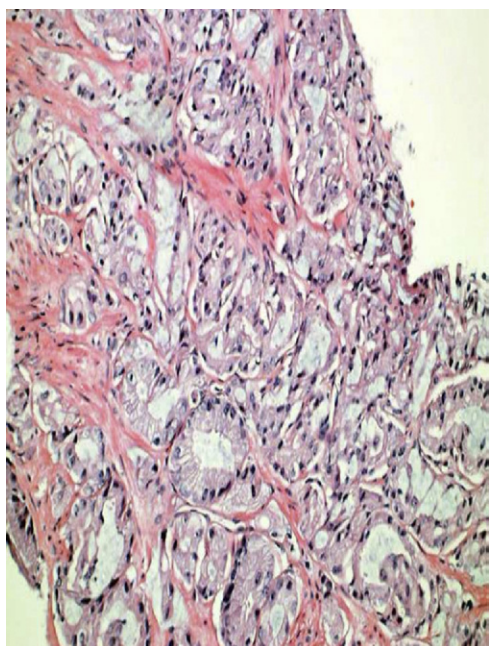


FIGURE 4 Pathologic evaluation demonstrated an adenocarcinoma within three of the six sampled core regions.

treatment); early intermittent loose stools improved after dose reduction of 5-fluorouracil to 5 days a week. He experienced moderate perianal discomfort near the completion of treatment, which was managed conservatively with dietary modification. The patient did not describe any noticeable change in urinary habit during or after treatment.

Five weeks after the completion of all radiotherapy, the patient underwent an extended low anterior resection of the primary tumor, with colorectal J-pouch anastomosis reconstruction and temporary diverting ileostomy. Pathology demonstrated a near pathologic complete response, with only a single minute focus (< 1 mm) of residual invasive tumor (Figure 6), with negative margins and no evidence of lymphovascular space or perineural tumor invasion. Ten lymph nodes were identified and were found to be negative for malignancy. The patient tolerated the procedure well, and ileostomy takedown with re-anastomosis was performed within 1 month of the resection.

During this time, the PSA value decreased rapidly, to 2.2 ng/mL, 1.3 ng/mL, 0.8 ng/mL, and 0.5 ng/mL (off finasteride) at 2, 5, 7, and 11 months, respectively, after radiotherapy. Surveillance CT scans at 7 months did not show any evidence of recurrent or metastatic disease, and the CEA value was 1.9 ng/mL. In particular, the lung nodules that had been noted during initial staging had entirely resolved. One year after the initial diagnosis, the patient was enjoying an excellent performance status,

without significant urinary or rectal symptoms or evidence of recurrent disease.

Discussion

Although prostate and colorectal carcinomas are the most common cancers in men in the United States,¹ synchronous presentation of these tumors is rare. Management of either tumor in isolation requires a multimodality approach, and thus management of the synchronous presentation requires the participation of the surgeon, urologist, medical oncologist, and radiation oncologist to optimize patient outcome in terms of long-term disease control and posttreatment quality of life.

There is significant controversy regarding the role of screening for PSA levels;^{6,7} however, given the current patient's history of elevated PSA levels and the continued rise in his PSA levels, biopsy was warranted. The decision to repeat this assessment of PSA levels was based on a combination of the clinical history, physical examination, radiographic findings, and intent to treat with pelvic radiotherapy.

After the prostate cancer had been identified, the decision to treat was also controversial. Given the patient's age and comorbidities (and the anticipated impact on overall life expectancy), if a low-risk prostate cancer been diagnosed (cT1-2a, Gleason score < 6, and PSA level < 10 ng/mL), then active surveillance with assessment of PSA levels at least every 6 months and annual biopsy would have been a reasonable option. However, in this patient's situation, there were several features that increased his risk for prostate cancer-specific mortality, including PSA velocity (4 ng/mL in 1 year),⁸ a Gleason score of 4 + 3,⁹ and an elevated PSA level (particularly on finasteride, which is known to "mask" the true PSA level by up to half¹⁰). As such, either prostatectomy or radiation therapy was offered—the former at the time of rectal resection, and the latter during the preoperative phase of therapy. The nonsurgical option was recommended because of the patient's age and comorbidities. Modern radiotherapy is most often delivered to target doses approaching 8,000 cGy,¹¹ often with intensity-modulated treatment fields that allow for improved protection of adjacent organs such as the bladder, femoral heads, intestines, and the rectum (when not an additional target).¹²

Our case involved a multidisciplinary discussion of the role of hormonal therapy in the treatment of the prostate primary tumor. A phase III randomized trial has demonstrated improved PSA control and overall survival for patients with intermediate-risk prostate cancer receiving a 6-month course of combined androgen blockade (with a gonadotropin-releasing hormone agonist and an oral antiandrogen); however, a subset analysis showed that the survival benefit was not maintained in patients with mod-

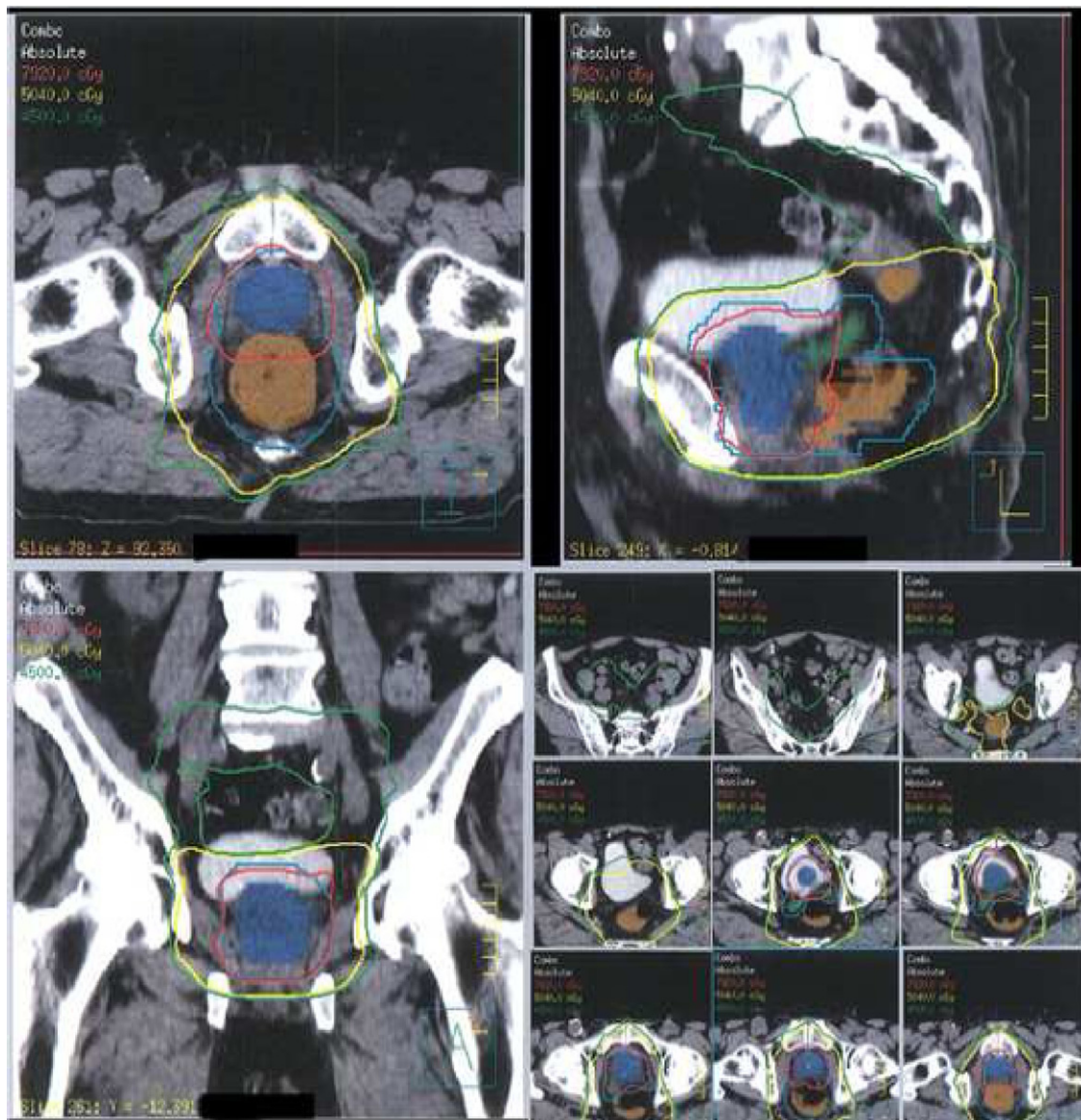


FIGURE 5 Intensity-modulated radiotherapy treatment plan. Axial, sagittal, and coronal plane images with prescription isodose lines, demonstrating coverage of the targets (blue = prostate; green = seminal vesicles; orange = rectal primary tumor; pelvic lymphatics not shaded for presentation clarity). Note the relative sparing of the small bowel, bladder, and femoral heads, which allow for high-dose treatment with minimal adverse effects.

erate to severe medical comorbidities.¹² One concern was an increase in the number of cardiovascular events from the negative metabolic effects of androgen deprivation;¹³ however, this issue was considered “hypothesis-generating,” and further investigation should address that issue. The comorbidity score for this patient qualified him as high risk, so we elected to proceed without testosterone suppression. As reported, the patient tolerated treatment well, and his rapid decline in PSA level suggests an increased likelihood of long-term disease control.¹⁴

Current management of rectal cancer is more straightforward than is the case with prostate cancer. Specific to our case, optimal staging would have included endoscopic ultrasonography, which demonstrates superior T- and N-staging accuracy over CT;¹⁵ however, as with many community settings, this modality is not yet available. The radiographic features were considered suspicious for perirectal extension, with possible low-volume, perirectal nodal involvement. For locoregionally advanced rectal carcinomas, randomized evidence supports preoperative

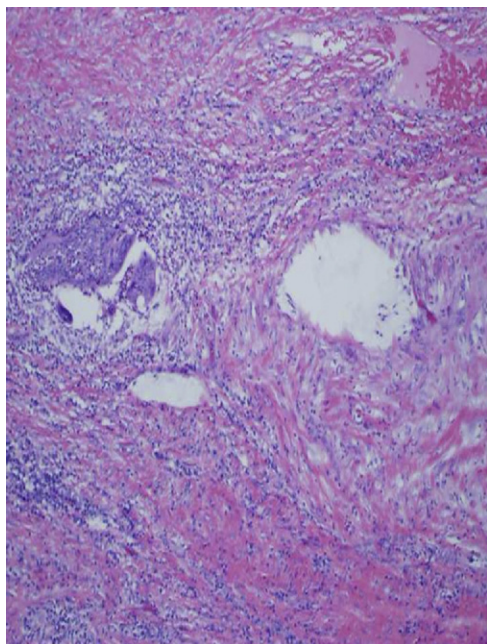


FIGURE 6 A histopathologic image of the low anterior resection specimen post treatment shows a near pathologic complete response, with only a minute focus (1 mm) of residual invasive tumor with negative margins and no evidence of lymphovascular space or perineural tumor invasion.

chemoradiotherapy over adjuvant therapy, with doubling of local tumor control and (for low rectal tumors) improved sphincter-preservation rates.¹⁶ In addition, favorable response to neoadjuvant therapy has been associated with improved long-term disease control.¹⁷ Given the near-complete response of tumor and negative nodal status, the patient is expected to have excellent prospects for long-term disease-free survival.

To our knowledge, there have been only five previously published reports detailing management and outcomes for eight patients with simultaneous presentation of rectal and prostate cancers,²⁻⁶ of whom five underwent an upfront surgical approach²⁻⁴ and three upfront chemoradiotherapy.^{5,6} Of the chemoradiotherapy case reports, which were all documented treatments at large academic centers, chemotherapy was 5-fluorouracil-based, and radiotherapy was administered in a “shrinking-field” technique similar to the present case. Of note is that two of the three patients underwent chemoradiotherapy without subsequent primary rectal tumor resection.⁵ Both of those patients had clinical complete responses at the rectal primary tumor site, without endoscopic evidence of residual tumor at 1 and 2 years, respectively. The third patient also had a pathologic complete response at the primary rectal tumor site, without involved lymph nodes.⁶

With respect to the prostate cancer, two of the three cases were considered at an elevated risk, one each owing to Gleason 4 + 3 disease⁵ and a PSA level of 3ng/mL (with clinically organ-confined, Gleason 3 + 3 adenocarcinoma).⁶ Hormonal therapy was used in the latter case but was discontinued after 6 months because the patient refused to continue with the therapy, which had been recommended for 2 to 3 years total. All three of the patients had disease control of both rectal and prostate cancers at early follow-up (12 to 24 months).

Conclusion

Synchronous presentation of rectal and prostate cancers requires a multidisciplinary approach, with the individualization of therapy based on the patient and clinicopathologic tumor features. Although primary rectal tumors require mesorectal resection with preoperative or postoperative therapy based on stage, both surgical and nonsurgical approaches to prostate cancer have yielded favorable outcomes. Our case demonstrates a favorable response by both primary tumors to a well-tolerated, combined, upfront chemoradiotherapy approach, followed by resection of the rectal primary tumor, within the context of a multidisciplinary community oncology practice setting.

References

1. Jemal A, Siegel R, Xu J, Ward E. Cancer statistics, 2010. *CA Cancer J Clin*. 2010;60:277-300.
2. Baur H, Frimberger M, Altwein JE. Simultaneous radical prostatectomy and partial rectum resection without colostomy. *Eur Urol*. 1997;31:380-381.
3. Klee LW, Grmoljez P. Combined radical retropubic prostatectomy and rectal resection. *Urology*. 1999;54:679-681.
4. Campbell SC, Church JM, Fazio VW, Klein EA, Pontes JE. Combined radical retropubic prostatectomy and proctosigmoidectomy for en bloc removal of locally invasive carcinoma of the rectum. *Surg Gynecol Obstet*. 1993;176:605-608.
5. Siu W, Kapp DS, Wren SM, King C, Terris MK. External beam radiotherapy for synchronous rectal and prostatic tumors. *Urology*. 2001; 57:800.
6. Colonias A, Farinash L, Miller L, et al. Multidisciplinary treatment of synchronous primary rectal and prostate cancers. *Nature Clin Pract Oncol*. 2005;2:271-274.
7. Crawford ED, Grubb R 3rd, Black A, et al. Comorbidity and mortality results from a randomized prostate cancer screening trial. *J Clin Oncol*. 2011;29:355-361.
8. D'Amico AV, Renshaw AA, Sussman B, Chen MH. Pretreatment PSA velocity and risk of death from prostate cancer following external beam radiation therapy. *JAMA*. 2005;294:440-447.
9. Stark JR, Perner S, Stampfer MJ, et al. Gleason score and lethal prostate cancer: does 3 + 4 = 4 + 3? *J Clin Oncol*. 2009;27:3459-3464.
10. Kaplan SA, Ghafar MA, Volpe MA, Lam JS, Fromer D, Te AE. PSA response to finasteride challenge in men with a serum PSA greater than 4 ng/ml and previous negative prostate biopsy: preliminary study. *Urology*. 2002;60:464-468.
11. Eade TN, Hanlon AL, Horwitz EM, Buyyounouski MK, Hanks GE, Pollack A. What dose of external-beam radiation is high enough for prostate cancer? *Int J Radiat Oncol Biol Phys*. 2007;68:682-689.
12. Zelefsky MJ, Chan H, Hunt M, Yamada Y, Shippy AM, Amols H. Long-term outcome of high dose intensity modulated radiation

therapy for patients with clinically localized prostate cancer. *J Urol*. 2006;176:1415-1419.

13. D'Amico AV, Chen MH, Renshaw AA, Loffredo M, Kantoff PW. Androgen suppression and radiation vs radiation alone for prostate cancer: a randomized trial. *JAMA*. 2008;299:289-295.

14. Cavanaugh SX, Kupelian PA, Fuller CD, et al. Early prostate-specific antigen (PSA) kinetics following prostate carcinoma radiotherapy: prognostic value of a time-and-PSA threshold model. *Cancer*. 2004;101:96-105.

15. Brown G. Staging rectal cancer: endoscopic ultrasound and pelvic MRI. *Cancer Imaging*. 2008;8:S43-S45.

16. Sauer R, Becker H, Hohenberger W, et al. Preoperative versus postoperative chemoradiotherapy for rectal cancer. *N Engl J Med*. 2004;351:1731-1740.

17. Maas M, Nelemans PJ, Valentini V, et al. Long-term outcome in patients with a pathological complete response after chemoradiation for rectal cancer: a pooled analysis of individual patient data. *Lancet Oncol*. 2010;11:835-844.