

# Superficial Acral Fibromyxoma and Other Slow-Growing Tumors in Acral Areas

Zachary A. Schwager, MD; Kathleen A. Mannava, MD; Sandeep Mannava, MD, PhD; Gladys H. Telang, MD; Leslie Robinson-Bostom, MD; Nathaniel J. Jellinek, MD

## Practice Points

- Superficial acral fibromyxoma (SAFM) is a rare but distinct tumor that may affect the nail bed and nail plate, and it may clinically or histopathologically mimic other tumors of the distal extremities.
- Although SAFM is considered a benign tumor, it frequently persists or recurs after incomplete excision, and therefore complete local resection may be recommended, particularly for symptomatic lesions.

*Superficial acral fibromyxoma (SAFM) is a rare fibromyxoid mesenchymal tumor with a predilection for the distal extremities and frequent nail bed involvement. Superficial acral fibromyxoma typically arises as a solitary, slow-growing nodule on a toe or finger, with the great toe being the most commonly affected site. Histopathologically, SAFM characteristically presents as a well-circumscribed but unencapsulated dermal tumor composed of spindle and stellate cells in a loose storiform or fascicular arrangement embedded in a myxoid, myxocollagenous, or collagenous stroma. The tumor often occupies the entire dermis and may extend into the subcutis and occasionally the underlying fascia and bone. The characteristic immunohistochemical profile of SAFM includes expression of CD34, epithelial membrane antigen (EMA), and CD99; it is notably negative for S-100 protein. We report 3 cases of SAFM and also provide a review of the literature on the*

*clinical and histopathologic presentations of this unique entity as well as the differential diagnosis.*

*Cutis. 2015;95:E15-E19.*

First described by Fetsch et al<sup>1</sup> in 2001, superficial acral fibromyxoma (SAFM) is a rare fibromyxoid mesenchymal tumor that typically affects the fingers and toes with frequent involvement of the nail unit. It is not widely recognized and remains poorly understood. We describe a series of 3 cases of SAFM encountered at our institution and provide a review of the literature on this unique tumor.

## Case Reports

**Patient 1**—A 35-year-old man presented for treatment of a “wart” on the right fifth toe that had increased in size over the last year. He reported that the lesion was mildly painful and occasionally bled or drained clear fluid. He also noted cracking of the nail plate on the same toe. Physical examination revealed a firm, flesh-colored, 3-mm dermal papule on the proximal nail fold of the right fifth toe with subtle flattening of the underlying nail plate (Figure 1). The patient underwent biopsy of the involved proximal nail fold. Histopathology revealed a proliferation of small oval and spindle cells arranged in fascicles and bundles in the dermis (Figure 2). There was extensive mucin deposition associated with the spindle cell proliferation. Additionally, spindle cells and mucin surrounded and entrapped collagen bundles on the periphery of the lesion.

---

Drs. Schwager, K.A. Mannava, Telang, Robinson-Bostom, and Jellinek are from the Department of Dermatology, Warren Alpert Medical School, Brown University, Providence, Rhode Island. Dr. Jellinek also is from the Division of Dermatology, University of Massachusetts Medical School, Worcester. Dr. S. Mannava is from the Department of Orthopedic Surgery, Wake Forest University School of Medicine, Winston-Salem, North Carolina.

The authors report no conflict of interest.

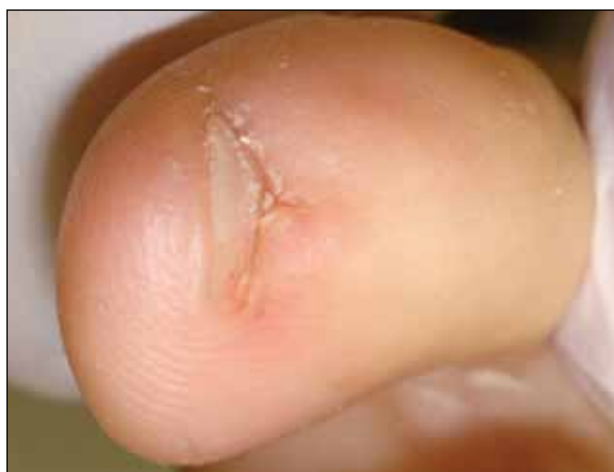Correspondence: Kathleen A. Mannava, MD, Department of Dermatology, Warren Alpert Medical School of Brown University, 593 Eddy St, APC 10, Providence, RI 02903 (kat.carroll@gmail.com).

Lesional cells were diffusely positive for CD34 and extended to the deep surgical margin (Figure 3). S-100 and factor XIIIa stains were negative. The diagnosis of SAFM was made based on the acral location, histopathologic appearance, and immunohistochemical profile of the tumor.

*Patient 2*—A 47-year-old man presented with an asymptomatic growth on the left fourth toe that had increased in size over the last year. Physical examination revealed an 8-mm, firm, fleshy, flesh-colored, smooth and slightly pedunculated papule on the distal aspect of the left fourth toe. The nail plate and periungual region were not involved. A shave biopsy of the papule was obtained. Histopathology demonstrated dermal stellate spindle cells arranged in a loose fascicular pattern with marked mucin deposition

throughout the dermis (Figure 4). Lesional cells were positive for CD34. An S-100 stain highlighted dermal dendritic cells, but lesional cells were negative. No further excision was undertaken, and there was no evidence of recurrence at 1-year follow-up. The diagnosis of SAFM was made based on the acral location, histopathologic appearance, and immunohistochemical profile of the tumor.

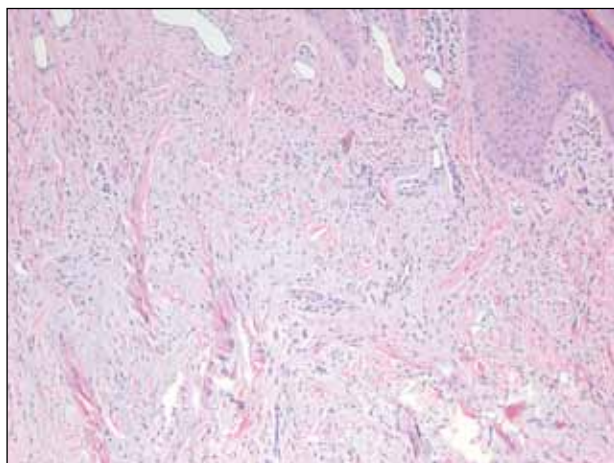
*Patient 3*—A 45-year-old woman presented with asymptomatic distal onycholysis of the right thumbnail of 1 year's duration. She denied any history of trauma, and no bleeding or pigmentary changes were noted. Physical examination revealed a 5-mm flesh-colored papule on the hyponychium of the right thumb with focal onycholysis (Figure 5). A wedge biopsy of the lesion was



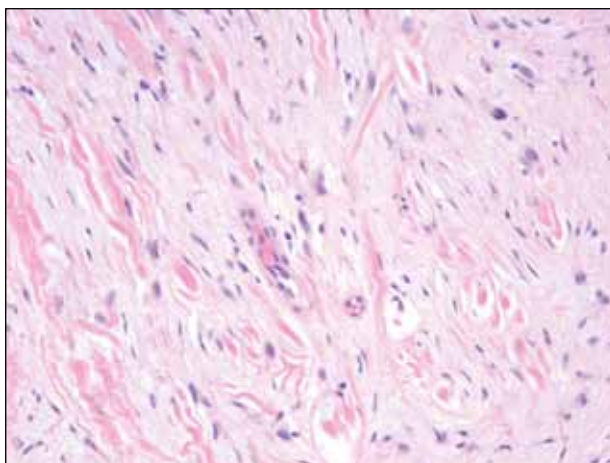
**Figure 1.** Firm dermal papule on the proximal nail fold of the right fifth toe with associated nail plate dystrophy.



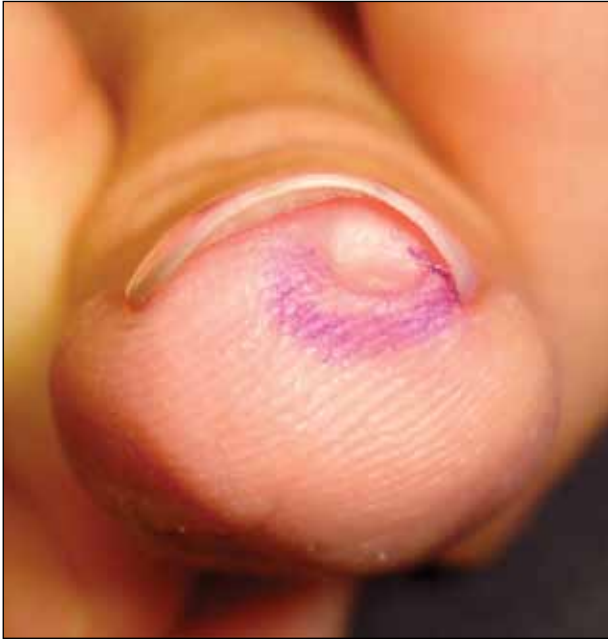**Figure 3.** Tumor cells were positive on CD34 staining (original magnification  $\times 40$ ).



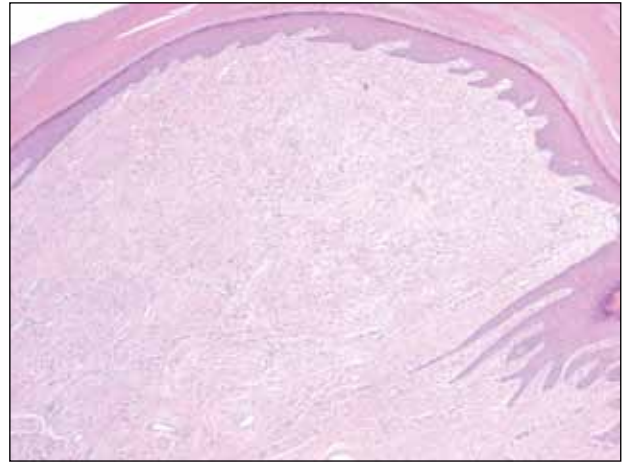
**Figure 2.** Small oval and spindle cells arranged in fascicles and bundles in the dermis, with extensive mucin deposition and collagen trapping (H&E, original magnification  $\times 100$ ).



**Figure 4.** Dermal stellate spindle cells arranged in a loose fascicular pattern with marked mucin deposition (H&E, original magnification  $\times 400$ ).



**Figure 5.** A firm flesh-colored papule on the hyponychium of the right thumb prior to biopsy.



**Figure 6.** Intradermal nodular proliferation of bland spindle cells arranged in loose fascicles and bundles and embedded in a myxoid stroma (H&E, original magnification  $\times 40$ ).

performed. Histopathology showed an intradermal nodular proliferation of bland spindle cells arranged in loose fascicles and bundles and embedded in a myxoid stroma (Figure 6). CD34 staining strongly highlighted lesional cells. S-100 and neurofilament stains were negative. The diagnosis of SAFM was made based on the acral location, histopathologic appearance, and immunohistochemical profile of the tumor.

### Comment

Clinically, SAFM typically presents as a slow-growing solitary nodule on the distal fingers or toes. The great toe is the most commonly affected digit, and the tumor may be subungual in up to two-thirds of cases.<sup>1</sup> Unusual locations, such as the heel, also have been reported.<sup>2</sup> Onset typically occurs in the fifth or sixth decade, and there is an approximately 2-fold higher incidence in men than women.<sup>1,3</sup>

Histopathologically, SAFM is a characteristically well-circumscribed but unencapsulated dermal tumor composed of spindle and stellate cells in a loose storiform or fascicular arrangement embedded in a myxoid, myxocollagenous, or collagenous stroma.<sup>4</sup> The tumor often occupies the entire dermis and may extend into the subcutis or occasionally the underlying fascia and bone.<sup>4,5</sup> Mast cells often are prominent, and microvascular accentuation also may be seen. Inflammatory infiltrates and multinucleated giant cells typically are not seen.<sup>6</sup> Although 2 cases

of atypical SAFM have been described,<sup>2</sup> cellular atypia is not a characteristic feature of SAFM.

The immunohistochemical profile of SAFM is characterized by diffuse or focal expression of CD34, focal expression of epithelial membrane antigen (EMA), CD99 expression, and varying numbers of factor XIIIa-positive histiocytes.<sup>2,3</sup> Positive staining for vimentin also is common. Staining typically is negative for S-100, human melanoma black 45, keratin, smooth muscle actin, and desmin.

The standard treatment of SAFM is complete local resection of the tumor, though some patients have been treated with partial excision or biopsy and partial or complete digital amputation.<sup>1</sup> Local recurrence may occur in up to 20% of cases; however, approximately two-thirds of the reported recurrences in the literature occurred after incomplete tumor excision.<sup>1,2</sup> It may be more appropriate to consider these cases as persistent rather than recurrent tumors. Superficial acral fibromyxoma is considered a benign tumor, with no known cases of metastases.<sup>4</sup>

A broad differential diagnosis exists for SAFM and it can be difficult to differentiate it from a wide variety of benign and malignant tumors that may be seen on the nail unit and distal extremities (Table). Myxoid neurofibromas typically present as solitary lesions on the hands and feet. Similar to SAFM, myxoid neurofibromas are unencapsulated dermal tumors composed of spindle-shaped cells in which mast cells often are conspicuous.<sup>2,7</sup> However, tumor cells in myxoid neurofibromas are S-100 positive, and the lesions typically do not show vasculature accentuation.<sup>4,7</sup>

### Differential Diagnosis of Superficial Acral Fibromyxoma

Condition	Clinical/Histopathological Findings	Immunohistochemical Findings
SAFM	Slow-growing solitary nodule on the distal fingers or toes; spindle cells in a fascicular arrangement embedded in a myxoid stroma; prominent mast cells and microvascular accentuation	S-100 <sup>-</sup> , EMA <sup>+</sup> , CD34 <sup>+</sup> , CD99 <sup>+</sup>
Myxoid neurofibroma	Solitary lesion on the hand or foot; unencapsulated dermal tumor of spindle-shaped cells; mast cells may be present, but vascular accentuation typically is absent	S-100 <sup>+</sup>
Sclerosing perineurioma	Benign tumor of the palms or fingers; bland spindle cells arranged in fascicles and whorls in a hyalinized matrix	S-100 <sup>-</sup> , EMA <sup>+</sup> , CD34 <sup>-</sup>
Superficial angiomyxoma	Typically located on the head or neck; spindle-shaped fibroblasts in a myxoid matrix with neutrophils and thin-walled capillaries	S-100 <sup>+</sup> , CD34 <sup>+/-</sup>
Myxoid dermatofibrosarcoma protuberans	Typically presents on the trunk, proximal extremities, or head/neck; acral occurrence is extremely rare; sheets of bland spindle cells; deeply invasive into subcutaneous tissue	S-100 <sup>-</sup> , CD34 <sup>+</sup>
Low-grade myxofibrosarcoma	Soft tissue neoplasm that is common in adults; rarely presents in acral areas; nodular growth pattern with nuclear atypia and perivascular clustering of tumor cells	CD34 <sup>+/-</sup>
Myxoinflammatory fibroblastic sarcoma	Predilection for the extremities, similar to SAFM, but rarely involves the nail bed; remarkable inflammatory infiltrate and characteristic virocyte or Reed-Sternberg cells	S-100 <sup>-</sup> , CD34 <sup>-</sup> , EMA <sup>-</sup>
Acquired digital fibrokeratoma	Benign neoplasm of the fingers and toes; solitary smooth nodule or dome with projecting configuration/horn	CD34 <sup>+</sup> , EMA <sup>-</sup>

Abbreviations: SAFM, superficial acral fibromyxoma; EMA, epithelial membrane antigen.

Sclerosing perineuriomas are benign fibrous tumors of the fingers and palms. Histopathologically, bland spindle cells arranged in fascicles and whorls are observed in a hyalinized collagen matrix.<sup>8</sup> Immunohistochemically, sclerosing perineuriomas are positive for EMA and negative for S-100, but unlike SAFM, these tumors usually are CD34 negative.<sup>8</sup>

Superficial angiomyxomas typically are located on the head and neck but also may be found in other locations such as the trunk. They present as cutaneous papules or polypoid lesions. Histopathologically, superficial angiomyxomas are poorly circumscribed with a lobular pattern. Spindle-shaped fibroblasts exist in a myxoid matrix with neutrophils and thin-walled capillaries. The

fibroblasts are variably positive for CD34 but also are S-100 positive.<sup>1,9</sup>

Myxoid dermatofibrosarcoma protuberans is a rare, locally aggressive, mesenchymal tumor of the skin and subcutis<sup>2</sup> that typically presents on the trunk, proximal extremities, or head and neck; occurrence on the fingers or toes is exceedingly rare.<sup>2,10</sup> Histopathologically, a myxoid stroma contains sheets of bland spindle-shaped cells with minimal to no atypia, sometimes arranged in a storiform pattern. The tumor characteristically invades deeply into the subcutaneous tissues. CD34 is characteristically positive and S-100 is negative.<sup>2,10</sup>

Low-grade myxofibrosarcoma is a soft tissue sarcoma easily confused with other spindle cell tumors. It is one of the most common sarcomas in adults but rarely arises in acral areas.<sup>2</sup> It is characterized by a nodular growth pattern with marked nuclear atypia and perivascular clustering of tumor cells. CD34 staining may be positive in some cases.<sup>11</sup>

Similar to SAFM, myxoinflammatory fibroblastic sarcoma has a predilection for the extremities.<sup>4</sup> However, it typically presents as a subcutaneous mass and has no documented tendency for nail bed involvement. Also unlike SAFM, it has a remarkable inflammatory infiltrate and characteristic virocyte or Reed-Sternberg cells.<sup>12</sup>

Acquired digital fibrokeratomas are benign neoplasms that occur on fingers and toes; the classic clinical presentation is a solitary smooth nodule or dome, often with a characteristic projecting configuration and horn shape.<sup>1</sup> Histopathologically, these tumors are paucicellular with thick, vertically oriented, interwoven collagen bundles; cells may be positive for CD34 but are negative for EMA.<sup>1,13</sup> Related to acquired digital fibrokeratomas are Koenen tumors, which share a similar histology but are distinguished by their clinical characteristics. For example, Koenen tumors tend to be multifocal and are strongly associated with tuberous sclerosis. These tumors also have a tendency to recur.<sup>1</sup>

## Conclusion

Our report of 3 typical cases of SAFM highlights the need to keep this increasingly recognized and

well-defined clinicopathological entity in the differential for slow-growing tumors in acral locations, particularly those in the periungual and subungual regions.

## REFERENCES

1. Fetsch JF, Laskin WB, Miettinen M. Superficial acral fibromyxoma: a clinicopathologic and immunohistochemical analysis of 37 cases of a distinctive soft tissue tumor with a predilection for the fingers and toes. *Hum Pathol.* 2001;32:704-714.
2. Al-Daraji WI, Miettinen M. Superficial acral fibromyxoma: a clinicopathological analysis of 32 tumors including 4 in the heel. *J Cutan Pathol.* 2008;35:1020-1026.
3. Hollmann TJ, Bovée JV, Fletcher CD. Digital fibromyxoma (superficial acral fibromyxoma): a detailed characterization of 124 cases. *Am J Surg Pathol.* 2012;36:789-798.
4. André J, Theunis A, Richert B, et al. Superficial acral fibromyxoma: clinical and pathological features. *Am J Dermatopathol.* 2004;26:472-474.
5. Kazakov DV, Mentzel T, Burg G, et al. Superficial acral fibromyxoma: report of two cases. *Dermatology.* 2002;205:285-288.
6. Meyerle JH, Keller RA, Krivda SJ. Superficial acral fibromyxoma of the index finger. *J Am Acad Dermatol.* 2004;50:134-136.
7. Graadt van Roggen JF, Hogendoorn PC, Fletcher CD. Myxoid tumours of soft tissue. *Histopathology.* 1999;35:291-312.
8. Fetsch JF, Miettinen M. Sclerosing perineurioma: a clinicopathologic study of 19 cases of a distinctive soft tissue lesion with a predilection for the fingers and palms of young adults. *Am J Surg Pathol.* 1997;21:1433-1442.
9. Calonje E, Guerin D, McCormick D, et al. Superficial angiomyxoma: clinicopathologic analysis of a series of distinctive but poorly recognized cutaneous tumors with tendency for recurrence. *Am J Surg Pathol.* 1999;23:910-917.
10. Taylor HB, Helwig EB. Dermatofibrosarcoma protuberans. a study of 115 cases. *Cancer.* 1962;15:717-725.
11. Wada T, Hasegawa T, Nagoya S, et al. Myxofibrosarcoma with an infiltrative growth pattern: a case report. *Jpn J Clin Oncol.* 2000;30:458-462.
12. Meis-Kindblom JM, Kindblom LG. Acral myxoinflammatory fibroblastic sarcoma: a low-grade tumor of the hands and feet. *Am J Surg Pathol.* 1998;22:911-924.
13. Bart RS, Andrade R, Kopf AW, et al. Acquired digital fibrokeratomas. *Arch Dermatol.* 1968;97:120-129.