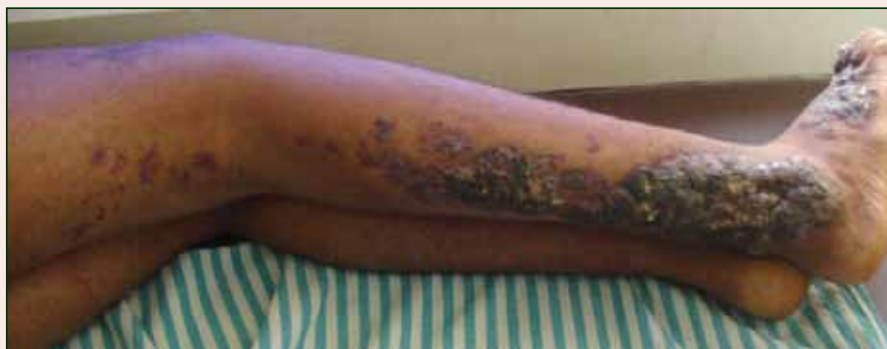

# Bluish Red Verrucous Lesions on the Leg

What's the diagnosis?



An 18-year-old man presented with a history of multiple bluish verrucous lesions over the right leg. A small nodule on the lateral aspect of the right ankle was present at birth; it increased in size and number and gradually extended to the right buttock. He had recurrent bleeding and infection over the lesions. No other remarkable comorbidities were noted. Dermatologic examination revealed multiple well-circumscribed, bluish red, verrucous lesions distributed linearly along the lateral aspect of the leg. The surface of the lesions was verruciform and showed crusting at places. The second and third toes on the right foot were involved. On the buttock, multiple well-defined, bluish red plaques were present. Both limbs were of equal length.

Kikkeri Narayanasetty Naveen, MD; Varadraj V. Pai, MD; Sharatchandra B. Athanikar, MD; Vidhisha S. Athanikar, MD; Vijetha Rai, MD

From the Sri Dharmasthala Manjunatheshwara College of Medical Sciences and Hospital, Sattur, Dharwad, India. Drs. Naveen, Pai, SB Athanikar, and Rai are from the Department of Dermatology. Dr. VS Athanikar is from the Department of Pathology. The authors report no conflict of interest.

Correspondence: Kikkeri Narayanasetty Naveen, MD, Department of Dermatology, No 10, Skin OPD, Sri Dharmasthala Manjunatheshwara College of Medical Sciences and Hospital (SDMCMS&H), Sattur, Dharwad 580009 (naveenkn80@yahoo.com).

## The Diagnosis: Linear Verrucous Hemangioma

Verrucous hemangioma is a rare congenital vascular malformation of the cutaneous and subcutaneous tissues. Although almost invariably present at birth, it may appear later in childhood or even in adulthood. Lesions commonly are found on the legs and may be linear, multiple, and disseminated or sometimes confined to the digits. In the early phase of evolution, the lesions are nonkeratotic, soft, blue-red plaques, but they gradually become increasingly hyperkeratotic.<sup>1</sup> Linear verrucous hemangioma is even more rare with few published reports.

In 1937, Halter<sup>2</sup> first used the term *verrucous hemangioma* to describe a 16-year-old adolescent boy who presented with a linear purpuric cluster of plaques extending from the right buttock to the toes. Imperial and Helwig<sup>3</sup> later described it as a distinct entity. Since then, similar lesions have been described using a variety of names such as angiokeratoma circumscriptum neviforme, angiokeratoma circumscriptum, angiokeratoma corporis neviforme, keratotic hemangioma, nevus vascularis unius lateralis, and nevus keratoangiomasus.<sup>3</sup> Therefore, the exact incidence is difficult to determine.

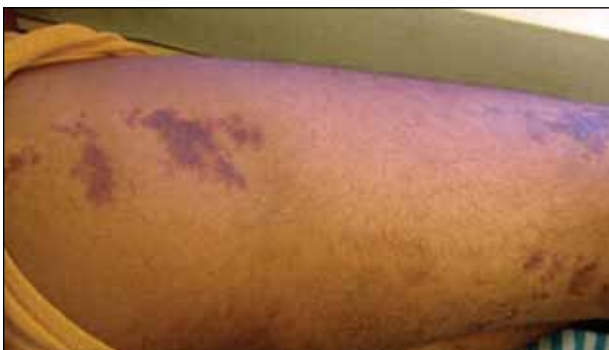Lesions generally are noted at birth or in early childhood and are often located on the lower extremities. The early lesions are bluish red in color. Secondary infection is a frequent complication, resulting in reactive papillomatosis and hyperkeratosis; thus, the older lesions acquire a verrucous or warty surface.<sup>3</sup>

Clinically, they may resemble angiokeratoma, lymphangioma circumscriptum, verrucous epidermal nevus, verrucous cancer, or even malignant melanoma. Lesions initially resemble port-wine stains and later may become soft, bluish red vascular swellings that tend to grow in size and become verrucous.<sup>1</sup>

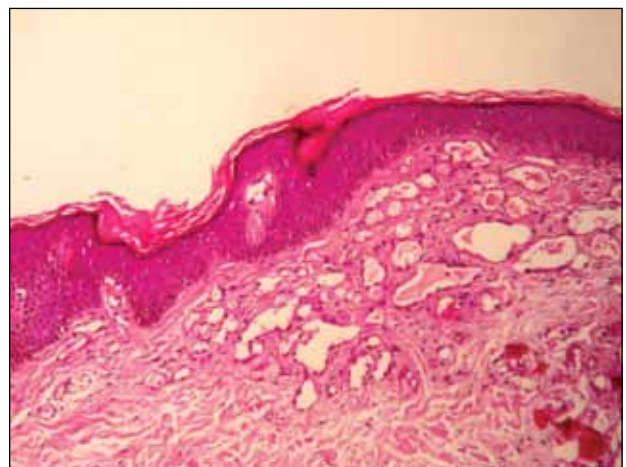
The histologic appearance closely resembles angiokeratoma, as both lesions show vascular spaces beneath a papillomatous and hyperkeratotic epidermis.<sup>4</sup> However, in contrast to angiokeratoma, the vascular spaces in verrucous hemangioma also involve the lower dermis and subcutaneous tissues.

Although cases of linear verrucous hemangioma have been reported, its distribution along the lines of Blaschko is rare.<sup>5,6</sup> It has been proposed that these lesions may actually be following dermatomal patterns or that the linear arrangement represents genetic mosaicism.<sup>5</sup> In our case, the lesion started as a small plaque in childhood and gradually spread linearly to the buttock (Figure 1). A biopsy was taken from the lesion on the right buttock, which showed numerous dilated capillaries in the dermis (Figure 2).

Verrucous hemangiomas are best treated by excision. Larger lesions will need grafting. There is a tendency for recurrence to occur unless excision is complete.<sup>1</sup> Yang and Ohara<sup>7</sup> reported 14 patients with small localized lesions that were cured by 1 session of surgery without recurrence; 9 patients with wider and more extensive lesions required combination therapy in several stages for optimal results.



**Figure 1.** Lesions on the right leg extending to the buttock.



**Figure 2.** Histopathologic examination showed numerous dilated blood vessels (H&E, original magnification  $\times 10$ ).

## REFERENCES

1. Atherton DJ, Moss C. Naevi and other developmental defects. In: Burns T, Breathnach S, Cox N, et al, eds. *Rook's Textbook of Dermatology*. 7th ed. London, England: Blackwell Scientific Publications; 2004:15-60.
2. Halter K. Haemangioma verrucosum mit Osteoatrophie. *Dermatol Z*. 1937;75:271-279.
3. Imperial R, Helwig EB. Verrucous hemangioma: a clinicopathological study of 21 cases. *Arch Dermatol*. 1967;96:247-253.
4. Calduch L, Ortega C, Navarro V, et al. Verrucous hemangioma: Report of two cases and review of the literature. *Pediatr Dermatol*. 2000;17:213-217.
5. Wentscher U, Happle R. Linear verrucous hemangioma. *J Am Acad Dermatol*. 2000;42:516-518.
6. Jain VK, Aggarwal K, Jain S. Linear verrucous hemangioma on the leg. *Indian J Dermatol Venereol Leprol*. 2008;74:656-658.
7. Yang CH, Ohara K. Successful surgical treatment of verrucous hemangioma: a combined approach. *Dermatol Surg*. 2002;28:913-919.