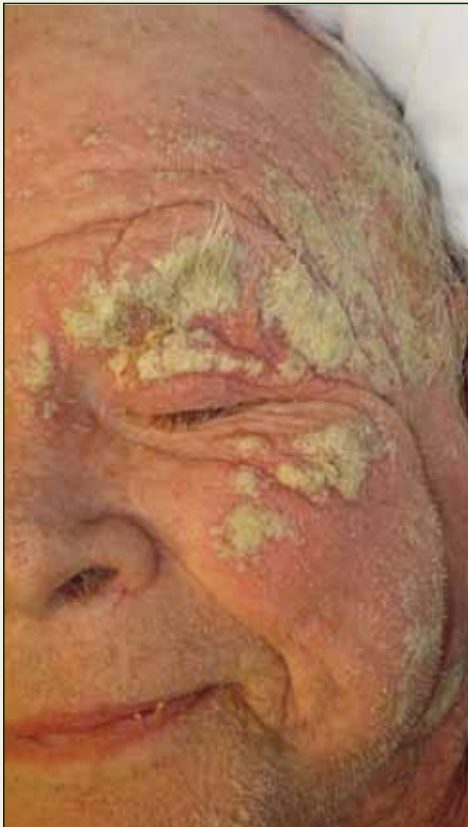

Diffuse Crusting of the Skin

What's the diagnosis?



An 82-year-old white man who resided in the northeastern United States was admitted to the hospital for weakness. He was evaluated for diffuse crusting of the skin including the face. The patient reported a history of minimally itchy, generalized crusts of 10 years' duration. He lived alone with one cat. His medications included fluticasone furoate, terazosin, and levothyroxine sodium. Human immunodeficiency virus screening was negative. A scraping was taken from one of the thick crusts within an interdigital web space.

Nina C. Botto, MD; Erin H. Penn, MD; Bridget M. Grant, MD; Laura Kogelman, MD; Alice B. Gottlieb, MD, PhD; Pamela L. Scheinman, MD

Drs. Botto, Grant, and Gottlieb are from the Department of Dermatology, Tufts Medical Center, Boston, Massachusetts. Drs. Penn and Scheinman are from Brigham and Women's Hospital, Boston, Massachusetts. Dr. Kogelman is from the Department of Geographic Medicine and Infectious Disease, Tufts Medical Center.

The authors report no conflict of interest.

Correspondence: Erin H. Penn, MD, Department of Medicine at Brigham and Women's Hospital, 45 Francis St, Boston, MA 02115 (epenn@partners.org).

The Diagnosis: Crusted Scabies

Approximately 1 year prior to presentation the patient completed a course of therapy comprised of repeat doses of ivermectin and permethrin for crusted scabies. He stated that the crusts had recurred shortly after treatment (Figure 1). The initial differential diagnosis included crusted scabies, pityriasis rubra pilaris, and psoriasis. Scraping from the interdigital web space (Figure 2) revealed multiple scabies mites, scabella, and ova (Figure 3). The patient was diagnosed with crusted scabies. Laboratory test results revealed a normal white blood cell count of $7300/\mu\text{L}$, with an elevated eosinophil count of $1900/\mu\text{L}$ (reference range, $<500/\mu\text{L}$). Human T-lymphotropic virus 1 (HTLV-1) was found to be positive. Serum protein electrophoresis showed a moderate polyclonal increase in gamma globulins. Treatment was promptly initiated with permethrin cream 5% applied to the whole body for a total of 2 treatments that were administered 7 days apart. Ivermectin also was started at $200 \mu\text{g}/\text{kg}$ and was given on days 1, 7, 14, and 29. Salicylic acid cream 25% was applied daily to help hasten resolution of the crusts.

Human T-lymphotropic virus 1 is endemic to Japan, Central and South America, the Middle East, and regions of Africa and the Caribbean.¹ Multiple cases of HTLV-1 associated with crusted scabies have been reported in endemic areas.²⁻⁶ In the present case, we encountered a patient with crusted scabies and HTLV-1 in a nonendemic area.

Cases of HTLV-1 and crusted scabies have been reported in Brazil, Peru, and Central Australia.^{3,4,7} A retrospective study in Brazil showed a notable association between HTLV-1 infection and crusted scabies; of 23 patients with crusted scabies, 21 were HTLV-1 positive.³ In another small study from Peru, 23 patients with crusted scabies were tested for HTLV-1 and 16 (70%) were seropositive.⁴ Neither study had a control group for comparison; however, interestingly, the estimated seroprevalence in the general population (based on blood donors) is only 0.04% to 1% and 1.2% to 1.7% in Brazil and Peru, respectively, thus reinforcing the association between HTLV-1 and crusted scabies.¹ Crusted scabies and HTLV-1 seropositivity acting as a predictor for adult T-cell leukemia/lymphoma (ATL) has been reported⁸ but not consistently.³ Our patient had abnormal serum protein electrophoresis findings. Although the results were not diagnostic of ATL, patients with HTLV-1 are at increased risk for ATL and the presence of this virus is important to document when

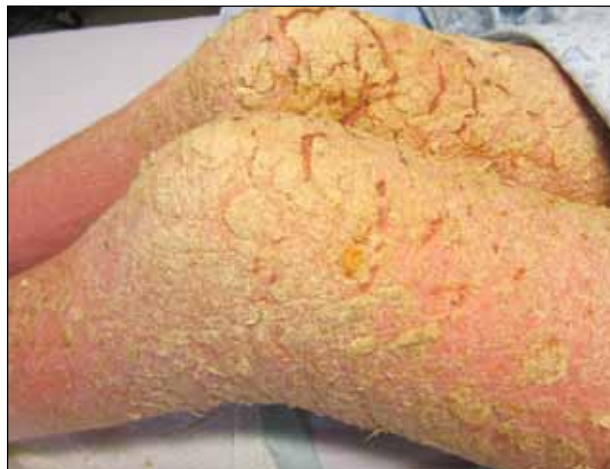

Figure 1. Generalized crusts and hyperkeratotic plaques on both legs.

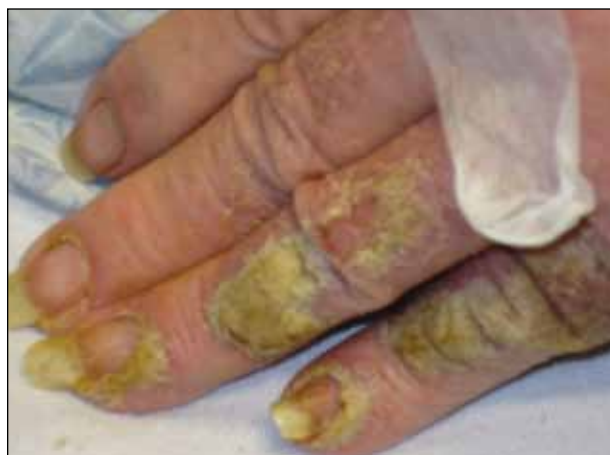

Figure 2. Crusts on the dorsal aspect and interdigital web space of the left hand.

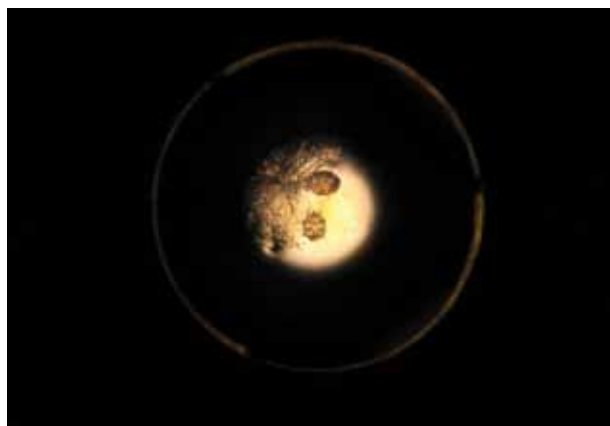


Figure 3. Microscopic examination of scrapings from interdigital crusts showing mites, scabella, and ova.

there is a high index of suspicion for ATL, as with crusted scabies.

Our patient resided in the northeastern United States and there was no evidence in support of underlying immunosuppression. This case of crusted scabies is unique because the patient was HTLV-1 positive without other underlying immunocompromise and he resided in a region where HTLV-1 is nonendemic. In light of these findings, the present case serves as a reminder to check for HTLV-1 infection in those patients with severe or crusted scabies and without an identifiable reason for immunosuppression, even if the patient resides in an area that is nonendemic for HTLV-1.

REFERENCES

1. Gessain A, Cassar O. Epidemiological aspects and world distribution of HTLV-1 infection. *Front Microbiol.* 2012;3:388.
2. Nobre V, Guedes AC, Martins ML, et al. Dermatological findings in 3 generations of a family with a high prevalence of human T cell lymphotropic virus type 1 infection in Brazil. *Clin Infect Dis.* 2006;43:1257-1263.
3. Brites C, Weyll M, Pedroso C, et al. Severe and Norwegian scabies are strongly associated with retroviral (HIV-1/HTLV-1) infection in Bahia, Brazil. *AIDS.* 2002;16:1292-1293.
4. Blas M, Bravo F, Castillo W, et al. Norwegian scabies in Peru: the impact of human T cell lymphotropic virus type I infection. *Am J Trop Med Hyg.* 2005;72:855-857.
5. Bergman JN, Dodd WA, Trotter MJ, et al. Crusted scabies in association with human T-cell lymphotropic virus 1. *J Cutan Med Surg.* 1999;3:148-152.
6. Daisley H, Charles W, Suite M. Crusted (Norwegian) scabies as a pre-diagnostic indicator for HTLV-1 infection. *Trans R Soc Trop Med Hyg.* 1993;87:295.
7. Mollison LC. HTLV-I and clinical disease correlates in central Australian aborigines. *Med J Aust.* 1994;160:238.
8. del Giudice P, Sainte Marie D, Gérard Y, et al. Is crusted (Norwegian) scabies a marker of adult T cell leukemia/lymphoma in human T lymphotropic virus type I-seropositive patients? *J Infect Dis.* 1997;176:1090-1092.