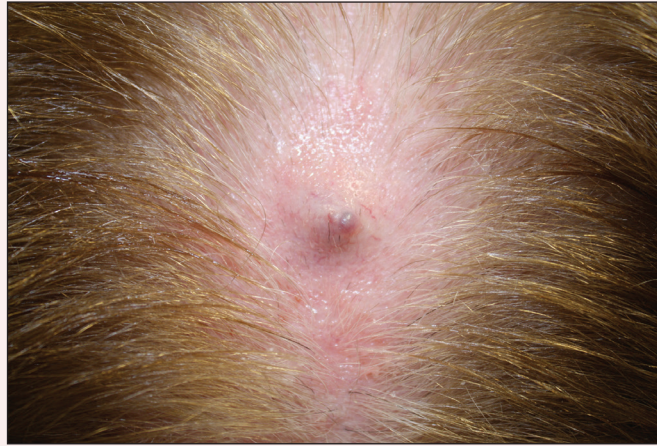

Firm Gray Nodule on the Scalp

Patrick M. Benson, MD; Gretchen W. Frieling, MD; Joseph C. Pierson, MD; Christine H. Weinberger, MD



A 78-year-old woman presented with a firm lump on the posterior vertex of the scalp of more than 1 year's duration. She denied pain, bleeding, discharge, or history of malignancies or skin conditions. The lesion occasionally became irritated when combing the hair. Physical examination revealed a 1.5-cm, firm, gray, mobile nodule with overlying telangiectasia and a superimposed purple papule. An excisional biopsy demonstrated a predominantly dermal neoplasm composed of cribriform islands of epithelial cells within pools of mucin. In the deep dermis and subcutaneous tissue there was a cystic component with more prominent apocrine differentiation and papillary architecture. Immunohistochemical stains were positive for p63 and cytokeratin 7 and negative for cytokeratin 20.

What's the diagnosis?

- a. basal cell carcinoma
- b. epidermoid cyst
- c. gastrointestinal tract metastasis
- d. Merkel cell carcinoma
- e. primary cutaneous mucinous carcinoma

From the University of Vermont College of Medicine, Burlington.

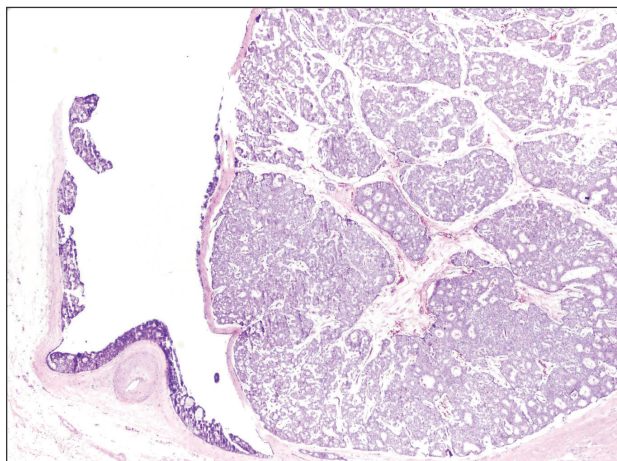
The authors report no conflict of interest.

Correspondence: Joseph C. Pierson, MD, Division of Dermatology, University of Vermont College of Medicine, 111 Colchester Ave, Burlington, VT 05401 (joseph.pierson@uvm.edu).

The Diagnosis: Primary Cutaneous Mucinous Carcinoma

Primary cutaneous mucinous carcinoma is a rare tumor of the sweat glands that was first reported in 1952 by Lennox et al.¹ These tumors are slow growing and have a predilection for the head and neck, with the eyelid being the most commonly reported location.² In general, they present as erythematous asymptomatic nodules measuring less than 7 cm in diameter.²⁻⁴ Primary cutaneous mucinous carcinoma tends to have a good prognosis with complete resection, but cases of metastasis and recurrence have been reported.² Although there is no standard of care, treatment typically consists of surgical management, as the tumors are nonresponsive to chemotherapy or radiation.⁴ Kamalpour et al² compared outcomes for Mohs micrographic surgery versus standard excision, the former showing a lower percentage of poor outcomes. Of note, there were fewer cases treated with Mohs surgery in this study; only more recently reported cases have been treated with Mohs surgery.

Histologically, primary cutaneous mucinous carcinoma is composed of cords, tubules, and lobules of epithelial cells floating in large pools of basophilic mucin, separated by thin fibrovascular septa.⁵ It can be difficult to distinguish a primary tumor from a mucinous carcinoma metastasis with histology alone, especially on the breasts and in the gastrointestinal tract. Immunohistochemistry can be helpful in determining the origin of the tumor. A homologue of p53, p63 expressed in basal and myoepithelial cells of the skin can aid in the confirmation of a primary tumor



Cystic and papillary components are present in the tumor sample (H&E, original magnification $\times 20$).

when present.^{6,7} Negative staining for cytokeratin 20 and positive staining for cytokeratin 7 also are helpful in distinguishing a primary cutaneous mucinous carcinoma from a gastrointestinal tract metastasis.^{4,8}

In our patient, no other symptoms were present that raised concern for an internal malignancy. Findings that supported a primary versus metastatic tumor included the clinicopathologic findings (Figure) as well as positive p63, cytokeratin 7, and negative cytokeratin 20 staining. The initial standard excision had tumor cells within 1 mm of the specimen margin; thus, a subsequent wider reexcision was performed. Reexcision was negative for tumor cells. Close follow-up with a primary care physician was recommended, with emphasis on colon and breast cancer screening. A follow-up mammogram was negative for breast cancer.

REFERENCES

1. Lennox B, Pearse AG, Richards HG. Mucin-secreting tumours of the skin: with special reference to the so-called mixed-salivary tumour of the skin and its relation to hidradenoma. *J Pathol Bacteriol.* 1952;64:865-880.
2. Kamalpour L, Brindise RT, Nodzinski M, et al. Primary cutaneous mucinous carcinoma a systematic review and meta-analysis of outcomes after surgery. *JAMA Dermatol.* 2014;150:380-384.
3. Papalas JA, Proia AD. Primary mucinous carcinoma of the eyelid: a clinicopathological and immunohistochemical study of 4 cases and an update on recurrence rates. *Arch Ophthalmol.* 2010;128:1160-1165.
4. Breiting L, Christensen L, Dahlstrom K, et al. Primary mucinous carcinoma of the skin: a population-based study. *Int J Dermatol.* 2008;47:242-245.
5. Walsh SN, Santa Cruz DJ. Adnexal carcinomas of the skin. In: Rigel DS, Robinson JK, Ross M, et al, eds. *Cancer of the Skin.* 2nd ed. Beijing, China: Elsevier Saunders; 2011:140-149.
6. Jo VY, Fletcher CD. p63 Immunohistochemical staining is limited in soft tissue tumors. *Am J Clin Pathol.* 2011; 136:762-766.
7. Ivan D, Nash JW, Prieto VG, et al. Use of p63 expression in distinguishing primary and metastatic cutaneous adnexal neoplasms from metastatic adenocarcinoma to skin. *J Cutan Pathol.* 2006;34:478-489.
8. Kazakov DV, Suster S, LeBoit PE, et al. Mucinous carcinoma of the skin, primary, and secondary: a clinicopathologic study of 63 cases with emphasis on the morphologic spectrum of primary cutaneous forms: homologies with mucinous lesions in the breast. *Am J Surg Pathol.* 2005;29:764-782.