

# 1,25-dihydroxyvitamin D hypercalcemia and imatinib hepatotoxicity in a patient with GIST

Drew Oostra, MD, and Keith Skubitz, MD

Division of Hematology, Oncology and Transplantation, Department of Medicine, University of Minnesota, Minneapolis, Minnesota

**H**ypercalcemia is commonly encountered in carcinomas, most commonly in breast and lung cancers, but is also encountered in some hematologic malignancies such as multiple myeloma, leukemia, and lymphoma. Hypercalcemia occurs in 20%-30% of carcinomas during their course and usually portends a poor prognosis.<sup>1</sup> It occurs in malignancy predominantly due to 2 mechanisms. The first mechanism is parathyroid hormone-related protein (PTHrP) and osteolytic bone metastasis. Hypercalcemia mediated by PTHrP release by the tumor is commonly called humoral hypercalcemia. PTHrP leads to increased bone resorption and increased renal calcium reabsorption, which leads to hypercalcemia. It is usually seen in squamous cell carcinomas (lung, head and neck), renal cell carcinoma, and bladder carcinoma.<sup>2</sup> Humoral hypercalcemia accounts for about 80% of all cases of hypercalcemia of malignancy.<sup>2</sup> The second main mechanism of hypercalcemia of malignancy is a result of osteolytic bone lesions. In this situation, tumors metastasize to bone and express cytokines, leading to osteoclast activation through the RANKL-RANK interaction, which results in bone resorption and release of calcium into circulation.<sup>3</sup> This type of hypercalcemia is usually seen in breast cancer and multiple myeloma. Osteolytic bone lesions account for about 15%-20% of all cases of hypercalcemia of malignancy.<sup>2</sup>

Although these mechanisms account for most cases of hypercalcemia, other mechanisms exist. Rarely, tumors can have ectopic PTH production. Increased production of 1,25-dihydroxyvitamin D is another cause of hypercalcemia of malignancy that is not often encountered or discussed. Increased production of 1,25-dihydroxyvitamin D accounts for many of the cases of hypercalcemia in Hodgkin lymphoma and some of the cases in non-Hodgkin

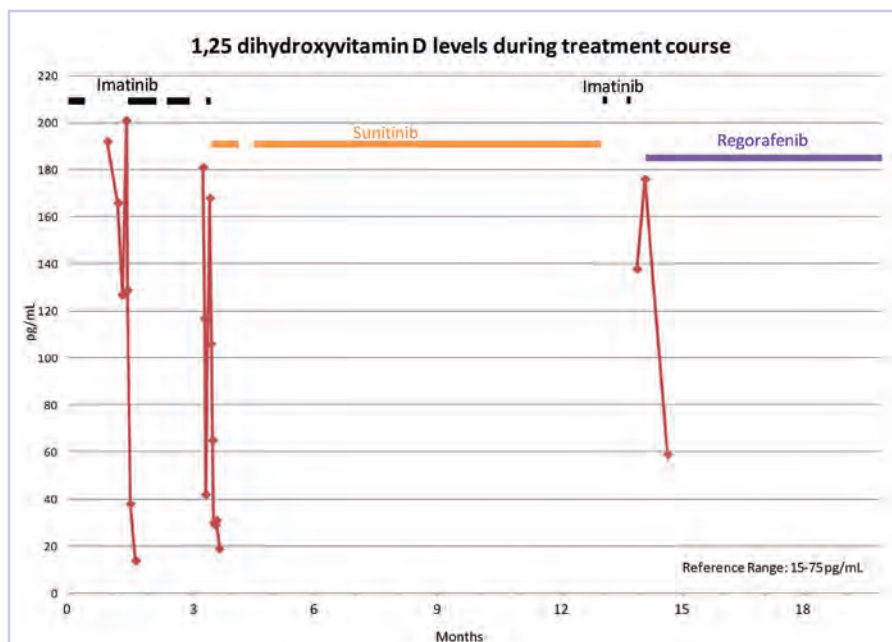
lymphoma. It has rarely been reported in other cancers,<sup>4-8</sup> including gastrointestinal stromal tumors (GISTs).<sup>9,10</sup>

GISTs are the most common mesenchymal tumor of the gut, and treatment involves surgical resection if possible. KIT is frequently mutated in GIST, and GIST tumors are treated with the tyrosine kinase inhibitor (TKI), imatinib. Imatinib inhibits KIT as well as ABL, platelet-derived growth factor (PDGFR), and other Src-family kinases. The site of the mutation in KIT is a determining factor of the efficacy of imatinib as an anti-tumor agent.<sup>11-13</sup> Although the side effects of imatinib are usually minimal, in some patients they can include edema, fatigue, skin rash, diarrhea, myelosuppression, and elevated liver function tests, in addition to other adverse effects.<sup>11,14</sup> Rarely, imatinib can cause severe liver injury and death.<sup>15</sup> Here we report a case of GIST presenting with 1,25-dihydroxyvitamin D-mediated hypercalcemia in which treatment with imatinib resulted in drug-induced liver injury.

## Case presentation and summary

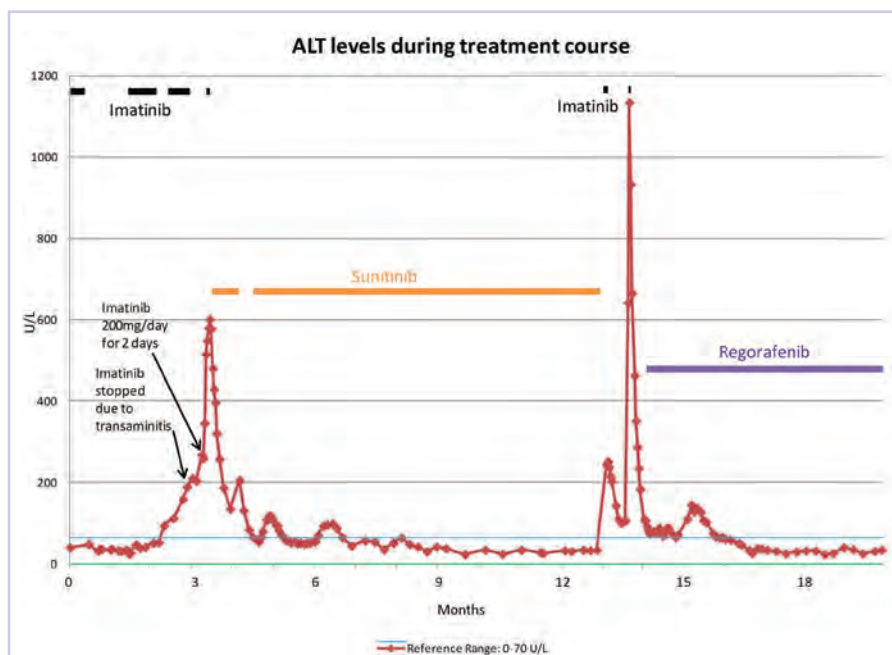
A 45-year-old man with a history of hypertension, hyperlipidemia, and borderline intellectual disability developed symptoms of nausea, malaise, abdominal pain, and weight loss 15-20 lb over 2-3 weeks. A computed-tomography (CT) scan showed a mesenteric mass and peritoneal studding consistent with peritoneal carcinomatosis. His labs showed acute kidney injury with a creatinine of 4.5 mg/dL (reference range, 0.66-1.25 mg/dL) and hypercalcemia with a corrected calcium of 14.5 mg/dL (reference range, 8.5-10.1 mg/dL). He was treated aggressively for hypercalcemia with intravenous fluids, but ultimately required calcitonin and a bisphosphonate. His PTH level was normal, and PTHrP level was not detectable.

Accepted for publication November 12, 2015. Correspondence: Keith Skubitz, MD; skubi001@umn.edu. Disclosures: The authors report no disclosures or conflicts of interest. JCSO 2016;14(8):363-366. ©2016 Frontline Medical Communications. doi: 10.12788/jcso.0210.



**FIGURE 1** 1,25-dihydroxyvitamin D levels for a GIST patient with 1,25-dihydroxyvitamin D-mediated hypercalcemia of malignancy.

GIST, gastrointestinal stromal tumors



**FIGURE 2** ALT levels for a GIST patient with 1,25-dihydroxyvitamin D-mediated hypercalcemia of malignancy.

ALT, alanine aminotransferase; GIST, gastrointestinal stromal tumors

A biopsy showed a mixed type GIST that was CD117 positive. He was started on imatinib 200 mg/day. His calcium level improved but did not normalize, and he transferred his care to another facility. A KIT exon 11 deletion (YIDPTQL 570-576) was found. Creatinine fell to 1.62

mg/dL, and his imatinib dose was increased to 400 mg/day. However, he developed increasing ascites. Imatinib was withheld, and the ascites improved, but hypercalcemia returned and required treatment with calcitonin and a bisphosphonate. The patient's 1,25-dihydroxyvitamin D level was elevated at 192 pg/mL at that time and peaked at 201 pg/mL (reference range, 15-75 pg/mL; Figure 1). PTHrP was again undetectable at <2.8 pmol/L (reference range, 0.0-4.0 pmol/L).

The patient's hypercalcemia proved difficult to control despite bisphosphonates, intravenous fluids, calcitonin, and steroids. After the patient had been off imatinib for 1 month, a positron-emission tomography (PET) scan showed marked fluorine-18-deoxyglucose (FDG)-avid PET activity (Figure 4A). Imatinib was begun at 400 mg/day, and the hypercalcemia and symptoms quickly improved. However, he developed severe transaminitis with an alanine aminotransferase (ALT) level of about 200 U/L (reference range, 0-70 U/L). Imatinib was again withheld, and the patient's ALT level stabilized. A re-trial of imatinib at 200 mg/day for 2 days resulted in an immediate increase in ALT to more than 600 U/L (Figure 2), and imatinib was stopped.

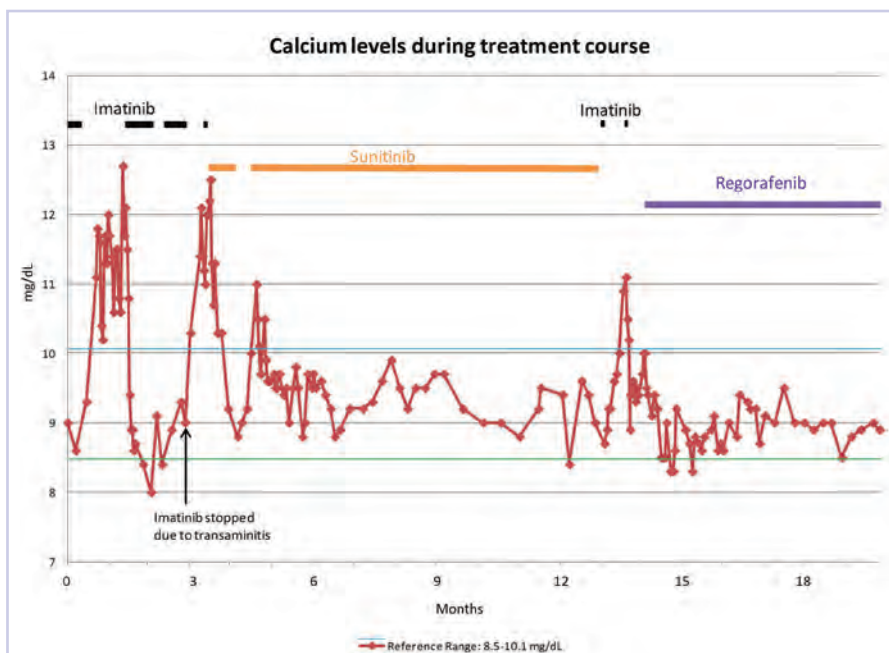
A liver biopsy showed portal inflammation and lobular inflammation consistent with drug-induced liver injury. The patient was started on prednisone at 20 mg/day. His ALT levels decreased and eventually normalized (Figure 2), and the steroids were tapered off. At the same time, he again developed hypercalcemia (Figure 3) and was found to have disease progression. Sunitinib was begun (50 mg/day for days 1-28 of a 6-week cycle) with normalization of the calcium (Figure 3). Skin toxicity required a modification of the sunitinib dose and schedule. He remained on this modified dose for 3 months, and a PET-CT scan showed marked improvement in peritoneal carcinomatosis (Figure 4B).

Four months after the PET scan (while remaining on sunitinib), the patient developed an uncomfortable right inguinal mass. A repeat PET scan showed progressive disease and a right inguinal hernia with a reducible tumor extending into the hernia. The surgery team decided that there was no good surgical option for his hernia. Sunitinib was stopped, and the

patient was started on a trial of imatinib at 200 mg/day, but rapidly developed transaminitis (ALT, about 250 U/L) after 4 doses of 200 mg/day (Figure 2). Imatinib was stopped, and his ALT level improved to about 100 U/L. We planned to use regorafenib, however, due to a delay in obtaining the drug, a trial of imatinib with steroids was attempted. The patient received imatinib 200 mg/day with prednisone 20 mg/day for 2 days, but developed a rapid rise in his ALT level, to >1,100 U/L (Figure 2). Imatinib was stopped, and prednisone was increased to 60 mg/day with normalization of ALT (Figure 2). Regorafenib (160 mg once daily for the first 21 days of each 28-day cycle) was begun, and a CT scan 1 month later showed an improved response. Repeat CT scans showed a mixed response to regorafenib.

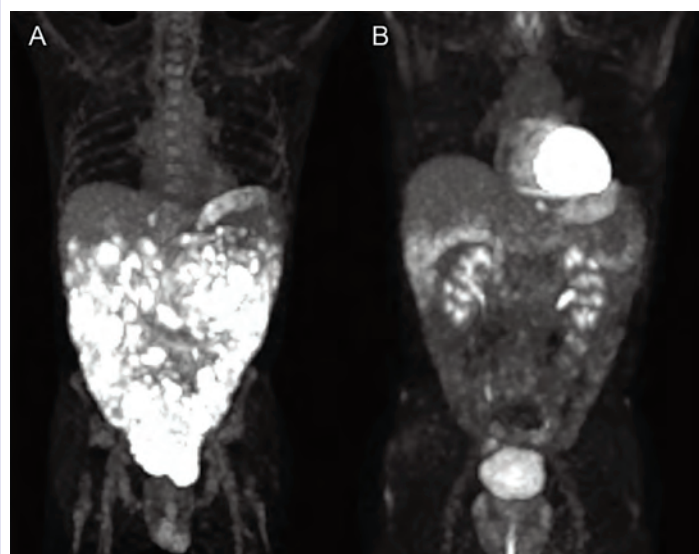
## Discussion

Hypercalcemia of malignancy is commonly encountered and occurs predominantly due to PTHrP release by the tumor or osteolytic bone lesions. Although these 2 mechanisms account for most hypercalcemia of malignancy cases, increased production of 1,25-dihydroxyvitamin D is another unusual cause of hypercalcemia of malignancy. Our patient's hypercalcemia was thought to be 1,25-dihydroxyvitamin D-mediated because of his high 1,25-hydroxyvitamin D level in the setting of a normal PTHrP level and lack of osteolytic bone lesions. 1,25-dihydroxyvitamin D is the active form of vitamin D. Cholecalciferol (vitamin D3) is obtained from diet and sunlight, and carried to the liver where it is converted to 25-hydroxyvitamin D (calcidiol). That is then converted to 1,25-dihydroxyvitamin D in the kidney via 1-alpha-hydroxylase, which is regulated by PTH. Normally, hypercalcemia should result in a decreased release of PTH and therefore decreased 1-alpha-hydroxylase, which would lead to decreased conversion of 25-hydroxyvitamin D to 1,25-dihydroxyvitamin D. In contrast, in some malignancies there is direct tumor production (extra-renal production) of 1-alpha-hydroxylase or 1,25-dihydroxyvitamin D. This results in increased levels of 1,25-dihydroxyvitamin D (despite a low PTH) and ultimately results in hypercalcemia.<sup>2</sup> This is thought to be accomplished directly by the malignancy through malignant cells and/or nearby macrophages.<sup>16</sup> The increased level of 1,25-dihydroxyvitamin D leads to hypercalcemia by causing increased intestinal calcium absorption and increased bone resorption. Increased production of 1,25-dihydroxyvitamin D accounts for many of the cases of hypercalcemia in Hodgkin lymphoma and some of the cases in non-Hodgkin lymphoma.<sup>2,17</sup>



**FIGURE 3** Calcium levels for a GIST patient with 1,25-dihydroxyvitamin D-mediated hypercalcemia of malignancy.

GIST, gastrointestinal stromal tumors



**FIGURE 4** Positron-emission tomography scan showing **A**, fluorine-18-deoxyglucose (FDG) activity with an unusual tumor pattern of diffuse peritoneal disease after the patient had been off imatinib for 1 month (maximal intensity projection image, coronal view), and **B**, after 3 months of sunitinib therapy (maximal intensity projection image, coronal view).

Hypercalcemia has rarely been reported in other cancers, including ovarian dysgerminomas,<sup>4,5</sup> lymphomatoid granulomatosis or angiocentric lymphoma,<sup>8</sup> mesothelioma,<sup>6</sup> and possibly colon cancer.<sup>7</sup> GISTs have very rarely been associated with 1,25-dihydroxyvitamin D-mediated hypercalcemia. We found only 2 reported cases in the lit-

erature.<sup>9,10</sup> Our case highlights that GIST tumors can present with hypercalcemia mediated by 1,25-dihydroxyvitamin D. In our case, the 1,25-dihydroxyvitamin D level was reduced from a peak of 201 pg/mL to a low of 19 pg/mL with imatinib, though levels later progressed. Our case suggests that calcium levels and 1,25-dihydroxyvitamin D levels were correlated with disease response and may aide in determining when disease is progressing. It is interesting to note that hypercalcemia has been reported in other diseases, namely granulomatous diseases, and that 1,25-dihydroxyvitamin D-mediated hypercalcemia responds to glucocorticoid therapy.<sup>18</sup>

This case also shows that TKIs can result in drug-induced liver injury that can respond to corticosteroids. Imatinib undergoes hepatic metabolism and is known to cause elevated liver function tests. In contrast, in trials of imatinib for GIST, rates of transaminitis were much lower. In a recent study that compared imatinib dosing in GIST, at 400 mg of imatinib, 4% of participants developed grade 3 hepatotoxicity and no grade 4 hepatotoxicity was observed.<sup>15</sup> For patients who develop transaminitis and/or hyperbilirubinemia, imatinib often has to be withheld until those conditions improve. The US prescribing information defines hepatotoxicity as elevations of total bilirubin >3 times the institutional upper limit of normal (IULN) or transaminases >5 times the IULN.

For patients who develop hepatotoxicity during therapy, the US prescribing information recommends withholding treatment until bilirubin is <1.5 times the IULN and transaminases <2.5 times the IULN, and then resuming treatment with a reduced dose, although there are scant data to support these recommendations. In the absence of transaminitis, a small elevation of bilirubin may not be a reason to alter treatment, depending on the clinical situation. In addition, the high incidence of Gilbert syndrome must be considered. Sometimes drug-induced injury can be severe enough to require permanent discontinuation of the drug and/or liver biopsy. Severe transaminitis, as occurred in our case, is uncommon. Steroids have been shown in some small studies to reverse severe imatinib-induced hepatotoxicity.<sup>19</sup> Our patient's transaminases returned to normal with imatinib withdrawal and prednisone treatment on 2 occasions, which highlights the importance of monitoring liver function tests in patients on imatinib.

In conclusion, our case draws attention to 2 key points: GISTs can present with hypercalcemia that is thought to be mediated by 1,25-dihydroxyvitamin D, and imatinib can result in severe liver injury that may respond to steroids.

## Acknowledgment

The authors thank Michael Franklin, MS, for editorial assistance.

## References

1. Stewart AF. Clinical practice. Hypercalcemia associated with cancer. *N Engl J Med*. 2005;352:373-379.
2. Horwitz MJ, Hodak SP, Stewart AF. Non-parathyroid hypercalcemia. In: Rosen CJ, Bouillon R, Compston JE, et al, eds. *Primer on the metabolic bone diseases and disorders of mineral metabolism*. 8th ed. Ames, Iowa: Wiley-Blackwell; 2013.
3. Oostra DR, Lustberg MB, Reinbolt RE, Pan X, Wesolowski R, Shapiro CL. Association of osteoprotegerin and bone loss after adjuvant chemotherapy in early-stage breast cancer. *Mol Cell Endocrinol*. 2015;402:51-56.
4. Evans KN, Taylor H, Zehnder D, et al. Increased expression of 25-hydroxyvitamin D-1 $\alpha$ -hydroxylase in dysgerminomas: a novel form of humoral hypercalcemia of malignancy. *Am J Pathol*. 2004;165:807-813.
5. Hibi M, Hara F, Tomishige H, et al. 1,25-dihydroxyvitamin D-mediated hypercalcemia in ovarian dysgerminoma. *Pediatr Hematol Oncol*. 2008;25:73-78.
6. Lee JM, Pou K, Sadow PM, et al. Vitamin D-mediated hypercalcemia and Cushing syndrome as manifestations of malignant pleural mesothelioma. *Endocr Pract*. 2008;14:1011-1016.
7. Mastoris K PS, Magaji V. 1,25-Dihydroxyvitamin D-mediated hypercalcemia in a patient with malignancy without lymphoma. *Int J Case Rep Images*. 2015;6:403-406.
8. Scheinman SJ, Kelberman MW, Tatum AH, Zamkoff KW. Hypercalcemia with excess serum 1,25-dihydroxyvitamin D in lymphomatoid granulomatosis/angiocentric lymphoma. *Am J Med Sci*. 1991;301:178-181.
9. Al-Moundhri MS, Al-Thahli K, Al-Kindy S, Salam J, Rao L. Metastatic gastrointestinal stromal tumor and hypercalcemia in a patient with ulcerative colitis. *Saudi Med J*. 2006;27:1585-1587.
10. Jasti P, Lakhani VT, Woodworth A, Dahir KM. Hypercalcemia secondary to gastrointestinal stromal tumors: parathyroid hormone-related protein independent mechanism? *Endocr Pract*. 2013;19:e158-162.
11. Dematteo RP, Ballman KV, Antonescu CR, et al. Adjuvant imatinib mesylate after resection of localised, primary gastrointestinal stromal tumour: a randomised, double-blind, placebo-controlled trial. *Lancet*. 2009;373:1097-1104.
12. Corless CL, Barnett CM, Heinrich MC. Gastrointestinal stromal tumours: origin and molecular oncology. *Nat Rev Cancer*. 2011;11:865-878.
13. Corless CL, Ballman KV, Antonescu CR, et al. Pathologic and molecular features correlate with long-term outcome after adjuvant therapy of resected primary GI stromal tumor: the ACOSOG Z9001 trial. *J Clin Oncol*. 2014;32:1563-1570.
14. Joensuu H, Eriksson M, Sundby Hall K, et al. One vs three years of adjuvant imatinib for operable gastrointestinal stromal tumor: a randomized trial. *JAMA*. 2012;307:1265-1272.
15. Blanke CD, Rankin C, Demetri GD, et al. Phase III randomized, intergroup trial assessing imatinib mesylate at two dose levels in patients with unresectable or metastatic gastrointestinal stromal tumors expressing the kit receptor tyrosine kinase: S0033. *J Clin Oncol*. 2008;26:626-632.
16. Hewison M, Kantorovich V, Liker HR, et al. Vitamin D-mediated hypercalcemia in lymphoma: evidence for hormone production by tumor-adjacent macrophages. *J Bone Miner Res*. 2003;18:579-582.
17. Seymour JF, Gagel RF. Calcitriol: the major humoral mediator of hypercalcemia in Hodgkin's disease and non-Hodgkin's lymphomas. *Blood*. 1993;82:1383-1394.
18. Sandler LM, Winearls CG, Fraher LJ, Clemens TL, Smith R, O'Riordan JL. Studies of the hypercalcaemia of sarcoidosis: effect of steroids and exogenous vitamin D3 on the circulating concentrations of 1,25-dihydroxy vitamin D3. *QJ Med*. 1984;53:165-180.
19. Ferrero D, Pogliani EM, Rege-Cambrin G, et al. Corticosteroids can reverse severe imatinib-induced hepatotoxicity. *Haematologica*. 2006;91(6 suppl):ECR27.