

# Current therapeutic options in hairy cell leukemia

Evgeny Mikler, PA-C, and John Mascarenhas, MD

Division of Hematology and Medical Oncology, Tisch Cancer Institute, Icahn School of Medicine at Mount Sinai, New York

Hairy cell leukemia (HCL) is a B-cell chronic lymphoproliferative disorder that was initially described as leukemic reticuloendotheliosis. The disease is characterized by monocytopenia, organomegaly, constitutional symptoms, and bone marrow fibrosis. Significant advances have improved the diagnosis and management of HCL over the last 55 years. Although HCL has an indolent course, most patients will require treatment of the disease. Indications to initiate therapy include disease-related symptoms, signs of bone marrow failure, or frequent infections. Asymptomatic patients without cytopenias can be observed without the need for therapeutic interventions. Therapeutic options usually consist of chemotherapy, immunotherapy, biological agents, and surgery.

**H**airy cell leukemia (HCL) was initially described in 1958 as leukemic reticuloendotheliosis.<sup>1</sup> The disorder is rare and accounts for 2% of all adult leukemia cases in the United States.<sup>2</sup> The incidence rate is 0.3 cases per 100,000 population per year, with about 600 individuals diagnosed annually.<sup>2,3</sup> Men are affected 4 times more frequently than are women. The incidence is higher in whites than in blacks.<sup>3-5</sup> The average age of diagnosis is 52 years.<sup>6</sup> The exact etiology remains unknown.<sup>5</sup>

## Diagnosis of HCL

### Clinical presentation

About 25% of individuals with HCL have no signs or symptoms at the initial presentation. Most patients experience fatigue and generalized weakness. They may also complain of unexplained weight loss, pain in the left upper quadrant, recurrent infections, and bruising. Physical examination may reveal hepatosplenomegaly and lymphadenopathy. Dermatologic manifestations are common and include ecchymosis, purpura, zoster rash, cellulitis, abscess, pyoderma, and dermatophytosis.<sup>3</sup>

### Laboratory findings

Anemia, leukopenia, monocytopenia, and neutropenia are the most frequent hematologic abnormalities seen in patients with HCL.<sup>1</sup> Other laboratory findings may include thrombocytopenia and hypocholesterolemia. Autoimmune hemolytic anemia (AIHA) and idiopathic thrombocytopenia purpura (ITP) can also be observed.<sup>3</sup> The peripheral blood

smear demonstrates atypical lymphocytes with hair-like projections (Figure). An attempted bone marrow aspiration that is unsuccessful – as is often the case in HCL – is called a “dry tap.”<sup>7</sup> Flow cytometry of the peripheral blood or the bone marrow may reveal cells that are positive for certain clusters of differentiation (specifically, CD11c, CD19, CD20, CD22, CD25, CD103, and CD123) as well as surface-membrane immunoglobulin free light chains ( $\kappa$  or  $\lambda$ ) but are negative for CD5, CD21, and CD23.<sup>7</sup> Additional markers – such as cyclin D1, annexin A1, tartrate-resistant acid phosphatase (TRAP), the monoclonal antibody DBA.44, and the BRAF V600E mutation – are usually expressed by the malignant cell population.<sup>7-9</sup> The bone marrow biopsy is also remarkable for varying degrees of reticulin and collagen fibrosis.<sup>7</sup>

### Differential diagnosis

The differential diagnosis of HCL should include chronic lymphocytic leukemia (CLL), small lymphocytic lymphoma (SLL), polymphocytic leukemia (PLL), splenic marginal zone lymphoma (SMZL), HCL-variant, myelodysplastic syndrome (MDS), and primary myelofibrosis (PMF).<sup>10-18</sup>

### Prognostic factors

Prognostic factors can assist in identifying patients with advanced disease. These factors are based on age, hemoglobin level, and organomegaly. Poor prognostic characteristics include advanced age, a hemoglobin level < 12 gm/dL, and the presence of splenomegaly.<sup>19</sup>

Accepted for publication December 10, 2013. Correspondence: Evgeny Mikler, PA-C; [evgeny.mikler@mountsinai.org](mailto:evgeny.mikler@mountsinai.org). Disclosures: The authors have no disclosures. JCSO 2014;12:104-108. ©2014 Frontline Medical Communications. DOI 10.12788/jcso.0027

## Treatment in HCL

Asymptomatic patients are usually observed because there is no proven clinical benefit in early treatment.<sup>19-21</sup> Reasons to begin therapy would include the presence of severe fatigue and weakness that interfere with the patient's quality of life; symptomatic splenomegaly or lymphadenopathy; signs of bone marrow failure (ie, a hemoglobin level < 10 g/dL, a platelet count < 100,000/ $\mu$ L and an absolute neutrophil count < 1,000/ $\mu$ L and the occurrence of frequent infections.<sup>20</sup>

Pharmacologic therapy consists of purine analogs, interferon, and monoclonal antibodies.<sup>6-7,19-20</sup> Other treatment options may include splenectomy and splenic irradiation.<sup>21,22</sup>

### Splenectomy

Historically, splenectomy was the only available treatment option for patients with HCL and symptomatic splenomegaly; it relieved symptoms related to an enlarged spleen and temporarily improved cytopenias.<sup>21</sup> However, splenectomy is associated with a risk of hemorrhage, which is the second most common cause of death in patients with HCL, thus making it challenging to perform, especially in older patients.<sup>22</sup> Currently, splenectomy is reserved for patients with primary splenic HCL who are refractory to medical therapy, for patients with splenic rupture, or for diagnostic purposes.<sup>6,21-22</sup>

### Interferon

The first reports of significant clinical activity in HCL via interferon-alpha (IFN- $\alpha$ ) were made in 1984; these investigators reported on 7 patients who had a 43% complete remission (CR) and a partial remission (PR) of 57%.<sup>23</sup>

In a small, randomized, 1992 study comparing IFN- $\alpha$  vs splenectomy, patients who received IFN- $\alpha$  showed higher responses and had longer median times both to response and to treatment failure.<sup>24</sup> IFN- $\alpha$  became the first medical therapy that demonstrated clinical benefit over splenectomy, producing mostly partial responses. This study showed that medical therapy could be successfully given to patients with HCL-related cytopenias.

In 1995, researchers reported the long-term follow-up of 55 previously untreated HCL patients after 1 year of treatment with IFN- $\alpha$ .<sup>25</sup> The overall response rate (ORR) was 73%, with a CR of 49% and a PR of 24%; in all, 83% (46 patients) remained alive at 6 years. Currently, IFN- $\alpha$  is used for HCL patients with relapsed and/or refractory disease after purine analogs.<sup>6,20-21,26</sup>

### Purine analogs

Clinical trials evaluating purine analogs in HCL, including pentostatin and cladribine, have demonstrated improved tolerability and ORR; reduction in size of spleen and lymph nodes; and longer time to progression.

**TABLE 1** Results of cladribine therapy in previously treated patients with hairy cell leukemia

Source	N	ORR, %	CR, %	PR, %
Hoffman <sup>32,a</sup>	21	100	76	24
Saven <sup>33,a</sup>	179	98	91	7
Goodman <sup>34,a</sup>	119	100	95	5
Else <sup>35,a</sup>	18	100	82	18
Piro <sup>31</sup>	12	100	92	8
Dearden <sup>36,a</sup>	54	100	76	24
Jehn <sup>37</sup>	44	100	98	2
Chadha <sup>38,a</sup>	60	100	79	21
Tallman <sup>39,a</sup>	27	98	80	18

CR, complete remission rate; N, total number of patients; ORR, overall response rate; PR, partial remission  
<sup>a</sup>Response rates included previously treated patients.

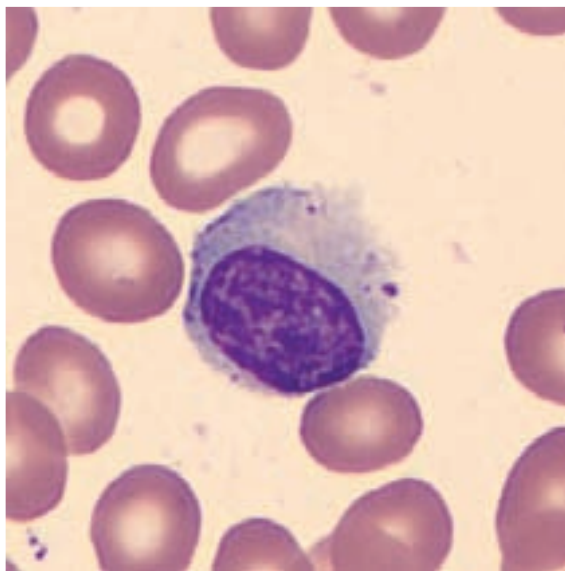
The first report of treating HCL with pentostatin was published in 1984, when 2 patients with advanced HCL both achieved a CR with the drug.<sup>27</sup> In 1995, a large intergroup trial compared pentostatin vs IFN- $\alpha$ ; patients who received pentostatin showed a significantly higher ORR (79% vs 38%) and CR (76% vs 11%).<sup>28</sup> Relapse-free survival (RFS) was also higher for those in the pentostatin group, but overall survival (OS) was not significantly different between the 2 therapies.<sup>28,29</sup>

Currently, cladribine is considered to be the treatment of choice because of its short duration of therapy, favorable adverse-effect profile, durable response rates, and improvement in disease-free survival.<sup>30</sup> In 1990, a single-institution trial of 12 patients who were treated with 1 cycle of cladribine showed an ORR of 100% and a CR of 92%.<sup>31</sup> In addition, other reports of treatment-naïve patients with HCL have shown ORRs ranging between 98% and 100%, with CRs ranging between 76% and 95% (Table).<sup>32-39</sup> Relapsed disease after the initial therapy can be either retreated with another course of cladribine or switched to pentostatin.<sup>6,19,20</sup>

### Monoclonal antibodies

Monoclonal antibodies have been evaluated in the treatment of HCL in a number of small clinical trials.

Rituximab is a chimeric, murine monoclonal antibody against CD20 and an active agent in treating B-cell lymphoid disorders. The first report of successful therapy with rituximab in a patient with HCL that was refractory to cladribine was published in 1999.<sup>40</sup> A year later, a case study reported a CR with rituximab therapy in an HCL patient.<sup>41</sup> In 2001, a report of 11 patients who were treated with rituximab as a single agent noted that 6 of them achieved a CR and 1 achieved a PR, with an ORR of 64%.<sup>42</sup> A single-institution trial of 15



**FIGURE 1** An atypical lymphocyte with hairlike projections can be seen on a peripheral blood smear (Wright's stain, 1,000x magnification).

patients who were treated with weekly rituximab therapy showed an ORR of 80% and a CR of 53%.<sup>43</sup> A phase 2 trial of rituximab in patients who previously failed cladribine therapy showed an ORR of 24% and a CR of 12%.<sup>44</sup> Monotherapy with rituximab demonstrated good tolerability, with ORRs ranging between 24% and 80%, and CRs between 12% and 53%.<sup>42-45</sup>

Rituximab also has been evaluated in combination with purine analogs in the relapsed/refractory setting, and was shown to be effective in eradicating minimally residual disease that can be detected by immunophenotyping by flow cytometry, immunohistochemistry, and polymerase chain reaction.<sup>46,47</sup> The lack of data from large, prospective, randomized trials precludes the routine use of this agent in the upfront setting.

Alemtuzumab is a monoclonal antibody that is approved by the US Food and Drug Administration for the treatment of CLL. It is a humanized, anti-CD52 antibody that could be used in the relapsed setting.<sup>48,49</sup> However, additional trials are needed to formally establish it as a therapeutic option in HCL.

The role of monoclonal antibodies in the treatment of HCL remains largely undefined because there have been no large prospective studies to support their use; for patients in the relapsed/refractory setting, enrolment in clinical trials that are evaluating these biologics is most appropriate.

### Radiation therapy

Radiation therapy has been used largely for the treatment of skeleton-related complications associated with HCL,

such as lytic lesions.<sup>21</sup> Splenic irradiation is rarely used as a treatment modality, mostly because of the availability of other effective treatment options, as previously mentioned in this review. Currently, radiation is reserved for patients who have symptomatic splenomegaly and are not good candidates for other therapeutic options.<sup>50</sup>

### Novel therapies

There are several novel therapies in the early phases of development. They include anti-CD22 (BL-22) and anti-CD25 (LMB-2) monoclonal antibodies.<sup>51,52</sup> In 2000, a report of 4 patients who were treated with LMB-2 (a recombinant immunotoxin against CD25) noted that 3 of them achieved a PR and 1 achieved a CR.<sup>51</sup> In 2005, a phase I study of 31 patients who were treated with BL-22 (an anti-CD 22 recombinant immunotoxin) resulted in an ORR of 80%, with a CR of 61% and a PR of 19%.<sup>52</sup> In 2011, the BRAF V600E mutation was found in all 47 HCL patients.<sup>8</sup> Vemurafenib (a BRAF inhibitor that has shown clinical benefit in patients with advanced forms of melanoma) has also recently been shown to have activity as a single agent in the treatment of refractory HCL.<sup>53-55</sup>

### Complications in HCL

Patients with HCL are susceptible to infectious complications. They can develop anemia, thrombocytopenia, neutropenia, monocytopenia, or platelet dysfunction at any time during their disease course.<sup>3</sup> Other complications include lytic bone lesions, inflammatory arthritis, vasculitis, and T-cell dysfunction. Splenic rupture has also been reported.<sup>3,22</sup> Although infections are the most common cause of death in these patients, there are no established recommendations for routine antimicrobial, antiviral, or antifungal prophylaxis.<sup>20</sup> Individuals with HCL also appear to be at a higher risk for the development of secondary malignancies.<sup>56-58</sup>

### Conclusion

HCL is a rare, B-cell chronic lymphoproliferative disorder. The disease is indolent, so patients should be observed until they develop signs or symptoms of disease progression. Those who require therapy are initially treated with purine analogs. Other therapeutic options include monoclonal antibodies, IFN- $\alpha$ , and splenectomy when clinically warranted. Monoclonal antibodies can be used alone or in combination with purine analogs, and are currently being evaluated in clinical trials. Future directions include the development of novel targeted therapies; further evaluation of monoclonal antibodies as single agents and in combination in the upfront setting; and subsequent lines of therapy in well-designed clinical trials.

### References

1. Bouroncle BA, Wiseman BK, Doan CA. Leukemic reticuloendotheliosis. *Blood*. 1958;13:609-630.

2. Morton LM, Turner JJ, Cerhan JR, et al. Proposed classification of lymphoid neoplasms for epidemiologic research from the Pathology Working Group of the International Lymphoma Epidemiology Consortium (InterLymph). *Blood*. 2007;110:695-708.
3. Hoffman MA. Clinical presentations and complications of hairy cell leukemia. *Hematol Oncol Clin North Am*. 2006;20:1065-1073.
4. Morton LM, Wang SS, Devesa SS, Hartge P, Weisenburger DD, Linet MS. Lymphoma incidence patterns by WHO subtype in the United States, 1992-2001. *Blood*. 2006;107:265-276.
5. Oleske D, Golomb HM, Farber MD, Levy PS. A case-control inquiry into the etiology of hairy cell leukemia. *Am J Epidemiol*. 1985;121:675-683.
6. Robak T. Current treatment options in hairy cell leukemia and hairy cell leukemia variant. *Cancer Treat Rev*. 2006;32:365-376.
7. Jones J, Parry-Jones N, Wilkins B, Else M, Catovsky D, British Committee for Standards in Haematology. Revised guidelines for the diagnosis and management of hairy cell leukemia and hairy cell leukemia variant. *Br J Haematol*. 2012;156:186-195.
8. Tiacci E, Trifonov V, Schiavoni G, et al. BRAF mutations in hairy-cell leukemia. *N Engl J Med*. 2011;364:2305-2315.
9. Arcaini L, Zibellini S, Boveri E, et al. The BRAF V600E mutation in hairy cell leukemia and other mature B-cell neoplasms. *Blood*. 2012;119:188-191.
10. Kroft SH, Finn WG, Peterson LC. The pathology of the chronic lymphoid leukaemias. *Blood Rev*. 1995;9:234-250.
11. Galton DA, Goldman JM, Wiltshaw E, Catovsky D, Henry K, Goldenberg GJ. Polymorphocytic leukaemia. *Br J Haematol*. 1974;27:7-23.
12. Catovsky D, O'Brien M, Melo JV, Wardle J, Brozovic M. Hairy cell leukemia (HCL) variant: an intermediate disease between HCL and B polymorphocytic leukemia. *Semin Oncol*. 1984;11:362-369.
13. Matutes E, Morilla R, Owusu-Ankomah K, Houlihan A, Catovsky D. The immunophenotype of splenic lymphoma with villous lymphocytes and its relevance to the differential diagnosis with other B-cell disorders. *Blood*. 1994;83:1558-1562.
14. Hallek M, Cheson BD, Catovsky D, et al. Guidelines for the diagnosis and treatment of chronic lymphocytic leukemia: a report from the International Workshop on Chronic Lymphocytic Leukemia updating the National Cancer Institute-Working Group 1996 guidelines. *Blood*. 2008;111:5446-5456.
15. Bennett JM, Catovsky D, Daniel MT, et al. Proposals for the classification of the myelodysplastic syndromes. *Br J Haematol*. 1982;51:189-199.
16. Tefferi A. Primary myelofibrosis: 2012 update on diagnosis, risk stratification, and management. *Am J Hematol*. 2011;86:1017-1026.
17. Campo E, Swerdlow SH, Harris NL, Pileri S, Stain H, Jaffe ES. The 2008 WHO classification of lymphoid neoplasms and beyond: evolving concepts and practical applications. *Blood*. 2011;117:5019-5032.
18. International Agency for Research on Cancer. WHO classification of tumours of haematopoietic and lymphoid tissues. 4th ed. Swerdlow SH, Campo E, Harris NL, et al, eds. IARC WHO Classification of Tumours, No. 2. Lyon, France: IARC Press; 2008.
19. Graver MR. How I treat hairy cell leukemia. *Blood*. 2010;115:21-28.
20. Naik RR, Saven A. My treatment approach to hairy cell leukemia. *Mayo Clin Proc*. 2012;87:67-76.
21. Habermann TM, Rai KR. Historical treatments of hairy cell leukemia, splenectomy and interferon: past and current uses. *Leuk Lymphoma*. 2011;52(suppl 2):18-20.
22. Zakarija A, Peterson LC, Tallman MS. Splenectomy and treatments of historical interest. *Best Pract Res Clin Haematol*. 2003;16:57-68.
23. Quesada JR, Reuben J, Manning JT, Hersh EM, Gutterman JU. Alpha interferon for induction of remission in hairy-cell leukemia. *N Engl J Med*. 1984;310:15-18.
24. Smalley RV, Connors J, Tuttle RL, Anderson S, Robinson W, Whisnant JK. Splenectomy vs alpha interferon: a randomized study in patients with previously untreated hairy cell leukemia. *Am J Hematol*. 1992;41:13-18.
25. Rai KR, Davey F, Peterson B, et al. Recombinant alpha-2b-interferon in therapy of previously untreated hairy cell leukemia: long-term follow-up results of study by Cancer and Leukemia Group B. *Leukemia*. 1995;9:1116-1120.
26. Ahmed S, Rai KR. Interferon in the treatment of hairy-cell leukemia. *Best Pract Res Clin Haematol*. 2003;16:69-81.
27. Spiers AS, Parekh SJ, Bishop MB. Hairy-cell leukemia: induction of complete remission with pentostatin (2'-deoxycoformycin). *J Clin Oncol*. 1984;2:1336-1342.
28. Grever M, Kopecky K, Foucar M K, et al. Randomized comparison of pentostatin versus interferon alfa-2a in previously untreated patients with hairy cell leukemia: an intergroup study. *J Clin Oncol*. 1995;13:974-982.
29. Ribeiro P, Bouaffia F, Peaud P, et al. Long-term outcome of patients with hairy cell leukemia treated with pentostatin. *Cancer*. 1999;85:65-71.
30. Else M, Osuji N, Forconi F, et al. The role of rituximab in combination with pentostatin or cladribine for the treatment of recurrent/refractory hairy cell leukemia. *Cancer*. 2007;110:2240-2247.
31. Piro LD, Carrera CJ, Carson DA, Beutler E. Lasting remissions in hairy-cell leukemia induced by a single infusion of 2-chlorodeoxyadenosine. *N Engl J Med*. 1990;322:1117-1121.
32. Hoffman MA, Janson D, Rose E, Rai KR. Treatment of hairy-cell leukemia with cladribine: response, toxicity, and long-term follow-up. *J Clin Oncol*. 1997;15:1138-1142.
33. Saven A, Burian C, Koziol JA, Piro LD. Long-term follow-up of patients with hairy cell leukemia after cladribine treatment. *Blood*. 1998;92:1918-1926.
34. Goodman GR, Burian C, Koziol JA, Saven A. Extended follow-up of patients with hairy cell leukemia after treatment with cladribine. *J Clin Oncol*. 2003;21:891-896.
35. Else M, Ruchlemer R, Osuji N, et al. Long remissions in hairy cell leukemia with purine analogs: a report of 219 patients with a median follow-up of 12.5 years. *Cancer*. 2005;104:2442-2448.
36. Dearden CE, Else M, Catovsky D. Long-term results for pentostatin and cladribine treatment of hairy cell leukemia. *Leuk Lymphoma*. 2011;52(suppl 2):21-24.
37. Jehn U, Bartl R, Dietzfelbinger H, Haferlach T, Heinemann V. An update: 12-year follow-up of patients with hairy cell leukemia following treatment with 2-chlorodeoxyadenosine. *Leukemia*. 2004;18:1476-1481.
38. Chadha P, Rademaker AW, Mendiratta P, et al. Treatment of hairy cell leukemia with 2-chlorodeoxyadenosine (2-CdA): long-term follow-up of the Northwestern University experience. *Blood*. 2005;106:241-246.
39. Tallman MS, Hakimian D, Rademaker AW, et al. Relapse of hairy cell leukemia after 2-chlorodeoxyadenosine: long-term follow-up of the Northwestern University experience. *Blood*. 1996;88:1954-1959.
40. Hagberg H. Chimeric monoclonal anti-CD20 antibody (rituximab)—an effective treatment for a patient with relapsing hairy cell leukemia. *Med Oncol*. 1999;16:221-222.
41. Hoffman M, Auerbach L. Bone marrow remission of hairy cell leukaemia induced by rituximab (anti-CD20 monoclonal antibody) in patients refractory to cladribine. *Br J Haematol*. 2000;109:900-901.
42. Hagberg H, Lundholm L. Rituximab, a chimaeric anti-CD20 monoclonal antibody, in the treatment of hairy cell leukaemia. *Br J Haematol*. 2001;115:609-611.
43. Thomas DA, O'Brien S, Bueso-Ramos C, et al. Rituximab in relapsed or refractory hairy cell leukemia. *Blood*. 2003;102(12):3906-3911.
44. Nieva J, Bethel K, Saven A. Phase 2 study of rituximab in the treatment of cladribine-failed patients with hairy cell leukemia. *Blood*. 2003;102:810-813.
45. Lauria F, Lenoci M, Annino L, et al. Efficacy of anti-CD20 monoclonal antibodies (Mabthera) in patients with progressed hairy cell leukemia. *Haematologica*. 2001;86:1046-1050.
46. Ravandi F, Jorgensen JL, O'Brien SM, et al. Eradication of minimal residual disease in hairy cell leukemia. *Blood*. 2006;107(12):4658-4662.
47. Cervetti G, Galimberti S, Andreazzoli F, et al. Rituximab as treatment for minimal residual disease in hairy cell leukaemia. *Eur J Haematol*. 2004;73:412-417.
48. Quigley MM, Bethel KJ, Sharpe RW, Saven A. CD52 expression in hairy cell leukemia. *Am J Hematol*. 2003;74:227-230.
49. Fietz T, Rieger K, Schmittel A, Thiel E, Knauf W. Alemtuzumab (Campath 1H) in hairy cell leukemia relapsing after rituximab treatment. *Hematol J*. 2004;5:451-452.
50. Nishii K, Katayama N, Maeda H, et al. Successful treatment with low-dose splenic irradiation for massive splenomegaly in an elderly patient with hairy-cell leukemia. *Eur J Haematol*. 2001;67:255-257.

51. Kreitman RJ, Wilson WH, White JD, et al. Phase I trial of recombinant immunotoxin anti-Tac(Fv)-PE38 (LMB-2) in patients with hematologic malignancies. *J Clin Oncol.* 2000;18:1622-1636.
52. Kreitman RJ, Wilson WH, Bergeron K, et al. Efficacy of the anti-CD22 recombinant immunotoxin BL22 in chemotherapy-resistant hairy-cell leukemia. *N Engl J Med.* 2001;345:241-247.
53. Chapman PB, Hauschild A, Robert C, et al. Improved survival with vemurafenib in melanoma with BRAF V600E mutation. *N Engl J Med.* 2011;364:2507-2516.
54. Dietrich S, Glimm H, Andrulis M, von Kalle C, Ho AD, Zenz T. BRAF inhibition in refractory hairy-cell leukemia. *N Engl J Med.* 2012;366:2038-2040.
55. Peyrade F, Re D, Ginet C, et al. Low-dose vemurafenib induces complete remission in a case of hairy-cell leukemia with a V600E mutation. *Haematologica.* 2013;98:e20-22.
56. Federico M, Zinzani PL, Frassoldati A, et al. Risk of second cancer in patients with hairy cell leukemia: long-term follow-up. *J Clin Oncol.* 2002;20:638-646.
57. Hisada M, Chen BE, Jaffe ES, Travis LB. Second cancer incidence and cause-specific mortality among 3,104 patients with hairy cell Leukemia: a population-based study. *J Natl Cancer Inst.* 2007;99:215-222.
58. Mikler E, Petersen B, Mascarenhas J. A case report of hairy cell leukemia and breast cancer. *Clin Adv Hematol Oncol.* 2013;1(7)1:460-462.