

## THE CLINICAL PICTURE

**EMILY JERNIGAN, BS**

Texas College of Osteopathic Medicine,  
University of North Texas Health Science  
Center, Fort Worth, TX

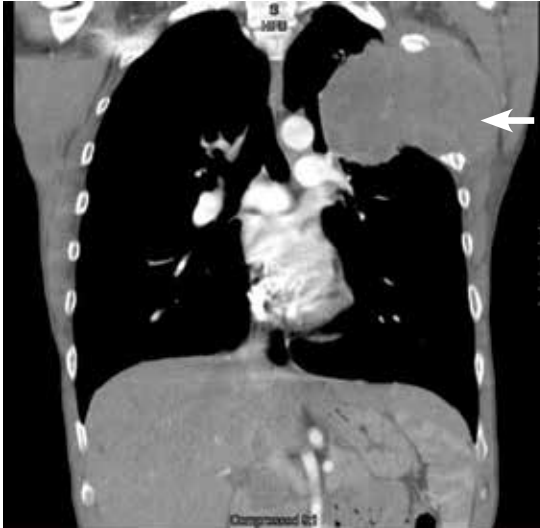**NADIA SIDDIQI, DO**

Good Shepherd Medical Center,  
Longview, TX

**PRASHANTH PEDDI, MD**

Academic Hospitalist, Good Shepherd  
Medical Center, Longview, TX

# Joint pain in a man with lung cancer

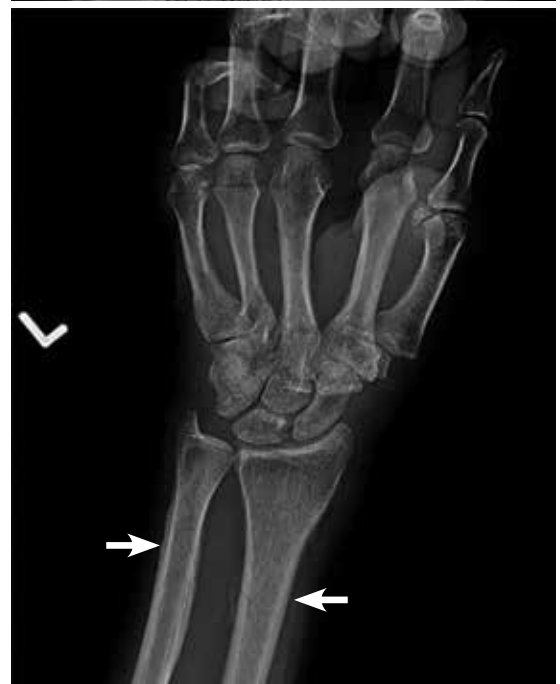
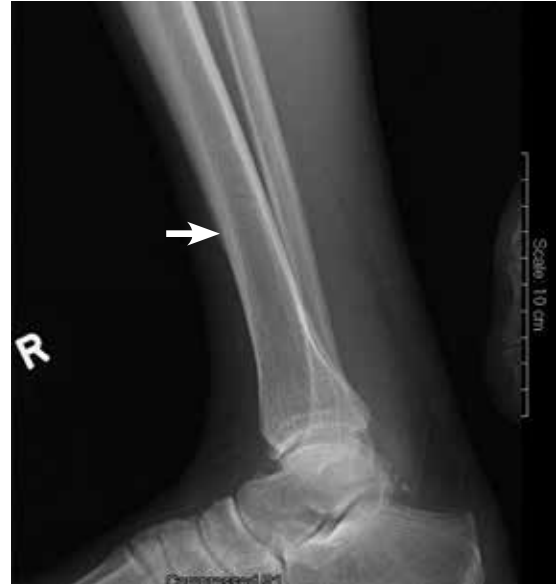
**FIGURE 1.** Computed tomography showed a mass in the left upper lobe of the lung (arrow), eroding the ribs and extending into the axilla.

**His joint pain  
had worsened  
over the past  
2 months**

**A** 46-YEAR-OLD MAN with a 50-pack-year smoking history, hepatitis C, and poly-substance abuse presented with worsening joint pain over the past 2 months involving both knees, ankles, wrists, and hands. On examination, along with clubbing of the fingers and toes, he had tenderness and restriction in range of motion in all the affected joints. A fixed, nontender, hard mass was noted in the left axilla extending into the infraclavicular and supraclavicular regions.

Computed tomography (CT) with contrast revealed a mass in the left upper lobe of the lung, eroding the ribs and extending into the axilla, consistent with a suspected diagnosis of lung cancer (FIGURE 1). Radiography of the hands and feet showed thickening of the periosteal membrane and periosteal formation of new bone (FIGURE 2). A bone scan revealed diffuse increased uptake



**FIGURE 2.** Radiography of the hands and feet showed thickening of the periosteal membrane and formation of new periosteal bone (arrows).

doi:10.3949/ccjm.82a.13137

in the affected joints with no metastases (FIGURE 3). A workup for brain and adrenal metastases was negative. CT-guided needle biopsy confirmed adenocarcinoma of the lung.

The final diagnosis was hypertrophic pulmonary osteoarthropathy (HPOA) secondary to stage IIIB: T4N2M0 adenocarcinoma of the lung. Resection of the lung mass was deemed difficult, so the patient was scheduled for neoadjuvant concurrent chemoradiation therapy before resection. Ibuprofen and intravenous pamidronate provided symptom relief.

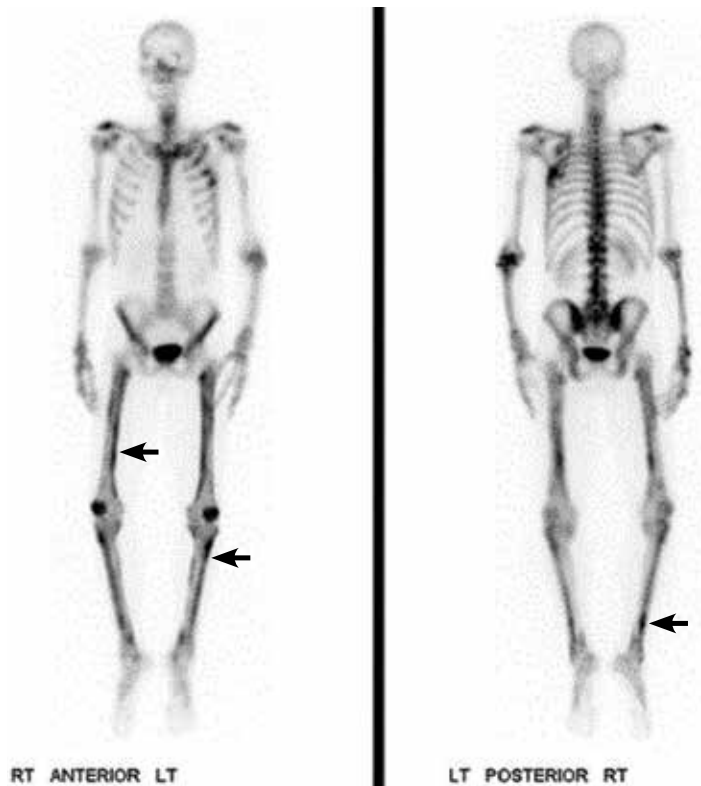
**■ HYPERTROPHIC PULMONARY OSTEOARTHROPATHY**

HPOA is characterized by abnormal proliferation of the skin and periosteal formation of new bone at the distal ends of long bones, metatarsals, metacarpals, and proximal phalanges.

Primary HPOA is genetically inherited and accounts for 5% of cases, while secondary HPOA, accounting for the other 95%, is a paraneoplastic syndrome.<sup>1</sup> Secondary HPOA is most commonly associated with lung cancer, usually stage III or IV adenocarcinoma.<sup>1</sup> However, only 1% of lung cancer patients develop HPOA.<sup>1</sup>

Other conditions linked to secondary HPOA are mesothelioma, renal cell carcinoma, gastrointestinal cancers, melanoma, thymic cancer, nasopharyngeal cancers, and Hodgkin lymphoma. HPOA is also associated with pulmonary infection, cystic fibrosis, and right-to-left cardiac shunt. Risk factors associated with secondary HPOA are smoking, male sex, and age greater than 55.

Patients often present with unremitting pain, edema, and erythema in the extremities. Radiography reveals periosteal membrane thickening and periosteal new bone formation.<sup>1</sup> Findings on bone scintigraphy that confirm the diagnosis include diffuse increased uptake and bracelet-like uptake.



**FIGURE 3.** A bone scan revealed diffuse increased uptake in the affected joints, most evident in the darkened areas of the long bones below the patella and on the medial sides of the femurs (arrows), but no metastases.

The prognosis and treatment of secondary HPOA are directly related to the underlying disease. Symptoms can be relieved with non-steroidal anti-inflammatory drugs, bisphosphonates, and octreotide. Unilateral vagotomy is an option in refractory cases.<sup>1,2</sup> ■

**■ REFERENCES**

1. Ito T, Goto K, Yoh K, et al. Hypertrophic pulmonary osteoarthropathy as a paraneoplastic manifestation of lung cancer. *J Thorac Oncol* 2010; 5:976-980.
2. Davis MC, Sherry V. Hypertrophic osteoarthropathy as a clinical manifestation of lung cancer. *Clin J Oncol Nurs* 2011; 15:561-563.

**ADDRESS:** Emily Jernigan, BS, Texas College of Osteopathic Medicine, University of North Texas Health Science Center, 3500 Camp Bowie Boulevard, Fort Worth, TX 76107; e-mail: eej0024@live.unthsc.edu