

AJOE JOHN KATTOOR, MD
Internal Medicine, University of Arkansas
for Medical Sciences, Little Rock

THOMAS W. BAUER, MD, PhD
Department of Anatomic Pathology,
Cleveland Clinic

MARK BERKOWITZ, MD
Department of Orthopedic Surgery,
Cleveland Clinic

JOSHUA M. POLSTER, MD
Staff Radiologist, Imaging Institute, Cleveland
Clinic; Associate Professor, Cleveland Clinic
Lerner College of Medicine of Case Western
Reserve University, Cleveland, OH

ALAN E. LICHTIN, MD*
Department of Hematology and Medical
Oncology, Cleveland Clinic

Ankle pain in a young woman with Gaucher disease

A 20-YEAR-OLD WOMAN with Gaucher disease presents with pain in her right ankle and in her back. She has had the ankle pain for the past 12 months and the back pain for the past 2 years. She describes the ankle pain as stabbing and moderately severe. It is constant, present both at rest and during physical activity, but aggravated by walking and twisting movements. She has noticed grinding and clicking sounds as she moves her ankle. The ankle pain has worsened over the past several months.

She says her back pain is similar to her ankle pain but less severe. She also reports generalized mild aches and bone pain. No other joints are involved. She has no history of fever, chills, or trauma.

■ A COMPLICATED MEDICAL HISTORY

Her Gaucher disease was diagnosed at age 4 when she presented with failure to thrive and with thrombocytopenia and splenomegaly. She was found to have an N370S/IVS2+1 mutation of the *GBA* gene. She underwent removal of 90% of her spleen at the time of diagnosis and was on enzyme replacement therapy with imiglucerase until 3 years ago, when the treatment was stopped because the drug had become unavailable (because of a temporary closure of the manufacturing facility), and because she had developed neutralizing antibodies to it. Despite a dosage as high as 120 U/kg every 2 weeks (the recommended range is 2.5 U/kg three times a week up to 60 U/kg every 2 weeks), her anemia and thrombocytopenia

worsened to the point that she became dependent on transfusion of red blood cells and platelets. She has also taken glucocorticoids at various times in the past as a premedication before enzyme replacement therapy.

About 3 years ago, she developed dryness of the skin, pruritus, shiny skin, hardening of the skin, and decreased oral aperture, which was diagnosed as scleroderma.

During the past 5 years, she has had multiple episodes of pale coloration of her skin on exposure to cold, suggestive of Raynaud phenomenon. And for the past 5 months, she has noticed a burning sensation in her throat and retrosternal pain, suggestive of gastroesophageal reflux disease.

She is a college student, with no history of smoking or use of alcohol or recreational drugs. She is sexually active, with no history of sexually transmitted disease, and she uses condoms and oral contraceptives for contraception.

Her father and mother are both carriers of Gaucher disease. She is not of Ashkenazi Jewish descent.

■ FINDINGS ON PHYSICAL EXAMINATION

On physical examination, her temperature, blood pressure, pulse, and respiratory rate are within normal limits. She has extensive tattooing on her upper chest to hide scarring from previous cannulation ports. The right ankle joint is moderately swollen but shows no other signs of inflammation; its range of motion is limited by severe pain. She has tenderness of the spinous processes and paraspinal area, in addition to multiple tender points in the thoracolumbar area. Palpation of the right hip reveals tenderness of the groin and trochanteric bursa.

Gaucher disease causes hepatomegaly, splenomegaly, bone marrow disease, and skeletal manifestations

*Dr. Lichtin has disclosed membership on advisory committees or review panels for Pfizer.

TABLE 1

Results of initial laboratory testing

Complete blood cell count

Hemoglobin	8.3 g/dL (reference range 11.5–15.5)
Hematocrit	25.4% (36.0–46.0)
Mean corpuscular volume	93.7 fL (80–100)
Platelet count	37 × 10 ⁹ /L (150–400)
White blood cell count	2.69 × 10 ⁹ /L (3.70–11.00)
Reticulocyte count	4.2% (0.5%–2.0%)
Differential count	Normal
Peripheral smear	Consistent with pancytopenia, normocytic anemia without polychromasia, and leukopenia with absolute lymphopenia

C-reactive protein 0.2 mg/dL (0–0.5)

Antinuclear antibody panel

Antinuclear antibody	Positive at 1:320
Anticentromere antibody	Positive (≥ 8.0 U)
Sjögren SSA, SSB	Negative
Scleroderma antibody	Low (< 0.2 U)
Complement C3, C4	Negative
Anti-ds DNA	Negative
Anti-Sm	Negative
Anti-histone	Negative

No lymphadenopathy, hepatomegaly, splenomegaly, or abdominal masses are noted. Neurologic examination is essentially nonfocal.

Her current medications include omeprazole, ergocalciferol, calcium carbonate, gabapentin, citalopram, and celecoxib. She also takes a multivitamin daily.

1 Which is the most likely underlying cause of her ankle pain?

- Rheumatoid arthritis
- Gaucher disease
- Septic arthritis
- Avascular necrosis secondary to steroid use

Rheumatoid arthritis varies in its presen-

tation. It is usually insidious in onset, migratory, and intermittent, with polyarticular or even monoarticular involvement, and it presents with pain, stiffness, and swelling of the joint.¹ Most often affected are the metacarpophalangeal, proximal interphalangeal, wrist, and metatarsophalangeal joints. Involvement of large joints of the upper and lower limbs is also common.² This is not the most likely cause of this patient’s symptoms, based on the history and the current presentation.

Gaucher disease is a lipidosis caused by accumulation of cellular glycolipids, especially glucocerebrosides, due to deficiency of the enzyme beta-glucosidase. Clinical manifestations include hepatomegaly, splenomegaly, and bone marrow disease presenting as anemia, thrombocytopenia, or skeletal disease.³ Skeletal involvement in Gaucher disease includes bone pain, bone infarcts, and lytic lesions.

Whether splenectomy predisposes the patient to bone manifestations is controversial. Some believe that splenectomy decreases the total body reservoir for the storage of glycolipids and predisposes to their deposition in bone, which in turn results in cortical thinning, impaired remodeling, and decreased intraosseous blood flow, leading to osteonecrosis and fractures.⁴ This is more common in patients with type 1 Gaucher disease who have undergone splenectomy. (Types 2 and 3 are much rarer, occurring mainly in children; central nervous system involvement is a key feature. A discussion of these types is beyond the focus of this paper.) However, some studies suggest that the increase in bone manifestations after splenectomy may be simply because of severe disease.⁵ It should be noted that, since the advent of enzyme replacement therapy for Gaucher disease, splenectomy is now rarely performed.⁶

Anemia is also considered an independent risk factor for the development of avascular necrosis in type 1 Gaucher disease.⁷ Osteonecrosis due to Gaucher disease is relatively common in the femur, tibia, and humerus and uncommon in the ankle joints.⁸

Septic arthritis is unlikely in this patient in the absence of fever or signs of inflammation of the joint. Her long-standing history of ankle pain would also be unusual for infection, but a superimposed infectious process should always be suspected in an arthritic joint.

Avascular necrosis secondary to steroid use. Glucocorticoids are notorious for their adverse effects on bone. They induce osteocyte apoptosis and a decrease in bone remodeling, potentially predisposing to osteonecrosis.⁹ There is a high incidence of osteoporosis, osteonecrosis, and fracture risk with glucocorticoid therapy, and the incidence is dose-dependent. Discontinuation of the drug only partially restores fracture risk to baseline levels.^{10,11}

A meta-analysis of cohort studies with a total sample size of about 42,000 reported an increased risk of fracture at all ages with the use of glucocorticoids.¹² Because the minimum dosage and duration of therapy to prevent glucocorticoid-induced osteoporosis are not known, the only recommendation is to keep the dosage as low as possible.¹³

Glucocorticoid therapy is the most common cause of nontraumatic avascular necrosis. The risk of osteonecrosis in patients on long-term glucocorticoid therapy may be as high as 40%.¹⁴ The risk is increased with prolonged treatment and with high doses, but it can also occur with short-term exposure to high doses. The increased risk has been shown to persist for as long as 2 years after the drugs are discontinued.¹⁵ Glucocorticoid-induced bone disease commonly affects the hip and vertebrae.

At this stage of the workup, we cannot completely rule out glucocorticoid use as the cause. However, after considering this patient's presentation and the key features of the other diagnoses, her ankle pain and back pain are more likely caused by her preexisting Gaucher disease.

■ CONTINUED EVALUATION

Initial laboratory tests (Table 1) reveal severe anemia and thrombocytopenia. Bone marrow biopsy of the iliac crest done as part of the workup for these conditions shows extensive bone marrow space replacement by histiocytic infiltrate, consistent with Gaucher disease. No other marrow process is observed.

Radiography of the ankle (Figure 1) shows a subtle lucency in the talar dome with minimal subarticular collapse seen on the lateral view, suggestive of avascular necrosis and diffuse osteopenia. Joint spaces are maintained.

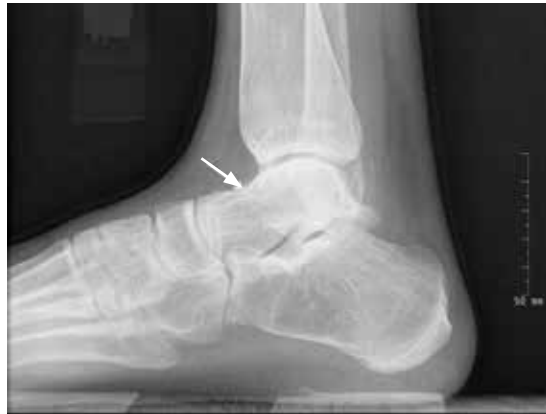

FIGURE 1. A radiograph of the right ankle at the time of presentation shows evidence of talar dome collapse (arrow) due to avascular necrosis of the talus body.

Magnetic resonance imaging (MRI) of the ankle shows numerous bone infarcts with an approximately 15-mm region of mild articular surface collapse in the central and lateral aspect of the talar dome.

MRI of the back shows extensive abnormal bone marrow signal intensity throughout the spine, compatible with a marrow replacement process. Patchy nonexpansile T2/stir hyperintensity with serpiginous enhancement within the T9, T11, T12, L2, and L3 vertebral bodies as well as throughout the entire sacrum is consistent with bone infarct.

2 Based on the results of radiographic studies, which is most likely the immediate cause of her ankle pain?

- Talar avascular necrosis secondary to rheumatoid arthritis
- Talar avascular necrosis secondary to Gaucher disease
- Trauma-induced fracture of the talus
- Plantar fasciitis

Of the bones of the feet, the talus is unique. It is the second largest of the tarsal bones and does not have muscular or tendinous attachments. Sixty percent of the talus bone is covered by articular cartilage,¹⁶ so only a limited area is available for penetration of blood vessels. Also, small nutrient vessels and variations of intraosseous anastomoses with a lack of collateral circulation predispose the talus to osteonecrosis when the vascular supply is

A superimposed infectious process should always be suspected in an arthritic joint

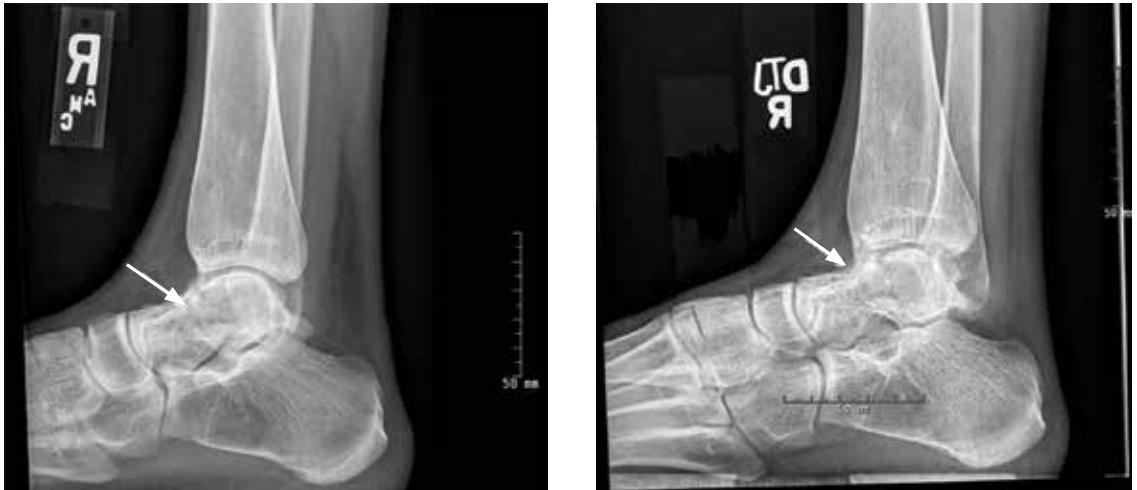

FIGURE 2. Radiographs after 4 months of conservative therapy (left) and just before below-the-knee amputation (right), when viewed along with **Figure 1**, show progressive talar dome collapse due to avascular necrosis of the talus body.

compromised.¹⁶

Radiographic evidence of avascular necrosis is the presence of bone that is more radiopaque than normal bone; this is necrotic bone surrounded by osteopenic bone. Avascular necrosis causes hyperemia and resorption of bone. The resorption does not take place in necrotic bone because of the lack of a vascular supply, and so it appears radiopaque, whereas the bone surrounding the necrotic bone becomes osteopenic and radiolucent.

The sclerotic rim of a bone infarct is also enhanced by an attempted healing process in which new bone forms on the surface of necrotic trabeculae, a process known as “creeping substitution.” This gives a typical sclerotic picture of the talus.

MRI is the most sensitive technique for detecting osteonecrosis. A characteristic radiographic pattern is seen with osteonecrosis of the talus starting with talar dome opacity, followed by deformity and, in severe cases, articular collapse and bone fragmentation.¹⁷

The radiograph in our patient’s case is not consistent with features of rheumatoid arthritis or traumatic fracture of the talus. In plantar fasciitis, radiographs are used to rule out other pathologies of the foot, and the only finding may be a bone spur seen at the site of pain. The bone spur is not the cause of pain in plantar fasciitis but may be a result of the plantar fasciitis itself.

Therefore, avascular necrosis secondary to Gaucher disease is most likely the immediate cause of her ankle pain.

■ THE COURSE OF TREATMENT

The patient is started on enzyme replacement therapy with taliglucerase alfa (see discussion of enzyme replacement below). For the ankle pain, conservative management is prescribed, with application of a splint and a boot.

After 4 months of conservative management, radiography (**Figure 2**) and magnetic resonance imaging (**Figure 3**) show progressive deterioration of the talus body, and her ankle pain has worsened. A 6-week trial of an ankle brace also proves futile. Her pain continues to worsen and is not controllable with high doses of pain medication. She requests below-the-knee amputation.

Given the complexity of this patient’s medical condition, fusion of the ankle and hindfoot—which in some patients is preferable to amputation—is not considered because of her extensive bone involvement and ongoing thrombocytopenia, which would impede healing after the procedure. Below-the-knee amputation is performed without complications.

Study of the specimen after amputation reveals talar bone necrosis and bone marrow infiltration by foamy macrophages, consistent with Gaucher disease (**Figures 4–6**).

MRI is the most sensitive imaging test for detecting osteonecrosis

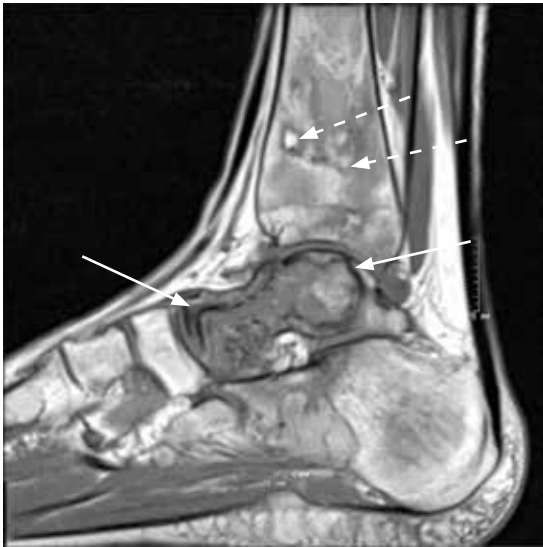

FIGURE 3. On sagittal T1-weighted magnetic resonance imaging, the serpentine black line indicates avascular necrosis in the talar head, neck, and body (solid arrows). Found incidentally were smaller foci of avascular necrosis in the distal tibial metaphysis and epiphysis (dashed arrows).

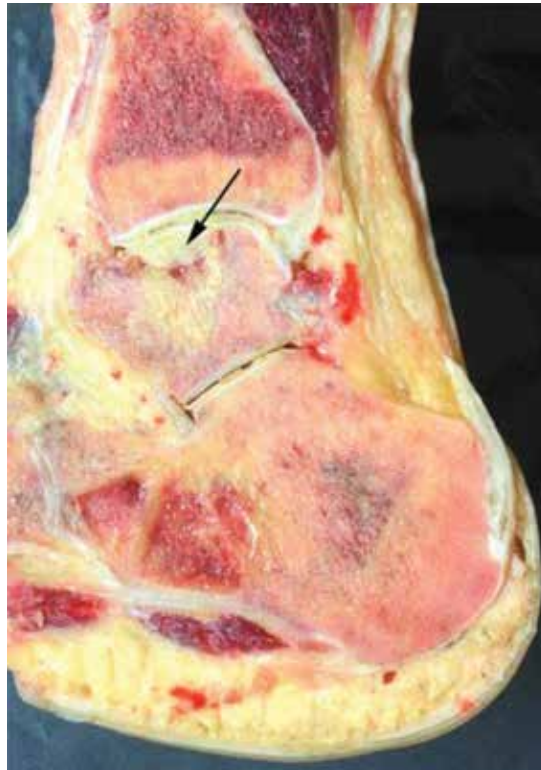

FIGURE 4. A sagittal section after amputation shows the collapsed dome of the talus and bone necrosis (arrow.)

GAUCHER DISEASE

Pharmacologic treatments, effective only for type 1 Gaucher disease, target hepatosplenomegaly, cytopenia, and bone manifestations. Two approaches are enzyme replacement therapy—ie, to replace the defective enzyme—and substrate reduction therapy—ie, to reduce the production and thus the accumulation of glucocerebroside. Enzyme replacement is the first choice of therapy; substrate reduction is reserved for patients unable to tolerate enzyme replacement therapy.

Enzyme replacement

Current drugs for enzyme replacement therapy are imiglucerase, taliglucerase alfa, and velaglucerase alfa. The drugs are given by intravenous infusion over 1 to 2 hours in an outpatient clinic or office every 2 weeks.

These drugs are extremely expensive. Currently, the estimated cost of therapy for 1 year would be \$432,978 for imiglucerase, \$324,870 for taliglucerase alfa, and \$368,550 for velaglucerase alfa. (The estimated costs are for 1 year of treatment for a 70-kg patient at 60 U/kg every 2 weeks.)¹⁸ Taliglucerase alfa is less

expensive than the other two because it is plant-derived and thus can be more readily produced on a large scale.¹⁹

Substrate reduction

Current drugs for substrate reduction therapy are eliglustat and miglustat. They are given orally. Eliglustat is the first oral drug approved as a first-line treatment for Gaucher disease.²⁰ Miglustat is approved only for mild to moderate disease when enzyme replacement fails or is not tolerated.

Patients can develop antibodies to any of the enzyme replacement drugs. It is not known whether this antibody response differs among the three drugs.²¹

Avascular necrosis of bone can occur in many clinical settings especially after a fracture, particularly of the head of the femur, which leads to interruption of blood supply to the area. Patients with sickle cell disease, those on corticosteroids or bisphosphonates (the latter causing osteonecrosis of the jaw), and those who have pancreatitis or human

Bone involvement is seen in about 75% of patients with type 1 Gaucher disease

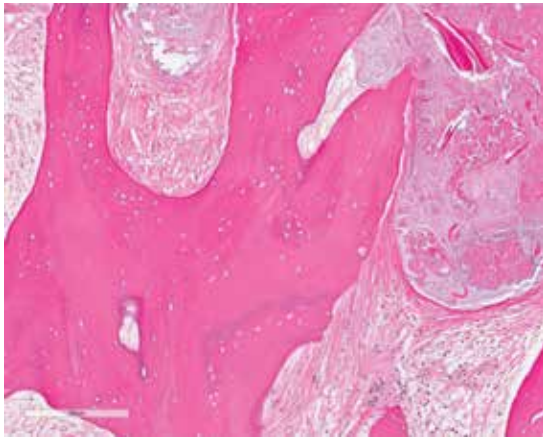


FIGURE 5. Histologic study after amputation shows necrotic bone with absent nucleus (hematoxylin and eosin, $\times 10$).

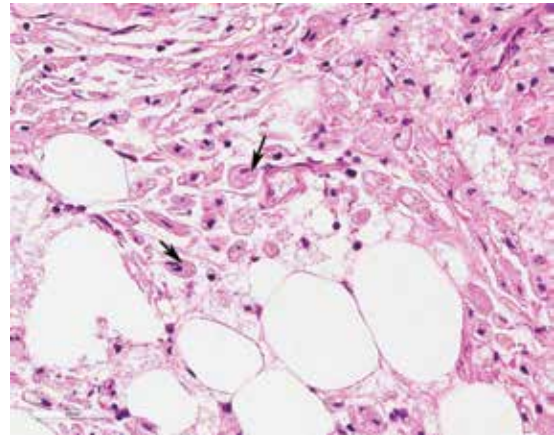


FIGURE 6. Histologic study under larger magnification shows "foamy macrophages" (arrow) filled with glycolipids, consistent with Gaucher disease (hematoxylin and eosin, $\times 100$).

immunodeficiency virus infection are more prone to this bone complication.

In Gaucher disease, osteonecrosis is associated with splenectomy and severe disease and tends to occur at a younger age than in patients with other diagnoses.⁸ The plasma chitotriosidase activity and pulmonary and activation-regulated chemokines (PARC/CCL18), which are 10 to 40 times higher than normal in symptomatic patients with Gaucher disease, can be used as a biomarker of disease activity.⁸ Only plasma chitotriosidase is clinically available and used on a routine basis.

Bone involvement is seen in approximately 75% of the patients with type 1 Gaucher disease,²² and osteonecrosis is a severe form of bone involvement. Monitoring of patients for bone involvement is recommended. Enzyme replacement therapy for Gaucher disease needs to be started even if visceral disease is absent if the patient has evidence of bone involvement in the form of avascular necrosis.⁷ Prospective studies have shown that enzyme replacement therapy reduces the incidence of osteonecrosis.²³

■ FOLLOW-UP MANAGEMENT OF OUR PATIENT

Avascular necrosis in Gaucher disease more typically involves the hips and shoulders. In the case of our patient, the talus was the most affected bone. Other contributing factors may have been the use of steroids as a premedication (often unnecessary) for her enzyme replacement therapy, as well as the coexistent scleroderma.²⁴

The decision to switch from imiglucerase, to which she developed antibodies, to taliglucerase was made in the hope that the antibodies would not cross-react. After she started taliglucerase, her complete blood count values improved steadily. She did not require transfusions for more than 1 year. Her platelet count rose to $90 \times 10^9/L$, and her hemoglobin to 12 g/dL.

A multidisciplinary approach with regular monitoring and appropriate initiation of therapy is necessary to prevent disastrous complications in patients with Gaucher disease. ■

■ REFERENCES

1. Lee DM, Weinblatt ME. Rheumatoid arthritis. *Lancet* 2001; 358:903–911.
2. Fleming A, Crown JM, Corbett M. Early rheumatoid disease. I. Onset. *Ann Rheum Dis* 1976; 35:357–360.
3. Grabowski GA, Andria G, Baldellou A, et al. Pediatric non-neuronopathic Gaucher disease: presentation, diagnosis, and assessment. Consensus statements. *Eur J Pediatr* 2004; 163:58–66.
4. Rodrigue SW, Rosenthal DI, Barton NW, Zurakowski D, Mankin HJ. Risk factors for osteonecrosis in patients with type 1 Gaucher's disease. *Clin Orthop Relat Res* 1999; May (362):201–207.
5. Lee RE. The pathology of Gaucher disease. *Prog Clin Biol Res* 1982; 95:177–217.
6. Cox TM, Aerts JM, Belmatoug N, et al. Management of non-neuronopathic Gaucher disease with special reference to pregnancy, splenectomy, bisphosphonate therapy, use of biomarkers and bone disease monitoring. *J Inheret Metab Dis* 2008; 31:319–336.
7. Khan A, Hangartner T, Weinreb NJ, Taylor JS, Mistry PK. Risk factors for fractures and avascular osteonecrosis in type 1 Gaucher disease: a study from the International Collaborative Gaucher Group (ICGG) Gaucher Registry. *J Bone Miner Res* 2012; 27:1839–1848.

8. Deegan PB, Pavlova E, Tindall J, et al. Osseous manifestations of adult Gaucher disease in the era of enzyme replacement therapy. *Medicine (Baltimore)* 2011; 90:52–60.
9. Weinstein RS. Glucocorticoid-induced osteonecrosis. *Endocrine* 2012; 41:183–190.
10. Compston J. Management of glucocorticoid-induced osteoporosis. *Nat Rev Rheumatol* 2010; 6:82–88.
11. Van Staa TP, Laan RF, Barton IP, Cohen S, Reid DM, Cooper C. Bone density threshold and other predictors of vertebral fracture in patients receiving oral glucocorticoid therapy. *Arthritis Rheum* 2003; 48:3224–3229.
12. Kanis JA, Johnell O, Oden A, et al. The risk and burden of vertebral fractures in Sweden. *Osteoporos Int* 2004; 15:20–26.
13. Seguro LP, Rosario C, Shoenfeld Y. Long-term complications of past glucocorticoid use. *Autoimmun Rev* 2013; 12:629–632.
14. Weinstein RS. Glucocorticoid-induced osteoporosis and osteonecrosis. *Endocrinol Metab Clin North Am* 2012; 41:595–611.
15. Cooper C, Steinbuch M, Stevenson R, Miday R, Watts NB. The epidemiology of osteonecrosis: findings from the GPRD and THIN databases in the UK. *Osteoporos Int* 2010; 21:569–577.
16. Mulfinger GL, Trueta J. The blood supply of the talus. *J Bone Joint Surg Br* 1970; 52:160–167.
17. Pearce DH, Mongiardi CN, Fornasier VL, Daniels TR. Avascular necrosis of the talus: a pictorial essay. *Radiographics* 2005; 25:399–410.
18. In brief: Taliglucerase (Elelyso) for Gaucher disease. *Med Lett Drugs Ther* 2012 Jul 9; 54(1394):56.
19. Hollak CE. An evidence-based review of the potential benefits of taliglucerase alfa in the treatment of patients with Gaucher disease. *Core Evid* 2012; 7:15–20.
20. Poole RM. Eliglustat: first global approval. *Drugs* 2014; 74:1829–1836.
21. Bennett LL, Mohan D. Gaucher disease and its treatment options. *Ann Pharmacother* 2013; 47:1182–1193.
22. Germain DP. Gaucher's disease: a paradigm for interventional genetics. *Clin Genet* 2004; 65:77–86.
23. Sims KB, Pastores GM, Weinreb NJ, et al. Improvement of bone disease by imiglucerase (Cerezyme) therapy in patients with skeletal manifestations of type 1 Gaucher disease: results of a 48-month longitudinal cohort study. *Clin Genet* 2008; 73:430–440.
24. Rennie C, Britton J, Prouse P. Bilateral avascular necrosis of the lunate in a patient with severe Raynaud's phenomenon and scleroderma. *J Clin Rheumatol* 1999; 5:165–168.

ADDRESS: Alan E. Lichtin, MD, Department of Hematologic Oncology and Blood Disorders, R35, Cleveland Clinic, 9500 Euclid Avenue, Cleveland, OH 44195; e-mail: lichtia@ccf.org



Dr. Roizen's Preventive and Integrative Medicine Conference

Focus: How You Can Affect Optimal Aging by Altering Inflammation

December 4 – 6, 2015
Las Vegas

TO SIGN UP FOR EMAIL UPDATES:
ccfcme.org/GetWell

What you will learn:

- The key concept about optimal aging that Dr. Roizen learned from 56 million people who took the RealAge® test
- Smart tips about changing your patient's microbiomes
- How you can affect the role of the GI tract in chronic disease
- How to understand the clinical utility of TMAO testing for monitoring cardiometabolic risk
- The tricks about measuring your microbiome's effects
- Why some choose a plant-based diet and why you may not
- What supplements do you need with a plant-based diet to decrease inflammation and improve your microbiome
- What to do for your microbiome to promote weight loss and how it inhibits aging
- Clarify how a systems-based approach can effectively treat illness and promote wellness

This activity has been approved for
AMA PRA Category 1 Credit™.



PHOTO CREDIT: LAS VEGAS NEWS BUREAU