

THE CLINICAL PICTURE

SHELLEY MAITHEL, BA

School of Medicine,
University of California, Irvine

ALEX K. DUONG

School of Medicine,
University of California, Irvine

JONATHAN ZHANG, MD

School of Medicine,
University of California, Irvine

DOUGLAS L. NGUYEN, MD

Assistant Clinical Professor,
Comprehensive Digestive Disease Center,
Division of Gastroenterology and Hepatology,
University of California, Irvine

An unusual cause of vitamin B₁₂ and iron deficiency

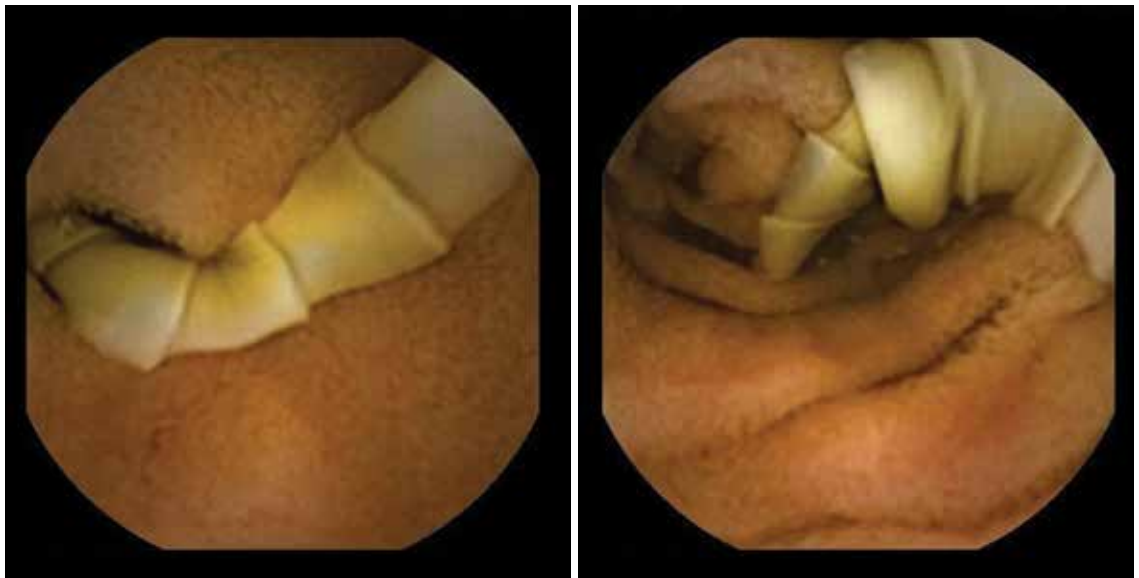


FIGURE 1. Capsule endoscopy confirmed the presence of flat segments of a tapeworm in the distal duodenum.

A 76-YEAR-OLD WOMAN visiting from Ethiopia presented for further evaluation of concomitant iron and vitamin B₁₂ deficiency anemia that had developed over the previous 6 months. During that time, she had complained of ongoing fatigue and increasing paresthesias in the hands and feet.

At presentation, her hemoglobin concentration was 7.8 g/dL (reference range 11.5–15), with a mean corpuscular volume of 81.8 fL (81.5–97.0). These values were down from her baseline hemoglobin of 12 g/dL and corpuscular volume of 85.8 recorded more than 1 year ago. Serum studies showed an iron concentration of 21 µg/dL (37–170), ferritin 3 ng/mL (10–107), and percent saturation of transferrin 5% (20%–55%). Also noted was a low vitamin B₁₂ level of 108 pg/mL (180–1,241 pg/mL). She had no overt signs of gastrointestinal blood loss. She did not re-

doi:10.3949/ccjm.82a.14151

port altered bowel habits or use of nonsteroidal anti-inflammatory medications.

Given her country of origin, she was sent for initial stool testing for ova and parasites, which was unrevealing.

She underwent esophagogastroduodenoscopy and colonoscopy, which revealed no underlying cause of her iron deficiency or vitamin B₁₂ insufficiency. But further evaluation with capsule endoscopy showed evidence of a tapeworm in the distal duodenum (**Figure 1**).

She was given praziquantel in a single oral dose of 10 mg/kg. Repeat stool culture 1 month later showed no evidence of tapeworm infection, and at follow-up 3 months later, her hemoglobin had recovered to 13.2 g/dL with a corpuscular volume of 87.6 fL and no residual vitamin B₁₂ or iron deficiency. She reported complete resolution of fatigue and of paresthesias of the hands and feet.

■ *DIPHYLLOBOTHRIUM LATUM*

The appearance on capsule endoscopy indicated *Diphyllobothrium latum* as the likely parasite. This tapeworm is acquired by ingesting undercooked or raw fish. Infection is most common in Northern Europe but has been reported in Africa.¹

As it grows, the tapeworm develops chains of segments and can reach a length of 1 to 15 meters.¹ In humans, it typically resides in the small intestine. Most patients are asymptomatic or have moderate nonspecific symptoms such as abdominal pain and diarrhea. A key differentiating aspect of *D latum* infection is vitamin B₁₂ deficiency caused by consumption of the vitamin by the parasite, as well as by parasite-mediated dissociation of the vitamin B₁₂-intrinsic factor complex, thus making the vitamin unavailable to the host.

Up to 40% of people infected with *D latum* develop low levels of vitamin B₁₂, and 2% develop symptomatic megaloblastic anemia.²

■ REFERENCES

1. **Schantz PM.** Tapeworms (cestodiasis). *Gastroenterol Clin North Am* 1996; 25:637–653.
2. **Scholz T, Garcia HH, Kuchta R, Wicht B.** Update on the human broad tapeworm (genus *Diphyllobothrium*), including clinical relevance. *Clin Microbiol Rev* 2009; 22:146–160.
3. **Stanciu C, Trifan A, Singeap AM, Sfarti C, Cojocariu C, Luca M.** *Diphyllobothrium latum* identified by capsule endoscopy—an unusual cause of iron-deficiency anemia. *J Gastrointest Liver Dis* 2009; 18:142.
4. **Soga K, Handa O, Yamada M, et al.** In vivo imaging of intestinal helminths by capsule endoscopy. *Parasitol Int* 2014; 63:221–228.
5. **Drugs for Parasitic Infections.** 3rd edition. Treatment guidelines from the Medical Letter 2010. The Medical Letter, Inc., New Rochelle, NY.

Iron deficiency anemia is uncommon but has been reported.³ In our patient, the concomitant iron deficiency was probably secondary to involvement of the duodenum, where a significant amount of dietary iron is absorbed.

The diagnosis is typically established by stool testing for ova and parasites. When stool samples do not reveal a cause of the symptoms, as in this patient, endoscopy can be used. Capsule endoscopy has not been widely used in the diagnosis of intestinal helminth infection, although reports exist describing the use of capsule endoscopy to detect intestinal parasites. Notably, as in this case, intestinal parasite infection is occasionally found during investigations of anemia and vitamin deficiencies of unknown cause.⁴

As in our patient, treatment of infection with this species of tapeworm typically involves a single oral dose of praziquantel; this off-label use has been shown to lead to resolution of symptoms in nearly all patients treated.⁵ ■

ADDRESS: Douglas L. Nguyen, MD, Comprehensive Digestive Disease Center, Division of Gastroenterology and Hepatology, University of California, School of Medicine Irvine, 101 The City Drive, Orange, CA 92868; e-mail: douglaln@uci.edu

CME CREDIT TEST

Visit WWW.CCJM.ORG
Test your knowledge
of clinical topics and earn
AMA PRA Category 1 Credit™

