

# Postoperative Patient Suddenly Worsens

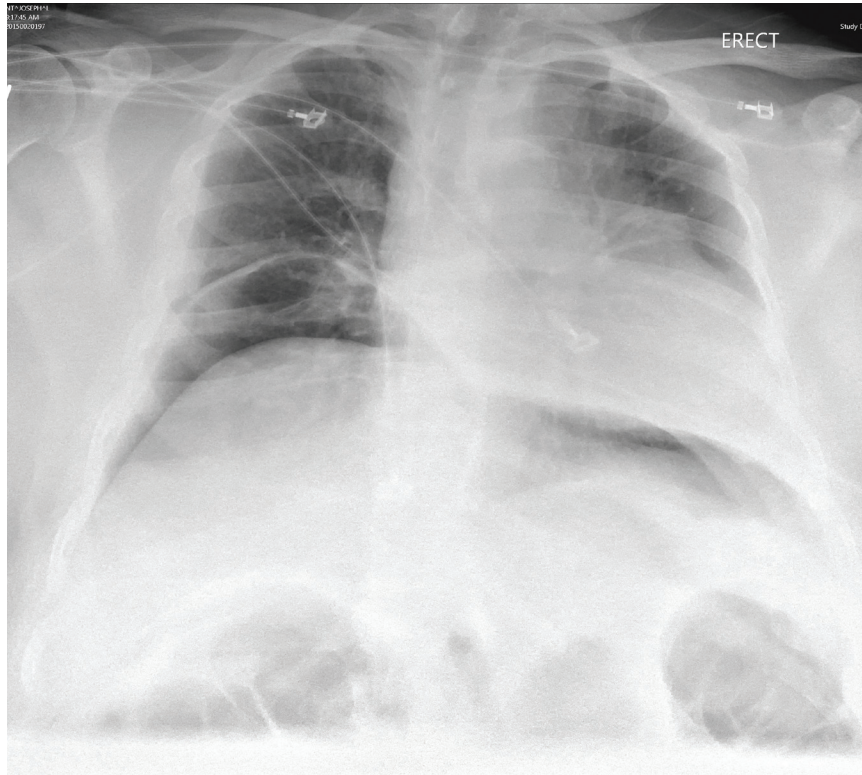
**A** 55-year-old man undergoes an elective craniotomy for tumor resection, with uneventful preoperative and intraoperative stages. Immediately postoperative, however, he experiences seizures. Noncontrast CT of the head is negative except for postoperative changes.

The patient is placed in the ICU for close monitoring. He is slowly improving when, on the fifth postoperative day, tachypnea and dyspnea are observed.

The patient is afebrile. His blood pressure is 116/70 mm Hg; pulse, 90 beats/min; respiratory rate, 30 breaths/min; and O<sub>2</sub> saturation, 98%.



A stat portable chest radiograph is obtained. What is your impression?  
see answer on page 22 >>



**Nandan R. Hichkad, PA-C, MMSc**, practices at the Georgia Neurosurgical Institute in Macon.

## MALPRACTICE CHRONICLE

which negligence was obvious to a layperson: for example, instruments left in patients or amputation of the wrong leg—the thing that “speaks for itself.” Newer evolution of the doctrine is problematic when extended to cases in which expert testimony should be required to demonstrate the standard of care and the defendant’s breach of it. When courts are willing to extend the doctrine, the plaintiff is awarded the presumption of negligence, which the defendant(s) must now come forward to rebut. For example, in a 2010 case in Illinois, a jury re-

turned a \$3.6 million verdict following the death of a 2-year-old who had had a seizure. The child’s seizure was reportedly controlled, but he was allegedly hypoventilated while undergoing CT and unfortunately died. The plaintiff was permitted to invoke the doctrine of *res ipsa loquitur* and was allowed the presumption that medical negligence was responsible for the outcome.

Unlike the surgical sponge left in a patient, matters of central nervous system status, monitoring during CT, airway and ventilation status, hypoxemia, and

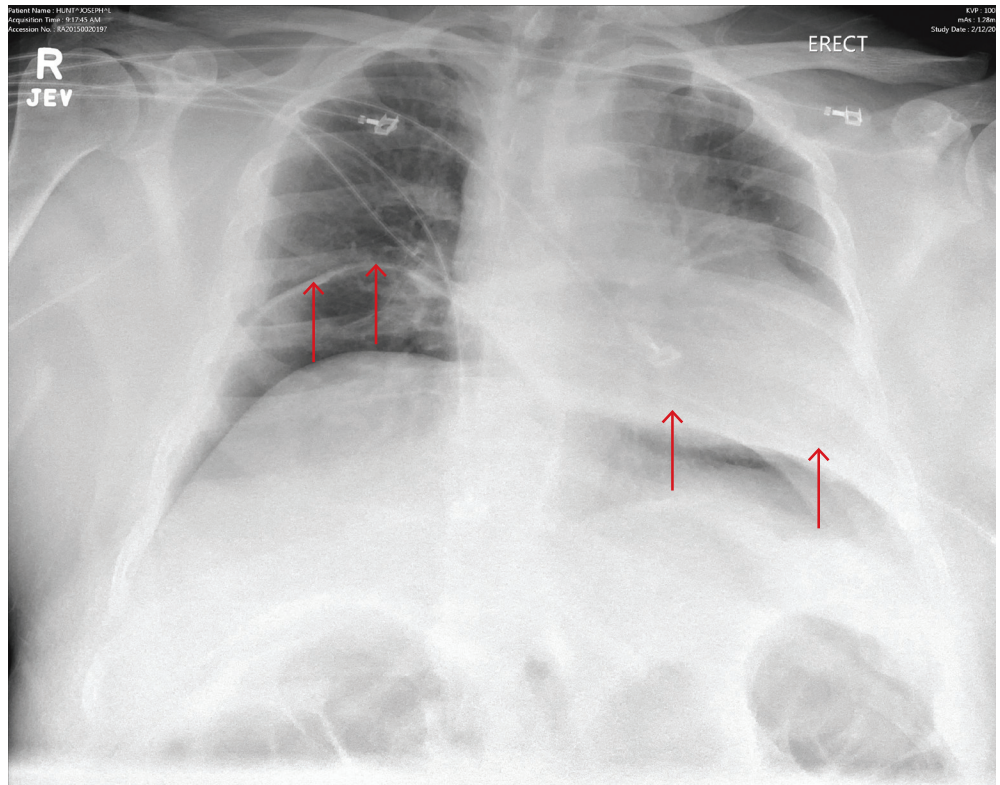
postictal states are not within the experience of the typical juror. The negligent “thing” is not a sponge that “speaks for itself,” but a course of actions that requires expert testimony precisely because it does not “speak for itself.” In cases in which an injury is beyond the average juror’s realm of experience, courts should require the plaintiff to prove her case. The doctrine should not “evolve” to excuse a plaintiff from the burden of producing evidence and persuading a jury. This forms the foundation of our civil law system. —DML **CR**

>> continued from page 15

### ANSWER

The radiograph demonstrates bilateral elevated diaphragm with a moderate amount of visible free air. With no history of recent abdominal procedures, the primary concern is a perforated viscus.

Urgent surgical consultation, as well as CT of the abdomen and pelvis, was obtained. The imaging confirmed the free air but provided no clear etiology. The patient underwent emergent laparotomy later that day and was found to have a perforated colon. **CR**



## ENDOCRINECONSULT

tory of thyroid disease

- Are older than 30
- Demonstrate symptoms of thyroid dysfunction
- Have goiter
- Are TPO-antibody positive
- Have type 1 diabetes or other autoimmune disorders
- Have a history of miscarriage or preterm delivery
- Have a history of head or neck radiation or thyroid surgery
- Are morbidly obese (BMI > 40)
- Use amiodarone or lithium or were exposed to iodinated radiologic contrast
- Are infertile
- Live in an area with moderate to severe iodine insufficiency.<sup>2,3</sup>

Rationale for targeted screen-

ing of asymptomatic women: Large-scale research has not demonstrated significantly better outcomes in those with subclinical hypothyroidism who receive treatment.<sup>7</sup> Small studies<sup>2</sup> have demonstrated improved fetal outcomes when subclinical hypothyroidism is treated, but for large bodies (eg, the US Preventive Services Task Force) to recommend screening, a clear improvement in health outcomes must be established via controlled studies. Future research should evaluate the effect of treating subclinical hypothyroidism during pregnancy.

### REFERENCES

1. Ballabio, M, Poshychinda M, Ekins RP. Pregnancy-induced changes in thyroid function: role of

human chorionic gonadotropin as putative regulator of maternal thyroid. *J Clin Endocrinol Metab.* 1991;73(4):824.

2. The Endocrine Society. Management of thyroid disease in pregnancy and postpartum. *J Clin Endocrinol Metab.* 2012;97:2543–2565.
3. Stagnaro-Green A, Abalovich M, Alexander E, et al. Guidelines of the American Thyroid Association for the diagnosis and management of thyroid disease during pregnancy and postpartum. *Thyroid.* 2011;21(10):1081-1125.
4. Alexander EK, Marqusee E, Lawrence J, et al. Timing and magnitude of increases in levothyroxine requirements during pregnancy in women with hypothyroidism. *N Engl J Med.* 2004;351:241-249.
5. Negro R, Formoso G, Mangieri T, et al. Levothyroxine treatment in euthyroid pregnant women with autoimmune thyroid disease: effects on obstetrical complications. *Clin Endocrinol Metab.* 2006;91(7):2587-2591.
6. Cooper DH. Antithyroid drugs. *N Engl J Med.* 2005;352:905-917.
7. American College of Obstetricians and Gynecologists. Routine thyroid screening not recommended for pregnant women. *J Obstet Gynecol.* 2007;110:959-960.