

THE CLINICAL PICTURE

STEPHANIE SAED, BS
Cleveland Clinic; Northeast Ohio
Medical University, Rootstown, OH

MARA WEINSTEIN VELEZ, MD
Department of Dermatology, Cleveland Clinic

KENNETH J. TOMECKI, MD
Department of Dermatology, Cleveland Clinic

ANTHONY P. FERNANDEZ, MD, PhD
Director of Medical and Inpatient Dermatology,
Department of Dermatology, and Department of
Anatomic Pathology, Cleveland Clinic

Parvovirus mimicking acute HIV infection

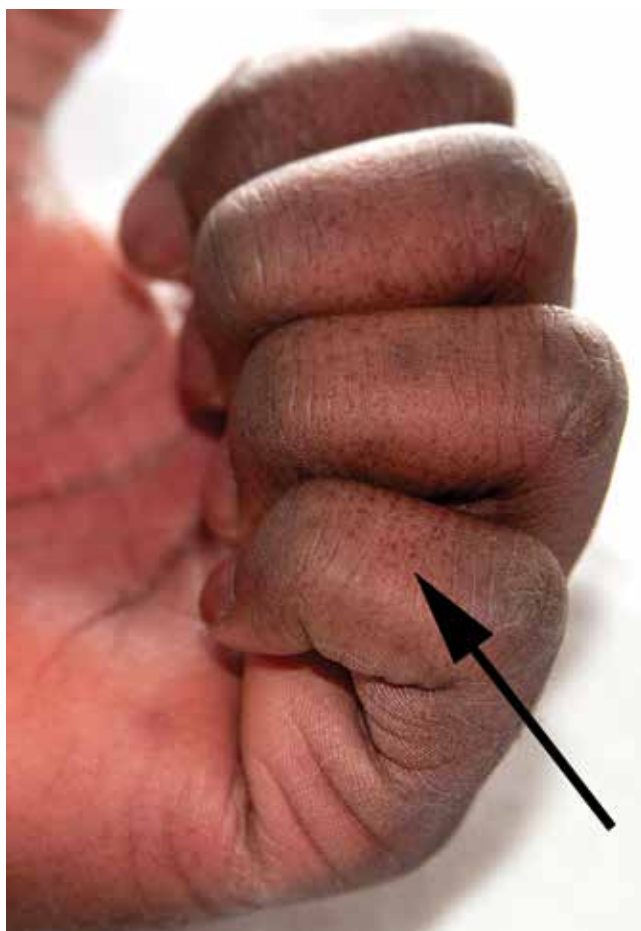


FIGURE 1. The rash affected the hands, as well as the face and back.

A 25-YEAR-OLD JAMAICAN MAN presented to the emergency department for evaluation of a rash on his face, back, and hands (**FIGURE 1**). He recalled a puncture injury after handling garbage at work. He denied recent travel, blood transfusions, or sick contacts. He was not aware of any recent arthropod bites. All

doi:10.3949/ccjm.82a.14141

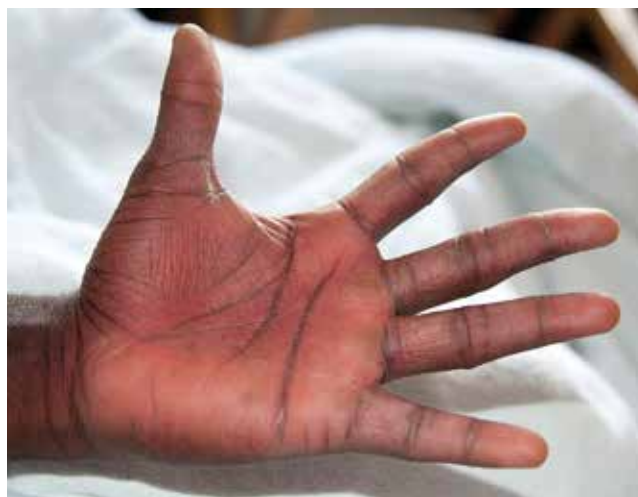

FIGURE 2. The patient had confluent erythema with petechiae on the palms.

standard vaccines including a tetanus booster were up to date.

Examination revealed edema of the hands and uvula. He was discharged with diphenhydramine and a short course of a systemic corticosteroid for presumed contact dermatitis.

He returned 4 days later with new symptoms, including sore throat, fever with a temperature of 103°F (39.4°C), oropharyngeal pain, dysphagia, dysuria, and purpura on the hands, abdomen, and legs. He was admitted to the hospital.

Examination revealed bright red confluent erythema of both legs extending to the lower abdomen, with petechiae on the palms (**FIGURE 2**), soles, toes, and fingers. Several small scrotal ulcers with well-defined borders were noted. Oral examination revealed white-yellow adherent plaques on the tongue and similar small ulcers on the lower lip and soft and hard palates.

A complete blood cell count revealed absolute lymphopenia, with a white blood cell count of $0.64 \times 10^9/L$

(reference range 1.0–4.8) and a neutrophil percentage of 78.9% (39%–68%). Other values were within normal limits, with a red blood cell count of $5.3 \times 10^{12}/L$ (3.9–5.5) and a platelet count of $161 \times 10^9/L$ (150–350). Serum liver enzymes were also within normal limits.

Treatment with intravenous fluids and intramuscular penicillin G was started empirically, pending a workup for infectious disease. Tests for syphilis immunoglobulin G (IgG), streptococci, anti-streptolysin O, Epstein-Barr virus, and human immunodeficiency virus (HIV) 1 and 2 were negative. The scrotal ulcers were swabbed, and culture and direct fluorescent antibody testing for cytomegalovirus and herpes simplex virus were negative. Urine testing for gonococcal and chlamydial infection was negative.

On the fifth day of hospitalization, the patient's condition was improving, but there was still no definitive diagnosis. Consultation with the inpatient dermatology team prompted testing for parvovirus B19 infection, based on the gloves-and-socks distribution of the purpura. Testing revealed a slightly elevated parvovirus B19 IgG titer (2.61) and a significantly elevated parvovirus B19 IgM titer (12.74), which confirmed acute parvovirus infection.

The patient's condition improved over several days with fluid administration, and he was discharged in good condition. He returned 1 week later for a follow-up appointment, at which time only superficial desquamation was noted in the areas previously affected by purpura.

■ PARVOVIRUS B19: NOT ONLY IN CHILDREN

Parvovirus B19 is responsible for the common childhood viral exanthem known as fifth disease.¹ However, although much less common, the virus can also affect young adults, precipitating a dermatosis referred to as gloves-and-socks syndrome characterized by purpura on the hands and feet,^{2,3} and with a higher incidence in the spring and summer.¹

Although papular-purpuric gloves-and-socks syndrome is characterized by purpura on

the hands and feet, the cheeks, oral mucosa, inner thighs, buttocks, and genitalia are affected in about 50% of patients.² In one report, in two-thirds of adult patients the presentation was caused by parvovirus B19 infection,⁴ but the syndrome has also been associated with Epstein-Barr virus, cytomegalovirus, human herpesvirus types 6 and 7, hepatitis B virus, rubella virus, and varicella zoster virus.⁴

Parvovirus B19 infection is commonly associated with systemic manifestations such as fever, fatigue, and lymphadenopathy, as well as swelling of the lips, cutaneous and mucosal ulcerations, polyarthritides, and petechiae involving the hard palate, the soft palate, or both.¹

The syndrome is self-limited and resolves within 1 to 2 weeks.¹

■ THE DIAGNOSTIC CHALLENGE

The differential diagnosis of the syndrome's gloves-and-socks presentation includes hand-foot-mouth disease, erythema multiforme, Henoch-Schönlein purpura, and Kawasaki disease,⁴ in addition to viral exanthems and sexually transmitted diseases. Our patient's fever, rash, and absolute lymphopenia focused attention on possible HIV infection, which caused the patient significant anxiety while awaiting the results of HIV testing. Heightened awareness of the cutaneous presentation of parvovirus B19 infection can help avoid unnecessary hospitalization and patient anxiety. ■

■ REFERENCES

1. Smith PT, Landry ML, Carey H, Krasnoff J, Cooney E. Papular-purpuric gloves and socks syndrome associated with acute parvovirus B19 infection: case report and review. *Clin Infect Dis* 1998; 27:164–168.
2. Harms M, Feldmann R, Saurat JH. Papular-purpuric "gloves and socks" syndrome. *J Am Acad Dermatol* 1990; 23:850–854.
3. Bagot M, Revuz J. Papular-purpuric "gloves and socks" syndrome: primary infection with parvovirus B19? *J Am Acad Dermatol* 1991; 25:341–342.
4. Gutermuth J, Nadas K, Zirbs M, et al. Papular-purpuric gloves and socks syndrome. *Lancet* 2011; 378:198.

ADDRESS: Stephanie Saed, BS, A61, Cleveland Clinic, 9500 Euclid Avenue, Cleveland, Ohio 44195; e-mail: ssaed@neomed.edu

By the fifth hospital, his condition had improved with IV fluids