

# Managing Common Dermatoses in Skin of Color

Marcelyn K. Coley, MD, and Andrew F. Alexis, MD, MPH

The demographics of the United States continue to evolve, with a growing proportion of the population consisting of non-Caucasian racial and ethnic groups. As darker skin types become more prevalent, so will the need to better understand their skin, the conditions that affect it, and optimal approaches for treatment. This population poses a special challenge for practitioners in part as a result of the sequelae often associated with the conditions in their own right—postinflammatory hyperpigmentation and scarring—and potential iatrogenic adverse effects that may occur during treatment. Through careful consideration of cultural, clinical, and therapeutic nuances, safe and effective management of common disorders in skin of color is achievable.

Semin Cutan Med Surg 28:63-70 © 2009 Elsevier Inc. All rights reserved.

As the demographics of the US population continue to evolve, understanding racial and ethnic variations in the presentation and management of skin disorders will be increasingly important for dermatologists. Several dermatologic concerns are more prevalent or have unique clinical features in populations with skin of color. Moreover, treatment options often vary according to a patient's skin type so that safe and effective outcomes are achieved. Variations in skin structure and function, as well as cultural practices and cultural standards of beauty, contribute to clinical and therapeutic differences in skin of color.

Most epidemiologic studies pertaining to the prevalence of dermatologic conditions in people of color have been practice surveys involving black patient populations. In a 1983 study by Halder et al,<sup>1</sup> acne, eczema, pigmentary disorders, seborrheic dermatitis, and alopecias were the most commonly diagnosed disorders in black patients in a university-affiliated private practice in Washington, DC. Alexis et al<sup>2</sup> showed similar results in 2007 in a New York City hospital-based practice survey, with acne vulgaris, as the most common diagnosis documented, followed by dyschromia, eczema/dermatitis, alopecia, and seborrheic dermatitis, respectively. In addition to the aforementioned diagnoses, disorders such as dermatosis papulosa nigra, pseudofolliculitis barbae, and keloids are also common concerns for which

patients of color seek dermatologic consultation. Here we review some of the common dermatologic concerns in patients with skin of color and their management.

## Acne Vulgaris

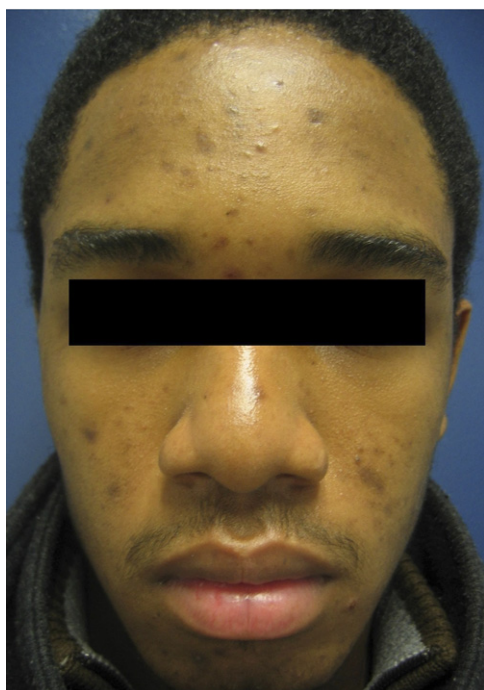
Acne vulgaris is a leading skin disorder in patient populations with skin of color, just as it is in the general population. In fact, acne was the most common diagnosis observed in multiple survey studies involving patients of color.<sup>1-6</sup> Although the etiology and treatment options are similar in all skin types, two potential consequences of acne—postinflammatory hyperpigmentation (PIH) and keloids—occur at significantly greater rates in darkly pigmented persons; therefore, treatment can be more challenging in this population. The sequelae may significantly reduce quality of life through their psychosocial impact. Discoloration and scarring, and the stigma associated, persist long after the acne lesions themselves have resolved. Moreover, PIH is often the primary motivation, rather than the acne itself, for dark-skinned individuals to seek medical attention (Fig. 1).<sup>7</sup>

Differences in the clinical presentation and exacerbating factors can be seen in skin of color. The most important and distinguishing clinical feature of acne in skin of color is the presence of associated PIH. A survey by Taylor et al<sup>8</sup> reported a high incidence of PIH in black, Hispanic, and Asian patients, where 65%, 53%, and 47%, respectively, had acne and acne-related hyperpigmented macules. The high prevalence of PIH is attributed to the increased lability of melanocytes in darkly pigmented skin.<sup>9</sup> Inflammation or trauma triggers an increase in melanogenesis or a release of melanin from labile melanocytes.<sup>9,10</sup> It has been reported that marked inflammation on histopathology (even in noninflammatory lesions—

Skin of Color Center, Department of Dermatology, St. Luke's-Roosevelt Hospital Center, New York, NY.

Dr Andrew Alexis has served as a speaker for Sanofi-Aventis, Galderma, and Stiefel. He has received honoraria from Medicis.

Address reprint requests to Andrew F. Alexis, MD, MPH, Skin of Color Center, Department of Dermatology, St. Luke's-Roosevelt Hospital Center, 1090 Amsterdam Avenue, Suite 11B, New York, NY 10025. E-mail: Andrew.alexis@columbia.edu.



**Figure 1** Acne vulgaris with PIH in a 17-year-old African-American male patient.

ie, comedones) may also contribute to the high prevalence of PIH.<sup>11</sup>

Common exacerbating factors in skin of color often are culturally accepted skin or hair care practices, such as occlusive skin products (eg, cocoa butter), hair pomades (eg, “hair grease”), and topical steroid-containing fade creams (used by some populations, especially in Africa, to lighten the complexion of the skin). Pomade acne is a type of acne that primarily affects individuals of African descent. To a lesser degree, it also has been seen in Hispanic patients, particularly men who use lubricating products on the scalp and facial hair.<sup>12</sup> The lesions are typically closed comedones on the forehead and along the anterior hairline and are associated with using pomades and oils in the hair. Pomades contain comedogenic combinations of high-melting hydrocarbons.<sup>13</sup> This form of acne can be remedied best if such products are avoided. Because of a change in product formulations and hair-care practices of African-Americans,<sup>14,15</sup> pomade acne is not as common today as it was in previous decades. In patients with pomade acne, less comedogenic hair emollients, such as those containing cyclomethicone or dimethicone, can be recommended.

## Treatment

Given the high prevalence and cosmetically disfiguring nature of PIH, early and aggressive intervention is warranted. However, because of the irritating nature of some acne treatments, it is important to balance aggressive treatment of acne with the risk of inducing PIH secondary to irritant contact dermatitis.

## Topical Therapy

Topical agents, such as retinoids and antimicrobials, are considered the first-line treatment in skin of color, much as in other ethnicities. In ethnic skin, topical retinoids remain the top choice.<sup>16,17</sup> Topical retinoids available in the United States include tretinoin, tazarotene, and adapalene, which have been shown to be effective in treatment of acne and the associated PIH.<sup>17-23</sup> With use of these agents, it is important to consider the potential risk of irritant contact dermatitis, which in itself may also result in PIH. To address this concern in patients of color, it is advisable to start with low concentrations and more tolerable formulations. Typically, the use of a cream vehicle is more tolerable than an alcohol-based gel, especially in dry/sensitive skin types.<sup>14</sup> However, newer aqueous-based gels as well as microsphere and crystalline formulations of topical retinoid gels are available and are well tolerated, effective options in this patient population. Another approach is alternate-day dosing, usually at night (eg, every other night), which can then be titrated up as tolerated over 4-6 weeks.

Topical antimicrobials, such as erythromycin and clindamycin, are commonly used and are effective in reducing levels of *Propionibacterium acnes*. A major concern with long-term use is development of antibiotic resistance. This resistance can be reduced by the use of benzoyl peroxide in conjunction with topical antibiotics.<sup>24</sup> Benzoyl peroxide formulations are important therapeutic modalities in the treatment of acne in patients with skin of color. Combination preparations, such as 5% benzoyl peroxide along with a topical antibiotic (ie, clindamycin or erythromycin) are useful for their antimicrobial and anti-inflammatory properties. A primary consideration with benzoyl peroxide, like that of topical retinoids, is minimizing irritation and drying effects that can potentially lead to the development of hyperpigmentation. Hence, the use of concentrations of  $\leq 5\%$  along with careful vehicle selection are strongly recommended.<sup>14</sup> In general, aqueous gels are better tolerated than alcohol-based gels.

Topical azelaic acid, 20% cream is also effective in managing acne in skin of color. It has been found to successfully reduce inflammatory and noninflammatory acne lesions in addition to decreasing hyperpigmentation via its inhibitory effects on tyrosinase.<sup>25,26</sup> Its efficacy has been reported to be comparable to that of tretinoin, 0.05% cream, BPO 5% gel, erythromycin, 2% ointment, and clindamycin, 1% gel.<sup>27</sup> It is generally well tolerated with a low potential for irritation; therefore, it may be an appropriate option for patients with sensitive skin or a history of PIH.<sup>14</sup> Efficacy may be enhanced by combining azelaic acid with other topical acne therapies.<sup>27</sup> Topical dapsone 5% gel has recently been approved in the US for the treatment of acne and may be particularly useful in skin of color patients given its anti-inflammatory properties.

## Adjunctive Therapy

The adjunctive use of depigmenting agents to improve PIH is commonly incorporated in the management of acne in skin of color. These agents include hydroquinone, azelaic acid, and

kojic acid. Hydroquinone actively blocks melanocyte pigment production via inhibition of tyrosine conversion to melanin. Ideally, hydroquinones are introduced after acne is under control. However, in practice they are often initiated sooner, typically as spot treatment applied with a cotton swab once to twice daily after the application of acne medication. Care must be taken because use could result in hypopigmentation of normal adjacent skin, producing a *halo effect*. This effect gradually resolves after discontinuation of hydroquinone. Azelaic acid when used as combination therapy for acne has also been successful. It also has effects on proliferating melanocytes and has been effective in reducing hyperpigmentation in melasma,<sup>8</sup> and therefore, has been used in other dyschromias.

Chemical peels, when limited to superficial peeling agents such as salicylic acid and glycolic acid, are effective and safe in darker skin types. Benefits of implementing chemical peels include the ability to treat existing primary and secondary lesions, the improvement of PIH, and the improved absorption of topical agents.<sup>28</sup> Liquid salicylic acid solution 20-30% applied to the face for 3-5 minutes<sup>28</sup> or a 30-50% buffered glycolic acid solution left in place for 2-4 minutes<sup>29</sup> have been effective. In one study by Grimes,<sup>30</sup> moderate-to-significant clearing of acne vulgaris occurred in 8 of 9 (89%) treated with a series of salicylic acid peels. Pretreatment with 4% hydroquinone is recommended by some authors to reduce post-peel hyperpigmentation in patients with skin types V-VI. A series of 3-6 treatments, approximately 4 weeks apart, is typically performed based on the severity of the areas to be treated. It is strongly recommended that topical retinoids be discontinued 1 week before the peel and restarted 5-7 days after the peel.

An important but often overlooked adjunctive measure in the treatment of acne is the use of sunscreen to prevent exacerbation of acne-associated PIH. Sunscreen (minimum SPF 15 with UVA and UVB protection) in combination with sun avoidance may be a successful and necessary adjunctive treatment in PIH.<sup>31</sup> The selection of a noncomedogenic sunscreen is important as to not exacerbate the primary condition. The vehicles rather than the UV-absorbing compounds themselves tend to be responsible for exacerbating acne. Therefore, patients should be instructed to look for sunscreens labeled as noncomedogenic.

A successful outcome is largely dependent on patient compliance and the clinician's ability to effectively choose treatment modalities that are agreeable to the patient. It is helpful to provide instructions both verbally and in writing to reinforce the regimen prescribed. In some patients, PIH and scarring are exacerbated by self-inflicted injury (eg, picking or scratching lesions). Counseling regarding the avoidance of manipulating acne lesions is an important step in the management of such patients.

## Pseudofolliculitis Barbae (PFB)

### Epidemiology

PFB is a common inflammatory follicular disorder characterized by papules and pustules localized to the beard and/or

neck. Also known as “ingrown hairs” or “razor bumps,” this condition primarily affects men who are of African ancestry (ie, African-Americans, Afro-Caribbeans, etc.), but more specifically affects those with curly, coarse hair. Although less common in women, it is often seen in hirsute women on the face/neck or in young women who practice hair removal (ie, waxing, plucking, or shaving) in the axilla or pubic regions. Generally, associated with shaving, PFB can occur in any hair-bearing area. Studies have identified a single nucleotide polymorphism, a disruptive Ala12Thr substitution in the 1A alpha-helical segment of the companion layer-specific keratin K6hf, as a genetic risk factor for the development of pseudofolliculitis barbae.<sup>32</sup> The prevalence ranges from 45% to 83% and is a leading concern among black US Army recruits.<sup>33-35</sup> A study done at the Skin of Color Center,<sup>36</sup> which surveyed 71 patients with PFB (41 female and 30 male subjects), showed an average age of onset of 22 years.

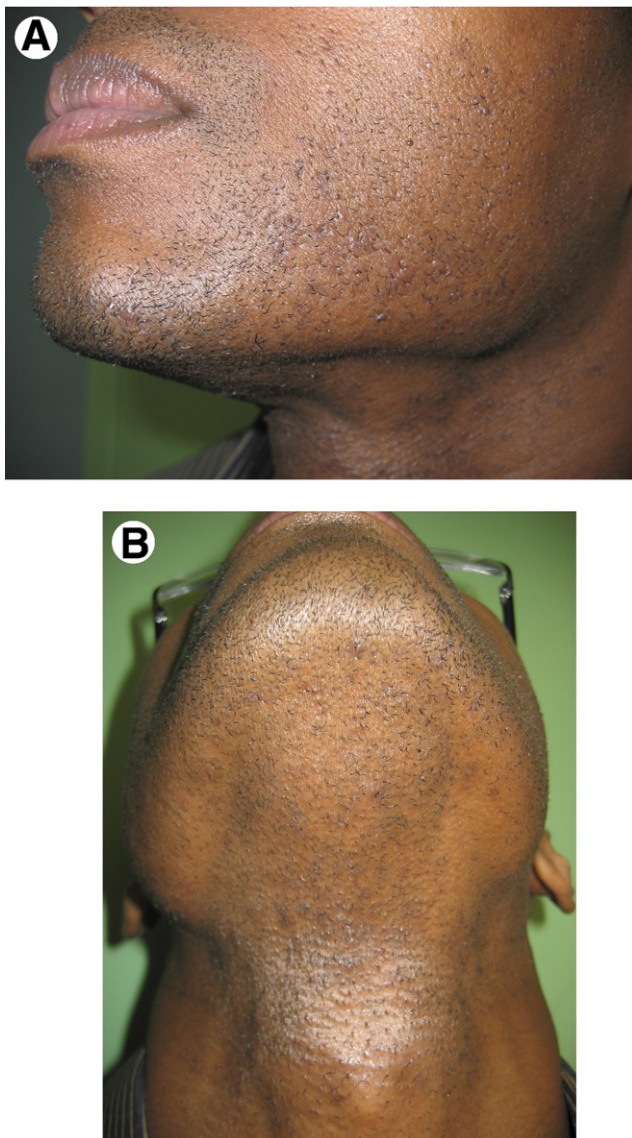
### Pathogenesis

The etiology is related to a foreign-body reaction surrounding an ingrown hair within the dermis. It is thought that the characteristics of the “black” hair type—a curved hair follicle and curly shaft—contribute to the hair's natural tendency to coil, producing tightly curled or “kinky” hair. This predisposes cut hair to reenter the skin, causing the subsequent inflammatory response. Cutaneous reentry of the hair shaft occurs by 2 mechanisms, extrafollicular and transfollicular penetration. In extrafollicular penetration, the shaved hair, now with a sharp edge, follows its natural curvature with the concavity towards the epidermis. As it grows out to the surface of the epidermis, it then reenters the skin. Transfollicular penetration is similar; however, because of the hair's natural tendency to coil, it pierces the follicle wall and reenters the dermis without ever exiting the epidermis.<sup>33,34,36</sup> Transfollicular penetration occurs when the skin is pulled taut during shaving, which causes newly cut hair to retract beneath the skin. This may also occur with plucking, which can leave hair fragments under the skin.<sup>34,36</sup> In either scenario, the hair penetrates the dermis, triggering a foreign-body inflammatory reaction resulting in the formation of papules and pustules.<sup>33,34</sup>

### Clinical Features

Clinically, PFB is characterized by follicular and perifollicular papules and pustules, often with associated hyperpigmentation. Embedded hair may be seen within papules. There may also be grooved, linear, depressed patterns in the skin that occur as the result of parallel hair growth.<sup>36</sup> Most commonly affected are the bearded area of the face, including the anterior neckline, submental and mandibular areas, chin, and cheeks (Fig. 2). Common sites in women include the axillae and pubis because they are the sites of most frequent hair removal. With the exception of secondary infection, cultures are usually sterile or contain normal flora.

In female patients with PFB secondary to hirsutism, it is important to rule out hormonal abnormalities, ie, polycystic ovarian syndrome or androgen-producing hormones.<sup>36,37</sup>



**Figure 2** Pseudofolliculitis barbae on the (A) chin, (B) submental, and neck regions in a 45-year-old African-American man.

Screening for hormonal abnormalities should include serum-free and total testosterone, dehydroepiandrosterone, and luteinizing hormone/follicle-stimulating hormone.<sup>37</sup>

### Psychosocial Impact

The appearance of these lesions can be very distressing to men and women affected with this condition and may cause a great deal of anxiety and self-consciousness about one's appearance. PIH may be a significant contributing factor to associated distress. It has been documented that as much as 90% of patients with PFB report having hyperpigmentation.<sup>36</sup> Additionally, PFB has led to significant social tension among African-American men in the Armed Forces because of the military grooming code requirement of a clean-shaven face. It left many African-American men faced with the dilemma of complying with the military code and suffering from PFB or not complying and facing discharge.<sup>35,36</sup> Despite

the significant impact on quality of life, men with PFB typically seek treatment later than women.<sup>36</sup>

### Treatment

Various treatment options have been employed in managing PFB. When personal and professional circumstances allow, avoidance of shaving altogether and growing a beard results in resolution of the condition within 4-8 weeks in most cases. This was demonstrated in a study by Strauss and Kligman, in which allowing the beard to grow for approximately 1 month resulted in spontaneous resolution of most papules.<sup>38</sup> Beard growth may not always be possible, however, not only because of occupational mandates for a clean-shaven appearance, but also because of personal choice, often dictated by social acceptability.

Nevertheless, when shaving avoidance is not an option, patient education and counseling about proper shaving techniques become important to controlling this condition. A key concept in preventing flares of PFB is to limit the closeness of the shave in these patients. Most men with PFB can control the condition by maintaining an optimal beard length of 0.5-1 mm.<sup>34-36,37</sup> Electric clippers are often recommended because they can be set to cut hair to the desired length.<sup>34</sup> If the proposed length of 0.5-1 mm or "stubble" is unacceptable and a closer shave is desired, use of a single blade razor, as opposed to a multiblade razor, is preferred. Multiblade razors tend to provide the closest shave but can facilitate transfollicular penetration and therefore may increase the risk for PFB. The first blade pulls the hair out of the follicle whereas the second blade cuts it, allowing retraction of the hair down into skin.<sup>36</sup> A single-blade razor, such as the Bump Fighter (American Safety Razor Company, Staunton, VA) may be considered.<sup>33,34,37,39</sup> This razor includes a polymer coating and a foil guard that keeps the blade edge slightly off the skin to prevent hair from being trimmed too short. This blade has been reported to significantly reduce the number of PFB lesions.<sup>36,40</sup> However, a recent unpublished study (sponsored by Gillette/Procter and Gamble, Cincinnati, OH) found that shaving with a five-blade razor did not exacerbate PFB.

Some dermatologists advocate preparing the area to be shaved with a warm moist towel to soften hair and washing with an antibacterial soap or benzoyl peroxide wash, along with use of shaving gel or foam for lubrication.<sup>37</sup> Patients should also be advised to shave in the direction of hair growth (ie, "with the grain"). The use of an adequately sharp blade is recommended to prevent the need for repeat passes over a given area with the blade. Patients should also be instructed against stretching or pulling the skin taut while shaving because as the skin is released, cut hair may fall beneath the skin's surface setting the stage for transfollicular penetration.<sup>34,36,38</sup> Another proposal is loosening of embedded hairs the night before shaving by brushing the beard or using a sterile needle with the aid of a magnifying mirror.<sup>37,40</sup> The latter requires great care to avoid inadvertently inducing trauma or introducing infection. This step is considered unnecessary by some because the hair eventually releases itself once the hair grows out further. This loop phenomenon,

described by Strauss and Kligman, occurs with extrafollicular penetration. A loop is formed when the hair reenters the skin. As the hair continues to grow out, the loop enlarges, serving as a way to release the hair. The hair will spontaneously release after a length of 1 cm.<sup>33,34,38</sup>

## Chemical Depilatories

Chemical depilatories, such as barium sulfide and calcium thioglycolate, have been used as an alternative to shaving. These substances, which exist in powder, paste, cream, and lotion forms, work by weakening the disulfide bonds in keratin so that hair is easily removed from the skin's surface. It is applied to a moistened beard and left in place for 5 or 15 minutes (ie, barium sulfide or calcium thioglycolate, respectively) and then scraped away with a blunt instrument (ie, wooden spatula) along with the weakened hair. This process leaves a blunt hair tip, making extrafollicular and transfollicular penetration less likely.<sup>36</sup> The skin is then rinsed and emollient applied to reduce irritation. Because these chemicals, if left on for prolonged periods, may cause potential irritant or allergic reactions, with resulting postinflammatory hyperpigmentation, it is important to follow directions precisely. A test patch may be performed to determine irritation potential before treatment.<sup>34</sup>

Eflornithine hydrochloride cream, 13.9% (Vaniqa, Skin Medica, Carlsbad, CA) is used to treat unwanted facial hair in women. It works by irreversible inhibition of skin ornithine decarboxylase, an enzyme in hair cell division, resulting in a decreased hair growth rate in the area applied.<sup>33,34,37</sup> Although not approved by the Food and Drug Administration for use in PFB, it has been used for the same purpose of decreasing hair growth in men with PFB. The cream is applied to the affected area of the face twice daily at least 8 hours apart and washed off at least 4 hours after application. Because it is not a depilatory, it is used in conjunction with other hair-removal methods. This point should be discussed clearly with patients to avoid unrealistic expectations. Additionally, the benefit of the therapy is only maintained with its continued use.

## Medical Management

Medical management includes use of an exfoliating agent, such as retinoids, low-potency corticosteroids, and topical antibiotics. Often a combination of therapies is used as opposed to monotherapy. Topical retinoids have been used with success (eg, topical 0.05% tretinoin or adapalene nightly), which help to alleviate the hyperkeratosis associated with repeated nicking of the follicular epithelium<sup>36</sup> and hyperpigmentation. Some also advocate use of low-to-mid potency topical corticosteroids (eg, desonide lotion) applied in the morning after shaving in place of commercial aftershave products.<sup>33,37</sup> Topical antimicrobials (clindamycin, erythromycin, benzoyl peroxide) may also be useful.<sup>41</sup> Although PFB is not a true folliculitis caused by bacterial infection, as implied by its name, it is thought that antimicrobials may reduce the colonization of bacteria that can aggravate the inflammation, leading to secondary infection,<sup>36</sup> and also have

anti-inflammatory effects.<sup>41</sup> As discussed in a previous section, a benzoyl peroxide wash may be added before shaving.

Depigmenting agents, such as hydroquinone 4%, azelaic acid, and kojic acid have been effective in treating the PIH that may result from the PFB lesions. Monthly intralesional corticosteroids are helpful in addressing resultant hypertrophic or keloidal scars.<sup>37</sup>

## Chemical Peels

Superficial chemical peels are generally well-tolerated and beneficial adjunctive therapies in PFB. In addition to its exfoliating effect, glycolic acid is a reducing agent. As a result, it may reduce sulfhydryl bonds in the hair shaft and lead to straighter hair growth that reduces the chance for reentry of the hair shaft into the epidermis.<sup>42</sup> Salicylic acid peels can offer comedolysis and lightening in cases complicated by PIH.<sup>37</sup> Reduced numbers of PFB lesions have been observed with both glycolic acid and salicylic acid peels.<sup>33</sup>

## Epilation

Electrolysis is generally not recommended in PFB. In addition to being painful and expensive, the use of electrolysis is often unable to ablate the curved or distorted hair follicle,<sup>43</sup> which may be distorted secondary to previous manipulation. It has been reported by several groups that electrolysis may actually exacerbate PFB because the needle used in electrolysis may not reach the hair bulbs of the curved follicle, perhaps promoting transfollicular penetration via relatively sharp hair fragments left in the skin.<sup>33,34,36</sup> Additionally, hyperpigmentation may result at the sites of needle insertion.<sup>36,43</sup> A blend method of electrolysis using galvanic and thermolytic currents has been effective.<sup>35,43</sup>

Surgical depilation has been described as an alternate method of hair removal.<sup>44</sup> This involves an incision into the subcutaneous tissue, extensive undermining, followed by skin inversion and removal of hair bulbs by scissor excision, extraction or electrodesiccation. A possible consequence of this procedure is keloid formation; surgical depilation is contraindicated in patients with predisposition to form keloids.<sup>40</sup>

Laser hair removal is the most recent advance in the management of PFB, with the development of lasers that can be used safely in darker skin types. The rationale behind its use is to reduce the amount of hair growth in affected areas, thus eliminating the potential for developing ingrown hairs. Studies have shown safe and effective use of laser epilation in darker skin types, including the diode (800-810),<sup>45,46</sup> and neodymium:yttrium aluminum garnet (Nd:YAG 1064 nm) lasers.<sup>46-48</sup>

Ross et al<sup>48</sup> reported the use of Nd:YAG 1064 nm coupled with contact cooling as an effective treatment option for PFB in skin types IV-VI, documenting significant reduction in hair and subsequent papule formation. Histologically, post-treatment biopsies revealed evidence of severe thermal hair bulb damage with epidermal preservation, supporting the concept that longer wavelengths better penetrate the skin, with less thermal damage to the epidermis.<sup>48</sup> Weaver and Sagal<sup>47</sup> also documented a decrease in the quantity of pap-

ules/pustules and hairs after 2 treatments in patients with active PFB using the long-pulse 1064 nm Nd:YAG laser on skin types V and VI. At a 3-month follow-up period, the mean papule/pustule percentage reduction was 75.9% as compared to the control at 28.6%. The most common side effects observed included transient hyperpigmentation, transient hypopigmentation, mild erythema and itching. Laser epilation is an effective treatment for PFB in those that desire long-term hair removal.

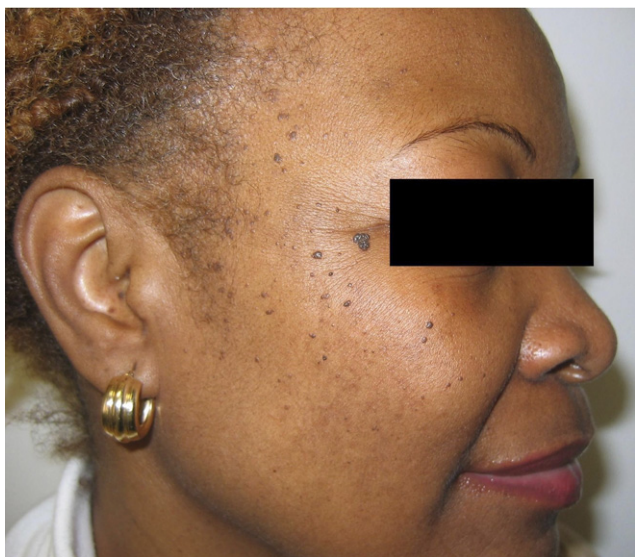## Dermatosis Papulosa Nigra (DPN)

### Epidemiology

DPN is a benign epithelial neoplasm, a probable variant of seborrheic keratosis that is found in darkly pigmented populations, most commonly in those of African descent.<sup>49</sup> The incidence has been reported to be 35-77% in the African-American population.<sup>50,51</sup> DPN tends to affect women more than men at a 2:1 ratio, usually increasing with age.<sup>51</sup>

### Clinical Features

The lesions are characterized by multiple hyperpigmented (dark brown to black) smooth papules measuring 1-5 mm in size. They typically occur symmetrically on the face, favoring the malar eminences, and may also involve the neck, chest, and upper back (Fig. 3). Although the etiology is not known, a genetic predisposition is thought to be a key factor. A positive family history is often found. However, because DPN tend to be distributed in sun-exposed areas, some authors have suggested that sun may play a role in the etiology—a hypothesis that has also been reported for seborrheic keratoses in some populations.<sup>52,53</sup> Niang et al<sup>54</sup> further comment on this hypothesis in a Senegalese study. In addition to observance of a prominence of lesions present in sun-exposed



**Figure 3** Dermatitis papulosa nigra in a 52-year-old African-American woman.

areas, it was also documented that 8 out of 10 patients who had profuse (100+) DPN had also practiced some form of artificial depigmentation with high potency topical corticosteroids in the past. Further studies are needed to investigate whether the sun or other nongenetic factors play any role in the pathogenesis.

### Role in Malignancy

No malignant transformation has been observed in DPN. This situation is unlike that of seborrheic keratoses and the rare sign of Leser-Trélat, characterized by a rapid increase in size and number of multiple seborrheic keratoses caused by malignancy, most commonly adenocarcinomas.<sup>55</sup> However, a case report from the University of Miami describes a middle-aged black woman with a history of DPN and anemia who reported an explosive progression in the number and size of biopsy-proven DPN lesions on the face, neck, and upper trunk, with back lesions in a “Christmas tree” pattern.<sup>56</sup> A subsequent colonoscopy revealed an ascending colon adenocarcinoma. It is unclear whether this could be another example of Leser-Trélat, if the DPNs observed were simply variants of seborrheic keratoses, or if this is a new, previously undescribed paraneoplastic entity unto itself.

### Treatment

Treatment is generally performed for aesthetic reasons, although some lesions may become irritated or pruritic. Particularly bothersome may be feelings of anxiety, fear of cancer, and/or professional concerns related to the appearance.<sup>54</sup> Options for treatment include light electrodesiccation, curettage, cryotherapy, and snip excision for pedunculated lesions. Intralesional anesthetics have been useful for cases where there are few lesions. However, topical anesthetics may be advantageous in more widespread involvement, with satisfactory levels of anesthesia for most patients when applied 30-60 minutes before the procedure.<sup>57</sup>

The most common adverse effect with any of the aforementioned treatments is potential for subsequent dyschromia—either hypo- or hyperpigmentation. Hypopigmentation can be particularly problematic after cryotherapy because melanocytes are particularly sensitive to freezing damage.<sup>58</sup> In the present author's (AFA) experience, light electrodesiccation is the safest and most effective treatment option for small DPNs. Care should be taken to minimize injury to normal skin beneath and adjacent to the lesion to prevent hyper- or hypopigmentation. For electrodesiccation of lesions that are 1 mm or less, an epilating needle can be used. In this author's opinion, electrodesiccated lesions are best left to fall off spontaneously (rather than using curettage post-electrodesiccation) to further minimize epidermal injury. Pedunculated lesions are safely and effectively removed by Gradle scissor excision under local anesthesia.

A study by Kauh et al<sup>50</sup> examined the efficacy of light curettage for DPN. Twenty patients (18 women, 2 men; 16 black, 4 Asian) with clinically diagnosed DPN were treated with “light abrasive curettage” to irritate, but not completely remove, the lesions. Minimal bleeding controlled with pres-

sure was common posttreatment. Good results were reported in 14 of 19 patients treated, with good (only minor pigment alteration) or excellent responses at 8 weeks. No evidence of scarring was seen in any patients treated. A prospective study by Niang et al<sup>54</sup> reported success with electrosurgery. Twelve Senegalese patients with DPN had lesions excised with fine-needle or fine-scissor electrosurgery after local anesthesia. Aesthetic results were evaluated over 6 weeks, with 60% of treated patients healing without sequelae at day 45. Dyschromia was the only documented adverse effect, seen in those who had practiced artificial depigmentation.

Laser treatment of DPN has also shown promise. Good results have been documented with use of the 532 diode laser.<sup>49</sup> Authors of recent reports have experienced success by using a long-pulsed 1064 nm Nd:YAG laser for the treatment of DPN. Schweiger et al<sup>49</sup> reports 2 cases of middle-aged African-American women with a long-standing history of DPN. In both cases, each lesion was treated with a double pulse from the Nd:YAG laser using a 3-mm spot size, fluence range of 145-155 J/cm<sup>2</sup> and a pulse duration of 20 milliseconds. At 2 months follow up, the treated areas had resolved with no pigmentary changes or scarring in approximately 90% and 70% of lesions treated in the 2 cases presented, respectively. Further studies will be necessary to corroborate these findings.

## Conclusions

Understanding the disease processes that affect patients with skin of color and the respective treatment options available will be increasingly important for US dermatologists. An added challenge is being mindful of the associated complexity and variation among the skin types within this group. However, through careful consideration of the clinical and therapeutic nuances in skin of color, it is possible to safely and effectively care for this population.

## References

- Halder RM, Grimes PE, McLaurin CI, et al: Incidence of common dermatoses in a predominantly black dermatologic practice. *Cutis* 32:378-380, 1983
- Alexis AF, Sergay AB, Taylor SC: Common dermatologic disorders in skin of color: A comparative practice survey. *Cutis* 80:387-394, 2007
- Taylor SC: Epidemiology of skin diseases in ethnic populations. *Dermatol Clin* 21:601-607, 2003
- Child FJ, Fuller LC, Higgins EM, et al: A study of the spectrum of skin disease occurring in a black population in south-east London. *Br J Dermatol* 141:512-517, 1999
- Arsouze A, Fitoussi C, Cabotin PP, et al: Presenting skin disorders in black afro-Caribbean patients: A multicenter study conducted in the Paris region. *Ann Dermatol Venereol* 135:177-182, 2008
- Dunwell P, Rose A: Study of the skin disease spectrum occurring in an Afro-Caribbean population. *Int J Dermatol* 42:287-289, 2003
- Taylor SC: Cosmetic problems in skin of color. *Skin Pharmacol Appl Skin Physiol* 12:139-143, 1999
- Taylor SC, Cook-Bolden F, Rahman Z, et al: Acne vulgaris in skin of color. *J Am Acad Dermatol* 46:S98-S106, 2002
- Grimes PE: Pigmentary disorders in blacks. *Dermatol Clin* 6:271, 1988
- Taylor SC: Skin of color: Biology, structure, function, and implications for dermatologic disease. *J Am Acad Dermatol* 46:S41-S62, 2002 (suppl)
- Halder RM, Holmes YC, Bridgeman-Shah S, et al: A clinicopathological study of acne vulgaris in black females. *J Invest Dermatol* 106:888, 1996
- Halder RM, Noothehi PK, Richards GM: Dermatological disorders and cultural practices: Understanding practices that cause skin conditions in non-Caucasian populations. *Skin Aging* 10:46-50, 2002
- Laude TA: Skin disorders in black children. *Curr Opin Pediatr* 8:381-385, 1996
- Callender VD: Acne in ethnic skin: Special considerations for therapy. *Dermatol Ther* 17:184-195, 2004
- Halder RM, Brooks HL, Caballero JC: Common dermatological diseases in pigmented skins, in Halder RM (ed): *Dermatology And Dermatological Therapy of Pigmented Skins*. Boca Raton, FL, Taylor & Francis, 2006, pp 17-39
- Leyden JJ: Topical treatment of acne vulgaris: Retinoids and cutaneous irritation. *J Am Acad Dermatol* 38:S1-S4, 1998
- Halder RM: The role of retinoids in the management of cutaneous conditions in blacks. *J Am Acad Dermatol* 39:S98-S103, 1998 (suppl 2)
- Bulengo-Ransby SM, Griffiths C, Kimbrough-Green CK, et al: Topical tretinoin (retinoic acid) therapy for hyperpigmented lesions caused by inflammation of the skin in black patients. *N Engl J Med* 328:1438-1443, 1993
- Grimes P, Callender V: Tazarotene cream for postinflammatory hyperpigmentation and acne vulgaris in darker skin: A double-blind, randomized, vehicle-controlled study. *Cutis* 77:45-50, 2006
- Czernielewski J, Poncet M, Mizzi F: Efficacy and cutaneous safety of adapalene in black patients versus white patients with acne vulgaris. *Cutis* 70:243-248, 2002
- Zhu XJ, Tu P, Zhen J, et al: Adapalene gel 0.1%: Effective and well tolerated in the topical treatment of acne vulgaris in Chinese patients. *Cutis* 68:55-59, 2001 (suppl 4)
- Thiboutot D, Arsonnaud S, Soto P: Efficacy and tolerability of adapalene 0.3% gel compared to tazarotene 0.1% gel in the treatment of acne vulgaris. *J Drugs Dermatol* 7:S3-S10, 2008 (suppl 6)
- Jacyk WK: Adapalene in the treatment of African patients. *J Eur Acad Dermatol Venereol* 15:37-42, 2001 (suppl 3)
- Leyden JJ: Current issues in antimicrobial therapy for the treatment of acne. *J Eur Acad Dermatol Venereol* 15:51-55, 2001 (suppl 3)
- Fitton A, Goa KL: Azelaic acid: A review of its pharmacological properties and therapeutic efficacy in acne and hyperpigmentary skin disorders. *Drugs* 41:780-798, 1991
- Hsu S, Quan LT: Topical antibacterial agents, in Wolverson SE (ed): *Comprehensive Dermatologic Drug Therapy*. Saunders, 2001, pp 473-496
- Webster G: Combination azelaic acid therapy for acne vulgaris. *J Am Acad Dermatol* 43:47-50, 2000
- Roberts WE: Chemical peeling in ethnic/dark skin. *Dermatol Ther* 17:196-205, 2004
- Burns RL, Prevost-Blank PL, Lawry MA, et al: Glycolic acid peels for postinflammatory hyperpigmentation in black patients. A comparative study. *Dermatol Surg* 23:171-174; discussion: 175, 1997
- Grimes PE: The safety and efficacy of salicylic acid chemical peels in darker racial-ethnic groups. *Dermatol Surg* 25:18-22, 1999
- Cayce KA, McMichael AJ, Feldman SR: Hyperpigmentation: An overview of the common afflictions. *Dermatol Nurs* 16:401, 2004
- Winter H, Schissel D, Parry DAD, et al: An unusual Ala12Thr polymorphism in the 1A alpha-helical segment of the companion layer-specific keratin K6hf: Evidence for a risk factor in the etiology of the common hair disorder pseudofolliculitis barbae. *J Invest Dermatol* 122:652-657, 2004
- Bridgeman-Shah S: The medical and surgical therapy of pseudofolliculitis barbae. *Dermatol Ther* 17:158-163, 2004
- Halder RM, Roberts CI, Noothehi PK, et al: Dermatologic disease in blacks, in Halder RM (ed): *Dermatology And Dermatological Therapy of Pigmented Skins*. Boca Raton, FL, Taylor & Francis, 2006, pp 331-355
- McMichael AJ: Hair and scalp disorders in ethnic populations. *Dermatol Clin* 21:629-644, 2003
- Perry PK, Cook-Bolden FE, Rahman Z, et al: Defining pseudofolliculitis

- barbae in 2001: A review of the literature and current trends. *J Am Acad Dermatol* 46:S113-S119, 2002
37. Quarles FN, Brody H, Johnson BA, et al: Pseudofolliculitis barbae. *Dermatol Ther* 20:133-136, 2007
  38. Strauss JS, Kligman AM: Pseudofolliculitis of the beard. *Arch Dermatol* 74:533-542, 1956
  39. Alexander MA: Evaluation of a foil-guarded shaver in the management of pseudofolliculitis barbae. *Cutis* 27:534-537:540-542, 1981
  40. Kelly AP: Pseudofolliculitis barbae and acne keloidalis nuchae. *Dermatol Clin* 21:645-653, 2003
  41. Cook-Bolden FE, Barba A, Halder R, et al: Twice-daily applications of benzoyl peroxide, 5%/clindamycin, 1% gel versus vehicle in the treatment of pseudofolliculitis barbae. *Cutis* 73:18-24, 2004 (suppl 6)
  42. Perricone NV: Treatment of pseudofolliculitis barbae with topical glycolic acid: A report of two studies. *Cutis* 52:232-235, 1993
  43. Richards RN, Meharg GE: Electrolysis: Observations from 13 years and 140,000 hours of experience. *J Am Acad Dermatol* 33:662-666, 1995
  44. Hage JJ, Bouman FG: Surgical depilation for the treatment of pseudofolliculitis or local hirsutism of the face: Experience in the first 40 patients. *Plast Reconstr Surg* 88:446-451, 1991
  45. Greppi I: Diode laser hair removal of the black patient. *Lasers Surg Med* 28:150-155, 2001
  46. Battle EF, Jr, Hobbs LM: Laser-assisted hair removal for darker skin types. *Dermatol Ther* 17:177-183, 2004
  47. Weaver SM, III, Sagral EC: Treatment of pseudofolliculitis barbae using the long-pulse Nd:YAG laser on skin types V and VI. *Dermatol Surg* 29:1187-1191, 2003
  48. Ross EV, Cooke LM, Timko AL, et al: Treatment of pseudofolliculitis barbae in skin types IV, V, and VI with a long-pulsed neodymium:Yttrium aluminum garnet laser. *J Am Acad Dermatol* 47:263-270, 2002
  49. Schweiger ES, Kwasniak L, Aries DJ: Treatment of dermatosis papulosa nigra with a 1064 nm Nd:YAG laser: Report of two cases. *J Cosmet Laser Ther* 10:120-122, 2008
  50. Kauh YC, McDonald JW, Rapaport JA, et al: A surgical approach for dermatosis papulosa nigra. *Int J Dermatol* 22:590-592, 1983
  51. Grimes PE, Arora S, Minus HR, et al: Dermatosis papulosa nigra. *Cutis* 32:385-386:392, 1983
  52. Kwon OS, Hwang EJ, Bae JH, et al: Seborrheic keratosis in the Korean males: Causative role of sunlight. *Photodermatology Photoimmunol Photomed* 19:73-80, 2003
  53. Yeatman JM, Kilkenny M, Marks R: The prevalence of seborrheic keratoses in an Australian population: Does exposure to sunlight play a part in their frequency? *Br J Dermatol* 137:411-414, 1997
  54. Niang SO, Kane A, Diallo M, et al: Dermatosis papulosa nigra in Dakar, Senegal. *Int J Dermatol* 46:45-47, 2007 (suppl 1)
  55. Schwartz RA: Sign of lesser-Trélat. *J Am Acad Dermatol* 35:88-95, 1996
  56. Schwartzberg JB, Ricotti CA, Jr, Ballard CJ, et al: Eruptive dermatosis papulosa nigra as a possible sign of internal malignancy. *Int J Dermatol* 46:186-187, 2007
  57. Carter EL, Coppola CA, Barsanti FA: A randomized, double-blind comparison of two topical anesthetic formulations prior to electrodesiccation of dermatosis papulosa nigra. *Dermatol Surg* 32:1-6, 2006
  58. Cockerell CJ, Larsen F: Benign epidermal tumors and proliferations, in Bologna JL, Lorzio JL, Rapini RP, et al (eds): *Dermatology*; vol 2. Spain, Mosby/Elsevier, 2008, pp 1661-1680