

# Phototherapy in the Age of Biologics

Daniel Walker, BS, and Heidi Jacobe, MD, MSCS

Dermatologists are presented with a diversity of therapeutic modalities for the treatment of inflammatory, sclerosing, and neoplastic conditions, but with the development of various new irradiation devices that utilize specific parts of the electromagnetic spectrum, phototherapy has become a more viable, accessible, and efficacious option in the treatment of these conditions. The ultraviolet (UV) range (10-400 nm) is further subdivided into UVA and UVB, each of which has been particularly useful in a number of skin conditions. The most commonly used forms of UV irradiation are UVA<sub>1</sub>, psoralen plus UVA (PUVA), and narrowband (NB) UVB. Each of these modalities differ in their mechanism of action, indications, and side effect profiles, and it is important that clinicians be familiar with these differences. Today, phototherapy is a valuable option in the treatment of many nonpsoriatic conditions including atopic dermatitis, sclerosing skin conditions such as morphea, vitiligo, and mycosis fungoides. Due to its relative safety, phototherapy may be used in most populations, including children and pregnant women. However, contraindications and side effects are known and should be considered before patients begin a phototherapeutic regimen.

Semin Cutan Med Surg 30:190-198 © 2011 Elsevier Inc. All rights reserved.

**KEYWORDS** phototherapy, UVA<sub>1</sub>, narrowband UVB, PUVA, atopic dermatitis, morphea, vitiligo, mycosis fungoides

For thousands of years, sunlight has been used to treat a variety of skin conditions. Ultraviolet (UV) light has been a mainstay in the treatment of psoriasis for more than 30 years, but the development of new topical agents and novel biological immunomodulators has provided dermatologists with a whole new armamentarium in the treatment of psoriasis. However, these drugs are limited by their availability, cost, and side effect profiles<sup>1,2</sup> and because of several advantages to both patients and physicians, phototherapy remains an important therapeutic option for the treatment of psoriasis and other inflammatory skin conditions. In addition, within the last 2 decades, new phototherapeutic modalities have been developed. These devices expanded the use of phototherapy in the treatment of dermatologic disease. Now, phototherapy is an excellent treatment option for many therapeutically challenging dermatologic disorders.

## Photobiology

The electromagnetic spectrum can be divided into subgroups on the basis of the biological effects of each wavelength (Fig. 1). An extensive review of each portion of this spectrum is beyond the scope of this review, and we limit our discussion to radiation within the ultraviolet range (10-400 nm). Ultraviolet radiation (UVR) can be further divided into several subtypes, which are, from shortest to longest wavelengths, UVC (200-290 nm), UVB (290-320 nm), and UVA (320-400 nm). UVA can be further divided into UVA<sub>2</sub> (320-340 nm) and UVA<sub>1</sub> (340-400 nm).

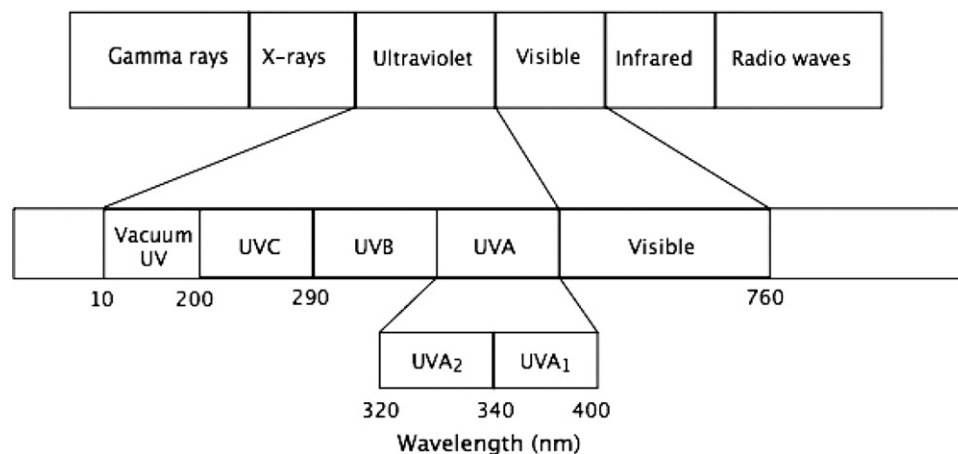
UVB is also referred to as mid-UV, or the sunburn spectrum, because most UVB sunscreens work to prevent erythema. Broadband (BB) UVB was one of the first phototherapy modalities used in the treatment of psoriasis. Today, however, the more commonly used form of UVB is narrowband (NB) UVB, which has a peak emission at 311 nm. A series of clinical trials have demonstrated its superiority in the treatment of psoriasis<sup>3,4</sup> and other conditions when compared with BB UVB. Today, it has become a first-line therapy in the treatment of psoriasis and other nonpsoriatic conditions<sup>5</sup> because of its many advantages. In addition, NB UVB treatment may be home or office based.<sup>6,7</sup>

Unlike UVB radiation, UVA has the ability to penetrate to the deep dermis and subcutis.<sup>8</sup> UVA<sub>1</sub>, because of its proximity to

Department of Dermatology, UT Southwestern Medical Center at Dallas, Dallas, TX.

*Conflict of Interest Disclosures:* The authors have completed and submitted the ICMJE Form for Disclosure of Potential Conflicts of Interest and none were reported.

Address reprint requests to Heidi Jacobe, MD, MSCS, Assistant Professor Dermatology Department, UT Southwestern Medical Center at Dallas, 5323 Harry Hines Blvd., Dallas, TX 75390-9069. E-mail: heidi.jacobe@utsouthwestern.edu



**Figure 1** The electromagnetic spectrum.

visible light on the far end of the UVA spectrum, does not induce erythema effectively, whereas UVA<sub>2</sub>, which resides at the lower wavelengths of UVA, may be associated with effects similar to UVB,<sup>9</sup> including acute sunburn. UVA is also the only type of UV radiation that is not filtered by window glass. The therapeutic potential of UVA<sub>1</sub> first emerged in 1992 in the treatment of atopic dermatitis<sup>10,11</sup> and then in 1995 for the treatment of localized scleroderma.<sup>12</sup> UVA<sub>1</sub> has been reported to have efficacy in a growing number of skin disorders.

Photochemotherapy is the use of psoralen combined with broadband UVA irradiation, also known as psoralen UV (PUVA). PUVA, in its modern form, was first used to treat vitiligo in 1947.<sup>13</sup> The most common PUVA regimen in the United States uses 8-methoxypsoralen (8-MOP), which is administered orally 2 hours before UVA irradiation. Bath PUVA is application of a topical psoralen before UVA irradiation, either to the entire body or limited areas (hands and feet). Advantages of bath PUVA include shorter irradiation times and a lack of gastrointestinal side effects associated with oral psoralens, but its use is limited by need for special facilities, patient inconvenience, and unpredictability (although this is minimal for localized topical PUVA). Consequently, PUVA is usually administered via the use of oral psoralen.

## Mechanism of Action

UV radiation exerts a multitude of biological effects in the skin from mutagenic to immunologic. We present a brief overview here. The depth of penetration of the different light sources used for medical therapy dictate which part of the skin they exert their greatest effect. UVB has more energy than UVA (inverse relationship between wavelength and energy) but has less capability to penetrate beyond the superficial layers of the skin. Thus, UVB primarily affects Langerhans cells and epidermal keratinocytes. UVA radiation, particularly UVA<sub>1</sub>, reaches the deep dermis and potentially the subcutis, thereby impacting dermal fibroblasts, dendritic cells, lymphocytes, mast cells, and granulocytes.<sup>8,14</sup>

The ability to induce lymphocyte apoptosis is an important immunomodulatory effect of UVA and UVB phototherapy.<sup>15</sup>

T cells are highly susceptible to the effects of UV irradiation.<sup>14</sup> The apoptotic effect of UVB is modulated via multiple mechanisms, including the Fas/Fas ligand system, p53, and apoptotic proteases.<sup>16-18</sup> The apoptotic effects of UVA<sub>1</sub> are different from those associated with UVB and include 2 independent caspase systems and an immediate apoptotic effect that may target specific types of cells preferentially.<sup>19,20</sup> UVR also inhibits and depletes the skin of Langerhans cells.<sup>21,22</sup>

The major target for UVB radiation is nuclear DNA, which absorbs UVB-generating pyrimidine dimers, inhibiting DNA synthesis.<sup>23</sup> For PUVA the psoralen molecule intercalates into the double strand of DNA. UVA irradiation then induces a DNA-psoralen crosslink, inhibiting DNA replication and causing cell cycle arrest.<sup>24</sup>

UVR alters the cellular cytokine profiles. UVA<sub>1</sub> suppresses proinflammatory cytokines<sup>25</sup> tumor necrosis factor- $\alpha$  and interleukin (IL)-12 and decreases levels of interferon- $\gamma$  and intercellular adhesion molecule-1, proinflammatory cytokines involved in lymphocyte migration into tissues.<sup>26-28</sup> UVA<sub>1</sub> also causes phenotypic and functional maturation of migrating dermal dendritic cells into potent antigen-presenting cells.<sup>29</sup> UVB has also been shown to decrease proinflammatory cytokines<sup>26,27</sup> interferon- $\gamma$  and IL-12 and increase levels of the anti-inflammatory cytokine IL-10. UVR also has a multitude of effects<sup>30-35</sup> on diseased skin, many of which putatively exert the therapeutic benefit of phototherapy (Table 1).

## Disease-Specific Therapy

### Atopic Dermatitis

Early investigators observed that many patients with atopic dermatitis (AD) improved in the summer, which prompted early reports<sup>36</sup> on the use of phototherapy in the treatment of AD. Multiple phototherapeutic modalities have been credited with exerting a beneficial effect in AD. For the purposes of this review, we concentrate on those that are most commonly used in modern phototherapeutic practice: NB UVB and UVA<sub>1</sub>.

**Table 1** Effects of Ultraviolet Radiation on Diseased Skin

<b>Vitiligo</b>	<b>NB UVB induces activation, proliferation, and migration of inactive melanocytes to the epidermis,<sup>30</sup> melanocyte proliferation via cytokines, such as basic fibroblast growth factor and endothelin-1,<sup>31</sup> and immunosuppression<sup>32</sup></b>
<b>Sclerosing skin conditions</b>	<b>UVA1 alters cytokine cascade, including increased collagenase<sup>33,34</sup></b>
<b>Skin flora</b>	<b>UVB has an antimicrobial effect on local flora and <i>Staphylococcus aureus</i><sup>35</sup></b>

NB UVB is likely the best option for patients with AD who require therapy above and beyond topical preparations. In a pilot case series, 5 patients with severe atopic eczema treated with NB UVB showed significant improvement after 3 weeks of treatment.<sup>37</sup> In a large randomized trial of 73 adults with moderate-to-severe atopic dermatitis, investigators compared NB UVB with UVA during a 12-week course and found NB UVB to be more effective in reducing disease severity.<sup>38</sup>

The use of UVA<sub>1</sub> in the management of patients with acute exacerbations of atopic dermatitis was first described by Krutmann et al<sup>10</sup> in the early 1990s. They were able to demonstrate that high-dose UVA<sub>1</sub> (130 J/cm<sup>2</sup>) was superior to combined UVA and UVB (UVAB). In another study, Krutmann et al<sup>39</sup> showed that high-dose UVA<sub>1</sub> was superior to midpotency corticosteroids in addition to UVAB. Von Kobyletzki et al<sup>40</sup> investigated the use of cold-light UVA<sub>1</sub>, an apparatus that was designed to reduce the heat load generated by traditional UVA<sub>1</sub> and UVAB. They found cold-light UVA<sub>1</sub> to be superior to both UVA<sub>1</sub> and UVAB. Two trials have attempted to establish the optimal dosing schedule for UVA<sub>1</sub> in the treatment of acute AD. Tzaneva et al<sup>41</sup> compared high-dose UVA<sub>1</sub> with medium-dose UVA<sub>1</sub> and showed that there was no statistically significant difference between the 2 regimens. Kowalzik et al<sup>42</sup> conducted a comparative trial for acute AD in which they determined that medium-dose UVA<sub>1</sub> was superior to low-dose UVA<sub>1</sub>. Both UVA<sub>1</sub> and NB UVB in the treatment of AD are supported by level 1 evidence, as defined by the U.S. Preventative Task Force Services.<sup>43</sup> This led investigators to conclude that UVA<sub>1</sub> was the preferred therapy for acute exacerbations of AD and that NB UVB was preferred for maintenance. The authors of a series of recent studies directly comparing NB UVB with UVA<sub>1</sub> have challenged this notion.

In a recent study, Gambichler et al<sup>44</sup> compared medium-dose UVA<sub>1</sub> to NB UVB in the treatment of both acute and chronic atopic eczema. After a 6-week course, both modalities produced significant clinical improvements with no difference between the 2 modalities. Majoie et al<sup>45</sup> published similar results, concluding that NB UVB and medium dose UVA<sub>1</sub> appeared equally effective in the treatment of moderate to severe AD. Most recently, Tzaneva et al<sup>46</sup> published the results of a randomized observer-blinded cross-over trial in which the authors found that PUVA provided a better short- and long-term response than medium dose UVA<sub>1</sub> in patients with severe AD. A summary of these studies<sup>11,37-42,44-46</sup> is found in Table 2.

Taken together, the current evidence suggests NB UVB is the preferred phototherapy option for the treatment of AD both because of efficacy and safety. PUVA or UVA<sub>1</sub> may be considered second-line treatment in patients who fail NB UVB. Recommendations for phototherapy for AD are summarized in Fig. 2.

## Sclerosing Skin Conditions

UVA<sub>1</sub> is a promising treatment for sclerosing skin conditions, a therapeutically challenging group of disorders.

### Morphea (Localized Scleroderma)

Kerscher et al<sup>12</sup> was among the first to report the benefit of low-dose UVA<sub>1</sub> for patients with morphea. The use of UVA<sub>1</sub> phototherapy for morphea is now supported by level 1 evidence, making it second only to methotrexate in terms of demonstration of efficacy. Table 3 highlights important trials<sup>12,33,47-54</sup> supporting the use of UVA<sub>1</sub> for morphea. A series of studies have investigated the ideal dosing regimen of UVA<sub>1</sub> for morphea (low, medium, or high dose). Taken together, these studies indicate low-dose UVA<sub>1</sub> might be of some efficacy or similar to NB UVB, but medium- and high-dose UVA<sub>1</sub> are likely more efficacious. This finding is similar to reports in AD.

Although controversial, UVA<sub>1</sub> phototherapy appears to be equally efficacious in darker skin type patients despite its ability to induce rapid pigmentation.<sup>55,56</sup> Nonetheless, optimum dose, frequency, and duration of therapy have not been worked out for UVA<sub>1</sub>. In our practice, patients begin at 20-60 J/cm<sup>2</sup> depending on Fitzpatrick skin type, and their dose is increased in 10-J/cm<sup>2</sup> increments to a maximum of 60-100 J/cm<sup>2</sup> on the basis of skin type. Treatments are delivered 3-5 times per week, patients are evaluated every 10-15 treatments, and treatment is discontinued after 40-50 treatments at the point of maximal response. In our experience, only the earliest, most inflammatory lesions clear whereas sclerotic lesions tend to improve in texture and mobility. As some of the studies indicate, patients with active, inflammatory morphea respond best. Patients with atrophic lesions will not improve. Given the depth of penetration of UVA<sub>1</sub>, we do not advocate UVA<sub>1</sub> as monotherapy for morphea profunda or eosinophilic fasciitis. Appropriate candidates for therapy include patients with progressive, active lesions of any subtype. Because UVA<sub>1</sub> is not widely available, NB UVB may be considered for superficial dermal lesions and UVA without psoralen for thicker dermal lesions (Table 4).<sup>57-59</sup>

### Scleroderma

Skin disease associated with scleroderma is disabling and highly symptomatic (including significant pruritus). Unfortunately, there is no therapy with proven efficacy for the treatment of scleroderma. Phototherapy, particularly UVA<sub>1</sub>, has been investigated in largely uncontrolled trials, where it appeared to show benefit. One small controlled trial<sup>60</sup> (18 patients, 1 hand randomized to receive treatment) showed that both arms improved over the course of the study, with no significant difference between the treated and untreated arm. These studies only addressed acrosclerosis. In one ret-

Table 2 Studies of Phototherapy for AD

Authors	Study Type	Number of Patients	Phototherapy Modality	Dose	Comment
Krutmann et al (1992) <sup>11</sup>	RCT	25	HD UVA1	130 J/cm <sup>2</sup>	HD UVA1 superior to UVAB, and produced results more quickly
			UVAB	Mean 28 mJ/cm <sup>2</sup> UVB, 7 J/cm <sup>2</sup> UVA	
Kowalick et al (1995) <sup>42</sup>	Uncontrolled trial	22	MD UVA1	50 J/cm <sup>2</sup>	MD UVA1 superior to LD UVA1
			LD UVA1	10 J/cm <sup>2</sup>	
Krutmann et al (1998) <sup>39</sup>	Randomized multicenter trial	43	HD UVA1	130 J/cm <sup>2</sup>	HD UVA1 superior to UVAB, corticosteroids
			UVAB	Mean 33 mJ/cm <sup>2</sup> UVB, 6.8 J/cm <sup>2</sup> UVA	
			0.5% fluocortolone cream	Once daily	
von Kobyletzki et al (1999) <sup>40</sup>	Randomized comparative trial	120	Cold-light UVA1	50 J/cm <sup>2</sup>	Cold-light UVA1 superior to UVA1, UVAB
			UVA1 UVAB	50 J/cm <sup>2</sup> Mean 0.29 J/cm <sup>2</sup> UVB, 7.9 J/cm <sup>2</sup> UVA	
Grundmann-Kollmann et al (1999) <sup>37</sup>	Case series	5	NB UVB	Variable*	Significant improvement in 3 wks
Tzaneva et al (2001) <sup>41</sup>	Randomized bilateral comparison study	10	HD UVA1	130 J/cm <sup>2</sup>	No difference between HD and MD UVA1
			MD UVA1	65 J/cm <sup>2</sup>	
Reynolds et al (2001) <sup>38</sup>	RCT	73	NB UVB	Variable*	NB UVB more effective over 12-wk course
			BB UVA	5-15 J/cm <sup>2</sup>	
Gambichler et al (2009) <sup>44</sup>	Randomized controlled crossover study	28	MD UVA1	50 J/cm <sup>2</sup>	Both modalities comparably good
			NB UVB	Variable*	
Majoie et al (2009) <sup>45</sup>	Randomized half-sided comparison study	13	MD UVA1	Average of 45 J/cm <sup>2</sup>	Both modalities equally effective in chronic AD
			NB UVB	Variable*	
Tzaneva et al (2010) <sup>46</sup>	Randomized crossover study	40	PUVA	Variable†	PUVA provides better response in severe AD
			MD UVA1	70 J/cm <sup>2</sup>	

AD, atopic dermatitis; BB, broadband; HD, high dose; LD, low dose; MD, medium dose; NB, narrowband; PUVA, psoralen plus UVA; RCT, randomized control trial; UV, ultraviolet; UVAB, ultraviolet A plus ultraviolet B.

\*Based upon minimal erythema dose, with incremental increase.

†Based upon minimal phototoxic dose, with incremental increase.

rospective case series<sup>61</sup> the authors did assess total body improvement via the modified Rodnan skin score and found total body improvement for these patients. In our experience, UVA<sub>1</sub> appears to be of benefit to scleroderma patients who have early inflammatory skin disease. We also noted great improvement in the pruritus and salt and pepper pigmentary change associated with scleroderma. Adequately powered trials assessing total body improvement in early scleroderma are needed to further define the potential benefit of this treat-

ment. PUVA has also been reported<sup>62</sup> to be of benefit in scleroderma and may be an option where UVA<sub>1</sub> is not available. Table 5 provides an overview of other sclerosing skin conditions reported to improve with UVA<sub>1</sub> phototherapy.

## Vitiligo

Vitiligo produces depigmentation as a result of destruction of melanocytes. Potent topical steroids remain the first-line

**First Line:***Narrowband UVB (NB UVB)*

- Dose: starting dose of 70% minimal erythema dose, increased 10-20% per session based on prior treatments ability to induce slight erythema, maximum dose of 1.2-1.5 J/cm<sup>2</sup>
- Frequency: 2-3 times weekly for 6-8 weeks
- Expected duration of remission: >3 months

**Second Line:***Ultraviolet A-1 (UVA-1)*

- Dose: 45-60 J/cm<sup>2</sup> (medium dose)
- Frequency: 3-5 times weekly for 3-4 weeks or until clear
- Expected duration of remission: 1-2 months

-OR-

*Psoralen plus UVA (PUVA)*

- Dose: weight based 8-methoxypsoralen (8-MOP) or 5-methoxypsoralen (5-MOP) given 2 hours before broadband UVA irradiation. BB UVA starting dose of 70% minimal erythema dose, increased 10-20% per session based on prior treatments ability to induce slight erythema.
- Frequency: 2-3 times weekly for 5 weeks
- Expected duration of remission: >3 months

**Figure 2** Recommendations for phototherapy for AD.

treatment for limited areas of vitiligo, but phototherapy should be considered when more than 20% of the body surface area is involved.<sup>63</sup> Targeted phototherapy sources are an option when <20% body surface area is involved.

PUVA was a mainstay of treatment for vitiligo until 1997 when Westerhof and Nieuweboer-Krobotava reported<sup>64</sup> the first use of NB UVB in vitiligo. In 1999, guidelines for the treatment of vitiligo were published<sup>65</sup> and they advocated NB UVB as the first choice therapy for generalized vitiligo in adults and as an alternative therapy, after class-III corticosteroids, in children. This recommendation was supported by a single randomized double-blind trial<sup>66</sup> comparing PUVA with NB UVB, which showed that NB UVB was superior to PUVA.

There is no universally accepted protocol for the treatment of vitiligo with NB UVB; therefore, protocols differ between studies. A summary of these studies has recently been published.<sup>32</sup> In general, sessions are performed 2-3 times per week, with doses ranging from 100 to 280 mJ/cm<sup>2</sup>, with doses stabilized and adjusted for each patient thereafter on the basis of individual response and development of erythema. Patient response to NB UVB therapy has been variable. More than 75% repigmentation has been achieved in 12.5%<sup>67</sup> to 75%<sup>68</sup> of patients after approximately 6 months to 1 year of treatment. The reason for such variability is unclear; however, proposed causes

**Table 3** Studies of UVA1 Phototherapy for Morphea

Authors	Study Type	Number of Patients	Phototherapy Modality	Dose	Comment
Kerscher et al (1995) <sup>12</sup>	Case series	10	LD UVA1	20 J/cm <sup>2</sup>	>80% lesion clearance
Stegé et al (1997) <sup>47</sup>	Controlled trial	17	HD UVA1 LD UVA1	130 J/cm <sup>2</sup> 20 J/cm <sup>2</sup>	Significant clearance in both groups, HD UVA1 is superior to LD UVA1
Gruss et al (1997) <sup>33</sup>	Uncontrolled trial	5	LD UVA1	20 J/cm <sup>2</sup>	5/5 improved, 3/45 resolved, normal skin thickness
Kerscher et al (1998) <sup>48</sup>	Uncontrolled trial	20	LD UVA1	20 J/cm <sup>2</sup>	Significant clinical improvement
Gruss (2001) <sup>49</sup>	Case series	3	LD UVA1	20 J/cm <sup>2</sup>	Highly effective in plaque clearance
de Rie et al (2003) <sup>50</sup>	Controlled trial	8	MD UVA1	48 J/cm <sup>2</sup>	Overall improved sclerosis
Kreuter et al (2006) <sup>51</sup>	Randomized controlled study	27	MD UVA1 LD UVA1 NB UVB	50 J/cm <sup>2</sup> 20 J/cm <sup>2</sup> 0.1-1.5 J/cm <sup>2</sup>	MD UVA1 is superior to LD UVA1 and NB UVB, LD UVA1 equivalent to NB UVB
Tuchinda et al (2006) <sup>52</sup>	Multicenter retrospective study	34	MD UVA1 LD UVA1 MD to HD UVA1	50-60 J/cm <sup>2</sup> 20-30 J/cm <sup>2</sup> 50-120 J/cm <sup>2</sup>	Greater clinical improvement in medium and medium to HD UVA1
Sator et al (2009) <sup>53</sup>	Randomized controlled trial	16	MD UVA1 LD UVA1	70 J/cm <sup>2</sup> 20 J/cm <sup>2</sup>	All improved, no difference between MD and LD UVA
Suh et al (2010) <sup>54</sup>	Retrospective study	6	LD UVA1 HD UVA1	20 J/cm <sup>2</sup> 100 J/cm <sup>2</sup>	Both effective in complete and partial remission

HD, high dose; LD, low dose; MD, medium dose; NB, narrowband; UV, ultraviolet.



**Table 4** Studies of UVA Phototherapy for Morphea

Authors	Number of Patients	Regimen	Study Type	Response
El-Mofty et al (2000) <sup>57</sup>	15	20 sessions at 20 J/cm <sup>2</sup>	Controlled trial	Softening of sclerotic lesions (90% cure in early lesions, 50% cure of late lesions)
El-Mofty et al (2004) <sup>58</sup>	67	20 sessions at 5, 10, or 20 J/cm <sup>2</sup>	Randomized control trial	All doses with remarkable softening of sclerotic lesions, no difference between doses
El-Mofty et al (2004) <sup>59</sup>	22	20 sessions at 10 or 20 J/cm <sup>2</sup>	Controlled trial	All improved, 18/22 with moderate or better improvement, 10 J/cm <sup>2</sup> was equivalent to 20 J/cm <sup>2</sup>

UVA, ultraviolet A.

are skin type, location of lesions, and lack of the use of a uniform validated outcome measure. A minimum treatment period of 6 months is recommended with NB UVB with a maximum treatment period of 24 months or until 100% repigmentation.<sup>65</sup> Facial lesions have been shown to be significantly more responsive to treatment, whereas acral site (hands and feet) have shown minimal response.<sup>69</sup> The duration of disease is thought to be inversely correlated with the repigmentation percentage of responsive lesions, with earlier lesions responding better than old ones.<sup>69,70</sup> Some researchers have shown that patients who responded earlier to treatment (around 1 month) have a greater level of posttreatment repigmentation, allowing physicians to better predict patients with a greater chance of achieving satisfactory pigmentation earlier in the treatment course.<sup>67</sup> The Excimer light source is a NB UVB source that has been used for treating localized areas, such as the face, neck, and trunk.

## Mycosis Fungoides

Mycosis fungoides (MF) is the most common form (approximately 65%) of the cutaneous T-cell lymphomas. MF is characterized by an epidermotropic infiltrate of T lymphocytes with the phenotypic display of mature memory T cells.<sup>71</sup> Gilchrist et al<sup>72</sup> first reported the efficacy of phototherapy in MF, when they treated 9 patients with PUVA. In this report, all patients responded well to treatment, and complete remission was achieved in 4 patients. Today, the most common forms of phototherapy used in the treatment of MF are PUVA and both NB and BB UVB. Recently, treatment recommendations and reviews have been published that provide a rational approach to MF. It is now commonly accepted that early-stage MF should be treated with skin directed therapies, while systemic and aggressive treatments should be reserved

for higher stages ( $\geq$ IIB), disease progression, or lack of appropriate responses.<sup>71,73</sup>

PUVA has remained a valuable tool in the treatment of MF over the years owing in part to the large number of clinical trials that have supported its use. A comprehensive list of these studies has been published recently.<sup>74</sup> The rate of complete remission with PUVA is estimated to be 90% with stage IA, 76% with stage IB, 78% with stage IIA, 59% with stage IIB, and 61% with stage III<sup>71,74,75</sup> in general, the protocol for PUVA is similar to that used in psoriasis.<sup>76</sup> Bath PUVA is generally not accepted as the head is not exposed to the topical psoralen and this is a likely source of relapse.<sup>77</sup> The choice to use maintenance phototherapy after clearance is still controversial. Although maintenance therapy is likely beneficial in preventing relapse, it is well documented that PUVA has been associated with carcinogenesis. Therefore, a practical approach is to reserve maintenance for those patients who show signs of early relapse (<6 months). Currently, there is no agreement on maintenance therapy duration, frequency, UVA dosing, and scheduling, but a practical approach may be once weekly treatments for 3-6 months without dose increments.

The first report of UVB phototherapy in the treatment of MF appeared in 1982.<sup>78</sup> A number of studies followed in which authors confirmed the efficacy of UVB in the treatment of MF. A comprehensive list of these studies has been published recently elsewhere.<sup>79</sup> Today, NB UVB has largely replaced the use of BB UVB and is the treatment of choice for the management of stage I MF patients according to a recent survey among dermatologists using office-based phototherapy.<sup>74</sup> However, there is a lack of studies comparing NB UVB with PUVA. A widely accepted consensus is that patients with patches and thin plaques should be preferentially treated with NB UVB, whereas PUVA should be reserved for thicker plaques. One comprehensive review<sup>74</sup> concluded that NB UVB administered 3 times per week or PUVA 2-3 times per week, continued until clearance (most commonly 3-4 months), was an effective regimen in the initial clearing stages of MF. On the basis of the results of one retrospective analysis, it has been proposed that because of its practical advantages, NB UVB might be a reasonable approach to treat early MF. PUVA may then be initiated in cases that fail to respond.<sup>80</sup>

**Table 5** Other Sclerosing Skin Conditions Reported to Improve With UVA1

Lichen Sclerosus et Atrophicus
Sclerodermoid GVHD
Scleredema
Necrobiosis lipodica
Nephrogenic systemic fibrosis

GVHD, graft-versus-host disease.

**Table 6** Other Cutaneous Conditions That Have Been Responsive to Phototherapy

UVA1	NB UVB	PUVA
Cutaneous mastocytosis	Acquired perforating dermatitis	Alopecia areata
Dyshidrosis	Chronic urticaria	Cutaneous GVHD
Granuloma annulare	Generalized granuloma annulare	Dermatitis herpetiformis
Keloids	Lichen planus	Dyshidrotic eczema
Mycosis fungoides	Lichen simplex chronicus	Granuloma annulare
Pityriasis lichenoides	Lymphomatoid papulosis	Histiocytosis
Sarcoidosis	Mastocytosis	Lichen planus
Systemic lupus erythematosus	Parapsoriasis	Mastocytosis
	Pityriasis lichenoides	Morphea
	Pityriasis rosea	Palmoplantar psoriasis
	Pruritis	Pityriasis rosea
	Seborrheic dermatitis	Urticaria
		Urticaria pigmentosa

GVHD, graft-versus-host disease; NB, narrow band; PUVA, psoralen UV; UVA1, ultraviolet A1; UVB, ultraviolet B.

## Other Uses of Phototherapy

Other skin disorders that may be responsive to UVA, UVB, and PUVA are listed in Table 6.

## Phototherapy in Children

The use of phototherapy in children is limited by concern about long-term carcinogenesis and photoaging.<sup>81</sup> Conversely, it is important to avoid exposing children to the risks of prebiologics and biologics whenever possible because of their potential risks, which include infection, malignancy, bone marrow suppression, and renal toxicity.<sup>82</sup> Thus, many have considered phototherapy to be a safe alternative in children requiring more than topical agents to control their disease. Pavlovsky et al<sup>83</sup> recently published one of the largest retrospective studies to date on the use of NB UVB in the pediatric population for psoriasis and AD. Their report included results from 129 children followed during an 8-year period, concluding that this was a viable therapeutic option that should be used with caution in a carefully selected population. Another recent 15-year prospective study evaluating the use of NB UVB phototherapy in 116 children determined it to be an effective and well-tolerated treatment, with most children only needing a single course.<sup>84</sup> As with all patients who receive phototherapy, parents should be counseled on sun protection, sunscreen use, sun avoidance, and the need for regular skin examinations.

## Side Effects and Contraindications

One of the primary advantages of UV phototherapy as compared to systemic steroids, biologics, or other immunosuppressive medications, is its relative safety and lack of side effects. Nonetheless, reported side effects range from mild to severe and should be considered before a patient begins UV phototherapy.

NB UVB is safe in almost any patient regardless of comorbidity, including children<sup>83</sup> and pregnant women. Acute adverse side effects during NB UVB treatment are infrequent. Of

those reported, the most common are erythema, pruritus, and xerosis, which typically resolve after topical emollients.<sup>32</sup> Chronic adverse effects include photoaging and possibly photocarcinogenesis (although studies to date have failed to identify significantly increased risk).

Patients treated with UVA<sub>1</sub> most commonly report no side effects other than tanning and, less commonly, erythema and pruritus. UVA<sub>1</sub> has been reported to cause a polymorphic light eruption<sup>85</sup> and activation of herpes simplex infection.

The side effects of the psoralen, 8-MOP, used in PUVA therapy, include nausea and gastrointestinal upset. One strategy for reducing the side effects of 8-MOP-induced nausea is to decrease the dose and compensate by increasing the dose of UVA by the same percentage.<sup>23</sup> 8-MOP may also be substituted with 5-MOP, which is relatively equivalent in efficacy and produces fewer side effects. As mentioned previously, bath PUVA carries some inconveniences as compared with oral psoralen therapy. Despite these inconveniences, bath PUVA is preferential in patients with limited treatment areas, such as the hands and feet, and may also be considered in patients who would otherwise have difficulty in tolerating oral psoralen (when facilities are available). In addition, some patients treated with PUVA complain of a painful, burning itch that may persist for months after treatment. Currently, PUVA is the only phototherapeutic modality definitively linked with the development of melanoma and nonmelanoma skin cancer in white patients.<sup>86,87</sup>

Various factors modulate the risk of carcinogenesis in each patient before any exposure to phototherapy. These factors include Fitzpatrick skin type, preexisting actinic damage, age, and personal habits and behavior (extensive outdoor exposure, tanning bed use). These elevate the baseline risk for carcinogenesis for each patient and therefore, additional exposure to further risk is clearly contraindicated.

## Conclusions

Phototherapy represents an excellent option in several therapeutically challenging disorders by providing effective therapy without systemic side effects. Although most commonly

associated with the treatment of psoriasis, phototherapy is a valuable tool in the treatment of a large number of skin disorders, many of which are disabling or have significant impact on life quality. This makes phototherapy relevant to modern dermatologic practice, even in the age of biological therapy. Further, the advent of more sophisticated devices using limited UV wavelengths or delivering targeted phototherapy continues to expand the role of this modality.

## References

- Lima XT, Seidler EM, Lima HC, et al: Long-term safety of biologics in dermatology. *Dermatol Ther* 22:2-21, 2009
- Graves JE, Nunley K, Heffernan MP: Off-label uses of biologics in dermatology: Rituximab,omalizumab, infliximab, etanercept, adalimumab, efalizumab, and alefacept (part 2 of 2). *J Am Acad Dermatol* 56:e55-e79, 2007
- Barbagallo J, Spann CT, Tutrone WD, et al: Narrowband UVB phototherapy for the treatment of psoriasis: A review and update. *Cutis* 68:345-347, 2001
- Dawe RS: A quantitative review of studies comparing the efficacy of narrow-band and broad-band ultraviolet B for psoriasis. *Br J Dermatol* 149:669-672, 2003
- Gambichler T, Breuckmann F, Boms S, et al: Narrowband UVB phototherapy in skin conditions beyond psoriasis. *J Am Acad Dermatol* 52:660-670, 2005
- Koek MB, Buskens E, Bruijnzeel-Koomen CA, et al: Home ultraviolet B phototherapy for psoriasis: Discrepancy between literature, guidelines, general opinions and actual use. Results of a literature review, a web search, and a questionnaire among dermatologists. *Br J Dermatol* 154:701-711, 2006
- Sarkany RP, Anstey A, Diffey BL, et al: Home phototherapy: Report on a workshop of the British Photodermatology Group, December 1996. *Br J Dermatol* 140:195-199, 1999
- Anderson RR, Parrish JA: The optics of human skin. *J Invest Dermatol* 77:13-19, 1981
- Young A: The molecular and genetic effects of ultraviolet radiation exposure on skin, in Hawk JLM (ed): *Photodermatology*. London, Arnold, 1996, pp 25-42
- Krutmann J, Czech W, Diepgen T, et al: High-dose UVA1 therapy in the treatment of patients with atopic dermatitis. *J Am Acad Dermatol* 26:225-230, 1992
- Krutmann J, Schopf E: High-dose-UVA1 phototherapy: A novel and highly effective approach for the treatment of acute exacerbation of atopic dermatitis. *Acta Derm Venereol Suppl (Stockh)* 176:120-122, 1992
- Kerscher M, Dirschka T, Volkenandt M: Treatment of localised scleroderma by UVA1 phototherapy. *Lancet* 346:1166, 1995
- El-Mofty AM: A preliminary clinical report on the treatment of leukoderma with *Ammi majus* Linn. *J R Egypt Med Assoc* 651-665, 1948
- Krutmann J, Morita A: Therapeutic photomedicine, in Freedberg IM, Eisen AZ, Wolff K (eds): *Fitzpatrick's Dermatology in General Medicine*. New York, McGraw Hill, 2003, pp 2469-2477
- Morita A, Krutmann J: Ultraviolet A radiation-induced apoptosis. *Methods Enzymol* 319:302-309, 2000
- Gutierrez-Steil C, Wrone-Smith T, Sun X, et al: Sunlight-induced basal cell carcinoma tumor cells and ultraviolet-B-irradiated psoriatic plaques express Fas ligand (CD95L). *J Clin Invest* 101:33-39, 1998
- Schwartz SM, Bennett MR: Death by any other name. *Am J Pathol* 147:229-234, 1995
- Wright SC, Wei QS, Kinder DH, et al: Biochemical pathways of apoptosis: Nicotinamide adenine dinucleotide-deficient cells are resistant to tumor necrosis factor or ultraviolet light activation of the 24-kD apoptotic protease and DNA fragmentation. *J Exp Med* 183:463-471, 1996
- Godar DE: UVA1 radiation triggers two different final apoptotic pathways. *J Invest Dermatol* 112:3-12, 1999
- Morita A, Werfel T, Stege H, et al: Evidence that singlet oxygen-induced human T helper cell apoptosis is the basic mechanism of ultraviolet-A radiation phototherapy. *J Exp Med* 186:1763-1768, 1997
- Gruner S, Zwirner A, Strunk D, et al: The influence of topical dermatological treatment modalities on epidermal Langerhans cells and contact sensitization in mice. *Contact Dermatitis* 26:241-247, 1992
- DeSilva B, McKenzie RC, Hunter JA, et al: Local effects of TL01 phototherapy in psoriasis. *Photodermatol Photoimmunol Photomed* 24:268-269, 2008
- Lapolla W, Yentzer BA, Bagel J, et al: A review of phototherapy protocols for psoriasis treatment. *J Am Acad Dermatol* 64:936-949, 2011
- Hönigsmann H: Phototherapy for psoriasis. *Clin Exp Dermatol* 26:343-350, 2001
- Skov L, Hansen H, Allen M, et al: Contrasting effects of ultraviolet A1 and ultraviolet B exposure on the induction of tumour necrosis factor-alpha in human skin. *Br J Dermatol* 138:216-220, 1998
- Krutmann J, Grewe M: Involvement of cytokines, DNA damage, and reactive oxygen intermediates in ultraviolet radiation-induced modulation of intercellular adhesion molecule-1 expression. *J Invest Dermatol* 105:675-705, 1995
- Szegedi A, Simics E, Aleksza M, et al: Ultraviolet-A1 phototherapy modulates Th1/Th2 and Tc1/Tc2 balance in patients with systemic lupus erythematosus. *Rheumatol Oxf Engl* 44:925-931, 2005
- Grewe M, Gyufko K, Schöpf E, et al: Lesional expression of interferon-gamma in atopic eczema. *Lancet* 343:25-26, 1994
- Schlaak M, Schwind S, Wetzig T, et al: UVA (UVA-1) therapy for the treatment of acute GVHD of the skin. *Bone Marrow Transplant* 45:1741-1748, 2010
- Cui J, Shen LY, Wang GC: Role of hair follicles in the repigmentation of vitiligo. *J Invest Dermatol* 97:410-416, 1991
- Wu CS, Yu CL, Wu CS, et al: Narrow-band ultraviolet-B stimulates proliferation and migration of cultured melanocytes. *Exp Dermatol* 13:755-763, 2004
- Nicolaïdou E, Antoniou C, Stratigos A, et al: Narrowband ultraviolet B phototherapy and 308-nm excimer laser in the treatment of vitiligo: A review. *J Am Acad Dermatol* 60:470-477, 2009
- Gruss C, Stucker M, Kobyletzki G, et al: Low dose UVA1 phototherapy in disabling pansclerotic morphoea of childhood. *Br J Dermatol* 136:293-294, 1997
- Scharffetter K, Wlaschek M, Hogg A, et al: UVA irradiation induces collagenase in human dermal fibroblasts in vitro and in vivo. *Arch Dermatol Res* 283:506-511, 1991
- Yoshimura M, Namura S, Akamatsu H, et al: Antimicrobial effects of phototherapy and photochemotherapy in vivo and in vitro. *Br J Dermatol* 135:528-532, 1996
- Morison WL, Parrish J, Fitzpatrick TB: Oral psoralen photochemotherapy of atopic eczema. *Br J Dermatol* 98:25-30, 1978
- Grundmann-Kollmann M, Behrens S, Podda M, et al: Phototherapy for atopic eczema with narrow-band UVB. *J Am Acad Dermatol* 40:995-997, 1999
- Reynolds NJ, Franklin V, Gray JC, et al: Narrow-band ultraviolet B and broad-band ultraviolet A phototherapy in adult atopic eczema: A randomised controlled trial. *Lancet* 357:2012-2016, 2001
- Krutmann J, Diepgen TL, Luger TA, et al: High-dose UVA1 therapy for atopic dermatitis: Results of a multicenter trial. *J Am Acad Dermatol* 38:589-593, 1998
- von Kobyletzki G, Pieck C, Hoffmann K, et al: Medium-dose UVA1 cold-light phototherapy in the treatment of severe atopic dermatitis. *J Am Acad Dermatol* 41:931-937, 1999
- Tzaneva S, Seeber A, Schwaiger M, et al: High-dose versus medium-dose UVA1 phototherapy for patients with severe generalized atopic dermatitis. *J Am Acad Dermatol* 45:503-507, 2001
- Kowalick L, Kleinheinz A, Weichenthal M, et al: Low dose versus medium dose UV-A1 treatment in severe atopic eczema. *Acta Derm Venereol* 75:43-45, 1995
- Creating a framework for "best evidence" approaches in systematic reviews. *Am J Prev Med*, 2010. Available at: <http://www.ahrq.gov/clinic/tp/bestevtp.htm>. Accessed April 26, 2011
- Gambichler T, Othlinghaus N, Tomi NS, et al: Medium-dose ultraviolet



- (UV) A1 vs. narrowband UVB phototherapy in atopic eczema: A randomized crossover study. *Br J Dermatol* 160:652-658, 2009
45. Majoie IM, Oldhoff JM, van Weelden H, et al: Narrowband ultraviolet B and medium-dose ultraviolet A1 are equally effective in the treatment of moderate to severe atopic dermatitis. *J Am Acad Dermatol* 60:77-84, 2009
  46. Tzaneva S, Kittler H, Holzer G, et al: 5-Methoxypsoralen plus ultraviolet (UV) A is superior to medium-dose UVA1 in the treatment of severe atopic dermatitis: A randomized crossover trial. *Br J Dermatol* 162:655-660, 2010
  47. Stege H, Berneburg M, Humke S, et al: High-dose UVA1 radiation therapy for localized scleroderma. *J Am Acad Dermatol* 36:938-944, 1997
  48. Kerscher M, Volkenandt M, Gruss C, et al: Low-dose UVA phototherapy for treatment of localized scleroderma. *J Am Acad Dermatol* 38:21-26, 1998
  49. Gruss CJ, Von Kobyletzki G, Behrens-Williams SC, et al: Effects of low dose ultraviolet A-1 phototherapy on morphea. *Photodermatol Photoimmunol Photomed* 17:149-155, 2001
  50. de Rie MA, Enomoto DN, de Vries HJ, et al: Evaluation of medium-dose UVA1 phototherapy in localized scleroderma with the cutometer and fast Fourier transform method. *Dermatology* 207:298-301, 2003
  51. Kreuter A, Hyun J, Stücker M, et al: A randomized controlled study of low-dose UVA1, medium-dose UVA1, and narrowband UVB phototherapy in the treatment of localized scleroderma. *J Am Acad Dermatol* 54:440-447, 2006
  52. Tuchinda C, Kerr HA, Taylor CR, et al: UVA1 phototherapy for cutaneous diseases: An experience of 92 cases in the United States. *Photodermatol Photoimmunol Photomed* 22:247-253, 2006
  53. Sator PG, Radakovic S, Schulmeister K, et al: Medium-dose is more effective than low-dose ultraviolet A1 phototherapy for localized scleroderma as shown by 20-MHz ultrasound assessment. *J Am Acad Dermatol* 60:786-791, 2009
  54. Suh KS, Kang JS, Baek JW, et al: Efficacy of ultraviolet A1 phototherapy in recalcitrant skin diseases. *Ann Dermatol* 22:1-8, 2010
  55. Jacobs HT, Cayce R, Nguyen J: UVA1 phototherapy is effective in darker skin: A review of 101 patients of Fitzpatrick skin types I-V. *Br J Dermatol* 159:691-696, 2008
  56. Wang F, Garza LA, Cho S, et al: Effect of increased pigmentation on the antifibrotic response of human skin to UV-A1 phototherapy. *Arch Dermatol* 144:851-858, 2008
  57. El-Mofly M, Zaher H, Bosseila M, et al: Low-dose broad-band UVA in morphea using a new method for evaluation. *Photodermatol Photoimmunol Photomed* 16:43-49, 2000
  58. El-Mofly M, Mostafa W, El-Darouty M, et al: Different low doses of broad-band UVA in the treatment of morphea and systemic sclerosis. *Photodermatol Photoimmunol Photomed* 20:148-156, 2004
  59. El-Mofly M, Mostafa W, Esmat S, et al: Suggested mechanisms of action of UVA phototherapy in morphea: A molecular study. *Photodermatol Photoimmunol Photomed* 20:93-100, 2004
  60. Kreuter A, Breuckmann F, Uhle A, et al: Low-dose UVA1 phototherapy in systemic sclerosis: Effects on acrosclerosis. *J Am Acad Dermatol* 50:740-747, 2004
  61. Rose RF, Turner D, Goodfield MJ, et al: Low-dose UVA1 phototherapy for proximal and acral scleroderma in systemic sclerosis. *Photodermatol Photoimmunol Photomed* 25:153-155, 2009
  62. Usmani N, Murphy A, Veale D, et al: Photochemotherapy for systemic sclerosis: Effect on clinical and molecular markers. *Clin Exp Dermatol* 35:608-613, 2010
  63. Tamesis ME, Morelli JG: Vitiligo treatment in childhood: A state of the art review. *Pediatr Dermatol* 27:437-445, 2010
  64. Westerhof W, Nieuweboer-Krobotova L: Treatment of vitiligo with UV-B radiation vs topical psoralen plus UV-A. *Arch Dermatol* 133:1525-1528, 1997
  65. Njoo MD, Westerhof W, Bos JD, et al: The development of guidelines for the treatment of vitiligo. Clinical Epidemiology Unit of the Istituto Dermatologico dell'Immacolata-Istituto di Recupero e Cura a Carattere Scientifico (IDI-IRCCS) and the Archives of Dermatology. *Arch Dermatol* 135:1514-1521, 1999
  66. Yones SS, Palmer RA, Garibaldinos TM, et al: Randomized double-blind trial of treatment of vitiligo: Efficacy of psoralen-UV-A therapy vs Narrowband-UV-B therapy. *Arch Dermatol* 143:578-584, 2007
  67. Chen GY, Hsu MM, Tai HK, et al: Narrow-band UVB treatment of vitiligo in Chinese. *J Dermatol* 32:793-800, 2005
  68. Kanwar AJ, Dogra S: Narrow-band UVB for the treatment of generalized vitiligo in children. *Clin Exp Dermatol* 30:332-336, 2005
  69. Anbar TS, Westerhof W, Abdel-Rahman AT, et al: Evaluation of the effects of NB-UVB in both segmental and non-segmental vitiligo affecting different body sites. *Photodermatol Photoimmunol Photomed* 22:157-163, 2006
  70. Njoo MD, Spuls PI, Bos JD, et al: Nonsurgical repigmentation therapies in vitiligo. Meta-analysis of the literature. *Arch Dermatol* 134:1532-1540, 1998
  71. Trautinger F: Phototherapy of mycosis fungoides. *Photodermatol Photoimmunol Photomed* 27:68-74, 2011
  72. Gilchrist BA, Parrish JA, Tanenbaum L, et al: Oral methoxsalen photochemotherapy of mycosis fungoides. *Cancer* 38:683-689, 1976
  73. Kaye FJ, Bunn PA Jr, Steinberg SM, et al: A randomized trial comparing combination electron-beam radiation and chemotherapy with topical therapy in the initial treatment of mycosis fungoides. *N Engl J Med* 321:1784-1790, 1989
  74. Carter J, Zug KA: Phototherapy for cutaneous T-cell lymphoma: Online survey and literature review. *J Am Acad Dermatol* 60:39-50, 2009
  75. Herrmann JJ, Roenigk HH Jr, Honigsmann H: Ultraviolet radiation for treatment of cutaneous T-cell lymphoma. *Hematol/Oncol Clin North Am* 9:1077-1088, 1995
  76. Hölzle E, Honigsmann H, Röcken M, et al: Recommendations for phototherapy and photochemotherapy [in German]. *J Dtsch Dermatol Ges* 1:985-997, 2003
  77. Weber F, Schmuth M, Sepp N, et al: Bath-water PUVA therapy with 8-methoxypsoralen in mycosis fungoides. *Acta Derm Venereol* 85:329-332, 2005
  78. Milstein HJ, Vonderheid EC, Van Scott EJ, et al: Home ultraviolet phototherapy of early mycosis fungoides: Preliminary observations. *J Am Acad Dermatol* 6:355-362, 1982
  79. Honigsmann H, Tanew A: Photo(chemo)therapy for cutaneous T-cell lymphoma. *Dermatol Photother Photodiagnostic Methods* 135-149, 2009
  80. Diederer PV, van Weelden H, Sanders CJ, et al: Narrowband UVB and psoralen-UVA in the treatment of early-stage mycosis fungoides: A retrospective study. *J Am Acad Dermatol* 48:215-219, 2003
  81. Trueb RM: Therapies for childhood psoriasis. *Curr Probl Dermatol* 38:137-159, 2009
  82. Pugashetti R, Koo J: Phototherapy in pediatric patients: Choosing the appropriate treatment option. *Semin Cutan Med Surg* 29:115-120, 2010
  83. Pavlovsky M, Baum S, Shpiro D, et al: Narrow band UVB: Is it effective and safe for paediatric psoriasis and atopic dermatitis? *J Eur Acad Dermatol Venereol* 25:727-729, 2011
  84. Tan E, Lim D, Rademaker M: Narrowband UVB phototherapy in children: A New Zealand experience. *Australas J Dermatol* 51:268-273, 2010
  85. McGrath H Jr: Ultraviolet A1 (340-400 nm) irradiation and systemic lupus erythematosus. *J Invest Dermatol Symp Proc* 4:79-84, 1999
  86. Stern RS: PUVA follow-up study: The risk of melanoma in association with long-term exposure to PUVA. *J Am Acad Dermatol* 44:755-761, 2001
  87. Murase JE, Lee EE, Koo J: Effect of ethnicity on the risk of developing nonmelanoma skin cancer following long-term PUVA therapy. *Int J Dermatol* 44:1016-1021, 2005