

Dilute Betadine Lavage Reduces Implant-Related Bacterial Burden in a Rabbit Knee Prosthetic Infection Model

Mohit Gilotra, MD, Thao Nguyen, MD, David Jaffe, MD, and Robert Sterling, MD

Abstract

Treatment of acute postoperative arthroplasty infection with polyethylene exchange and retention of components has a limited success rate, potentially because of residual bacterial burden. We hypothesized that dilute Betadine (povidone-iodine) lavage would decrease bacterial burden in a rabbit knee infection model.

We inserted a stainless steel screw with a polyethylene washer into the lateral femoral condyle in 16 bilateral rabbit knees, and the sites were infected with *Staphylococcus aureus*. After 1 week, all knees were treated with a polyethylene washer exchange and either a saline lavage or a 3.5% Betadine lavage.

We assessed bacterial growth after 7 days. Betadine-treated knees showed a statistically significant decrease in the bacterial count on the stainless steel screw and polyethylene washer but no difference in soft-tissue growth. Betadine lavage as a treatment adjunct may improve component retention for acute arthroplasty infection.

Surgical site infection after arthroplasty causes substantial morbidity and potential mortality. Prosthetic joint infection (PJI) ranges from simple superficial wound infection and cellulitis to deep subfascial infection that involves the prosthesis. Consistent use of prophylactic antibiotics has reduced postoperative hip and knee arthroplasty infections to rates of 0.25% to 2%.¹⁻⁴ Treatment of a patient with PJI commonly includes hospitalization, long-term intravenously administered antibiotics, resection arthroplasty, and staged reimplantation. The estimated cost of interventions reaches tens of millions of dollars annually in the United States and does not include the costs of psychosocial effects on patients and their families.^{5,6}

Betadine (povidone-iodine) is a widely used antiseptic for skin and mucous membrane wounds and has been shown to be effective for the prevention of PJI.⁷ Dilute Betadine solution has been proposed as an aid in treatment of PJI.⁸ At a minimum concentration of 5%, cytotoxicity has been observed in chicken

tibia osteoblasts.⁹ A balance of the bactericidal and cytotoxic activities of Betadine, while maintaining its efficacy against resistant organisms, such as methicillin-resistant *Staphylococcus aureus* (MRSA), is optimized at dilutions between 0.5% and 4%.¹⁰⁻¹⁴ We hypothesized that a dilute Betadine lavage of 3.5% would achieve a significant decrease in bacterial counts compared with an isolated saline lavage in an in vivo knee PJI model.

Materials and Methods

Animal Protocol

All surgical procedures were conducted according to the protocol approved by our institutional animal care and use committee. Using a power analysis and data obtained at our institution, we determined that 12 was the minimum number of animals needed to reach significance set at $P < .05$ and assuming a 50% decrease in colony-forming units (CFU) (SigmaStat Version 2.03; Aspire Software International, Ashburn, Virginia). Eight New Zealand White rabbits were used in our study; because significance was reached early, 12 were not needed. The average weight of the rabbits was 3.5 kg (weight range, 3.2-4.1 kg). All rabbits completed 1 week of acclimation before surgery.

Bacteria Preparation

A broth culture of methicillin-sensitive *S aureus* (MSSA) (ATCC 25923) was prepared 1 day before surgery. The bacteria were suspended in 5 mL of Trypticase Soy Broth (Becton Dickinson & Co, Franklin Lakes, New Jersey) and incubated at 37°C in a shaking incubator for 16 hours. The next day, the culture was centrifuged and irrigated twice with normal saline to remove the broth and prevent further growth. The bacteria were reconstituted in normal saline, and the concentration was standardized using a turbidity meter (LaMotte 2020e; LaMotte Co, Chestertown, Maryland), which correlated with 10⁶ CFU/100 µl plated on trypticase soy agar plates with 10% sheep blood (Fisher Scientific, Pittsburgh, Pennsylvania).

Surgical and Postoperative Procedures

Our procedure was based on the New Zealand White rabbit knee PJI model.¹⁵ General anesthesia was induced with ketamine and xylazine, and maintained with isoflurane inhala-

Authors' Disclosure Statement: The authors report no actual or potential conflict of interest in relation to this article.

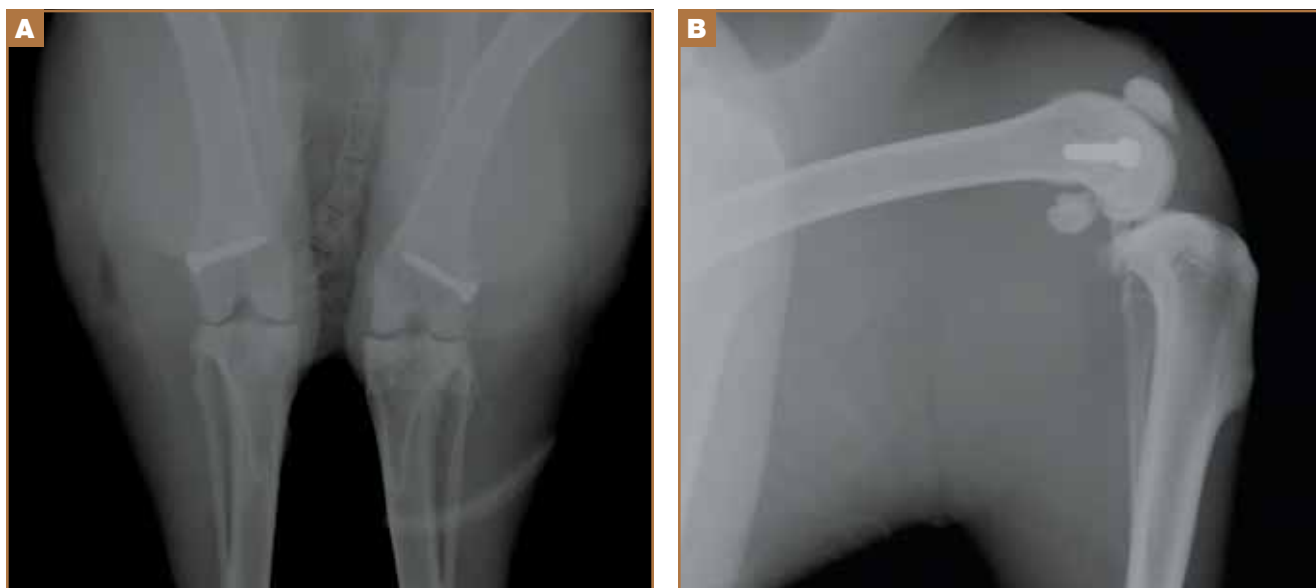

Figure 1. (A) Anteroposterior and (B) lateral radiographic views show bilateral screw implantation in an intra-articular yet non-weight-bearing aspect of the lateral femoral condyle.

tion via a nose cone mask. Rabbits were positioned supine, and bilateral knees were shaved, prepped, and draped in a sterile fashion.

A 2-cm longitudinal incision was made over the lateral knee, and arthrotomy was performed, exposing the lateral collateral ligament attachment at the lateral femoral condyle. Using a 4-mm drill bit, a defect was drilled obliquely into the lateral femoral condyle, anterior to the lateral collateral ligament attachment. This produced a defect in the non-weight-bearing, nonarticulating portion of the knee. A fully threaded 4×14-mm stainless steel screw (Synthes, West Chester, Pennsylvania) with a U-shaped ultrahigh-molecular-weight polyethylene washer (Synthes) was inserted into the defect. The joint capsule was closed with a running 3-0 Vicryl suture (Ethicon, Somerville, New Jersey). The knee joint was inoculated with 100 μ L of the *S aureus* preparation using a 22-gauge needle. The skin was closed with a 4-0 Biosyn suture (Ethicon). The procedure was repeated on the contralateral knee (Figures 1A, 1B).

Seven days after the initial surgery, the rabbits were returned to the operating room and were anesthetized, positioned, and prepped for surgery as detailed above. Ceftriaxone (20 mg/kg of body weight) was intravenously administered to all rabbits for the treatment procedure. For each rabbit, a control knee and an experimental knee were randomly assigned. A longitudinal incision was made, exposing the previously placed implants. The screw was loosened slightly to remove the U-shaped polyethylene washer. Each knee then underwent lavage 2 times, for 90 seconds each time, with 3.5% dilute Betadine solution (experimental knee) or with normal saline (control knee). Because *Pseudomonas* contamination has been reported with povidone-iodine taken from unsterilized bottles,^{16,17} packets of sterilized povidone-iodine (Aplicare;

Clorox, Oakland, California) were used. After the irrigation was complete, a new sterile polyethylene washer was placed and the screw was tightened. The wound closure was repeated as detailed above.

Postoperative analgesia was provided based on a standard institutional animal care and use committee protocol. Rabbits were permitted full cage activity and nutrition *ad libitum*. Wound healing, body weight, and signs of distress were monitored daily.

Outcome Measures

Seven days after surgery, the rabbits were euthanized with administration of phenobarbital (100 mg/kg of body weight). Arterial blood samples were obtained from the auricular vein to ensure that the rabbits were not systemically infected. Using a sterile technique, the screw, polyethylene washer, lateral femoral condyle bone from the defect, and joint capsule were cultured. Harvested bone and soft tissues were weighed and immediately homogenized (PowerGen Model 35 Handheld Homogenizer; Thermo Fisher Scientific, Inc, Waltham, Massachusetts). Implants were sonicated (UBATH-Y; World Precision Instruments, Inc, Sarasota, Florida) in cold saline to obtain a sensitive culture.¹⁸

Bacterial quantification was determined by using trypticase soy agar plates after 24 hours of growth. Final CFU were calculated after serial dilutions and were standardized per gram of biopsied tissues.¹⁹ Members of the team were blinded to the treatment type.

Statistical Analysis

Statistical differences in mean bacterial burden were calculated independently for lateral condyle bone, joint capsule, polyethylene, and screws by conducting a Student t test.

Results

Treatment effect was higher than expected, and the study was terminated after 8 animals completed the protocol. All 8 rabbits tolerated the procedures well and were appropriately monitored during the postoperative period. No animals had signs of systemic infection or positive blood culture. All local cultures for screw, polyethylene washer, lateral femoral condyle defect, and joint capsule were positive.

Statistically significant decreases were shown in the bacterial burden of the Betadine-irrigated screws and the Betadine-irrigated polyethylene washers compared with the saline-irrigated controls. Betadine-irrigated screws grew an average of 7.16×10^1 CFU of *S aureus*/g, whereas screws from control knees grew an average of 1.45×10^3 CFU/g ($P = .0003$) (Figure 2). Betadine-treated washers grew an average of 1.28×10^3 CFU/g compared with 1.62×10^4 CFU/g for control washers ($P = .04$) (Figure 3).

A trend toward decreased bacterial counts was shown in Betadine-treated soft tissues compared with saline-treated soft tissues, but the difference did not reach statistical significance ($P = .9$). Biopsied joint capsule from knees treated with Betadine grew an average of 2.84×10^4 CFU/g compared with an average of 3.16×10^4 CFU/g in control-rabbit knees (Figure 4). Cultured lateral condyle from Betadine-treated knees had an average bacterial load of 3.22×10^4 CFU/g compared with an average bacterial load of 1×10^5 CFU/g in control knees (Figure 4).

Discussion

Knees irrigated with Betadine showed a significant ($P = .0003$) decrease in metal implant-related *S aureus* bacterial counts by 20-fold and a significant ($P < .05$) decrease in polyethylene implant-related counts by more than 10-fold. This arthroplasty model used Betadine lavage as a treatment adjunct with intravenously administered antibiotics and polyethylene exchange. Our 1-week interval after the index procedure classifies the infection as an acute postoperative arthroplasty infection (occurring less than 4 weeks postoperatively).

The gold standard treatment for these infections is irrigation and débridement with component retention.¹⁸ The success rate has been reported to be as high as 71%²⁰ but was closer to 44% in a study by Fridkin and colleagues,²¹ especially with more virulent bacteria. *Staphylococcal* species, higher American Society of Anesthesiologists scores, and frank pus around the prosthesis were markers of débridement failure in a recent study by Azzam and colleagues.¹⁸

The majority of postoperative joint arthroplasty infections are caused by *S aureus*, and the incidence of MRSA bacteria continues to rise.²² Community-acquired MRSA is increasing at an alarming rate and is now the predominant organism in skin and soft-tissue infections.²³ Organism resistance also occurs at a cellular level by the formation of a glycocalyx layer, or biofilm. This layer assists in changing the phenotypic properties of the organism and decreases the efficacy of antibiotics.²⁴ The self-produced layer of extracellular matrices, deoxyribonucleic acid, and polysaccharides attaches to inert material, preventing

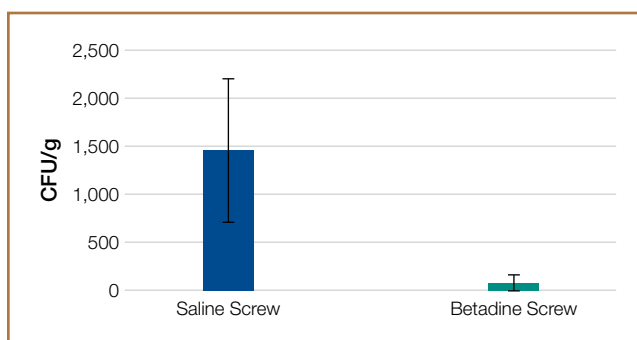


Figure 2. Implant bacterial burden (measured in standardized CFU/g) was decreased in cultures obtained from Betadine-treated screws. The difference was statistically significant ($P = .0003$).

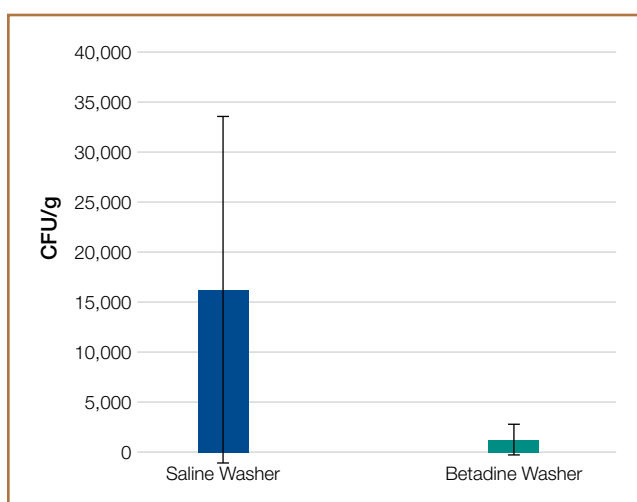


Figure 3. Polyethylene bacterial burden (measured in standardized CFU/g) was decreased in cultures obtained from Betadine-treated washers. The difference was statistically significant ($P = .04$).

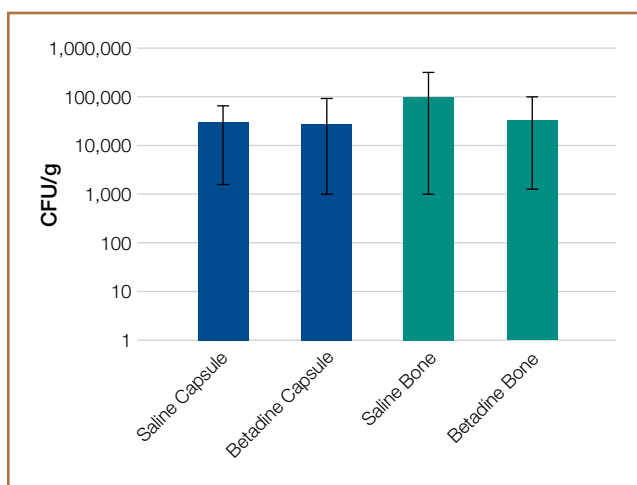


Figure 4. No statistical difference was shown in the bacterial load of soft tissue (homogenized bone and joint capsule cultures) treated with Betadine lavage versus saline lavage ($P = .9$).

phagocytic action by neutrophils. In addition to antibacterial activity, povidone-iodine has antibiofilm activity against *Staphylococcal* species.²⁵ The active ingredient targets the gene that produces biofilm. This correlates to our study in which the largest decrease in bacterial counts was noted on the implants.

The use of Betadine lavage has shown some promise in vivo as well. A prospective randomized controlled trial²⁶ used 3.5% Betadine irrigation to prevent spine infection. No infections occurred in the Betadine group compared with a deep-infection rate of 2.9% in the control group. Brown and colleagues⁸ reviewed 1862 hip and knee arthroplasty cases before the use of Betadine lavage and 688 cases after the use of Betadine lavage and found a decrease in infection rate, from 0.97% to 0.15%. *S aureus* caused 13 of the 18 infections in the control group. These studies^{8,26} used Betadine lavage for prophylaxis and prevention of deep spine and arthroplasty infection. Betadine lavage as a treatment adjunct for acute arthroplasty infection has not been studied clinically. It has the potential to increase isolated incision and débridement success and to improve component survivorship.

Our arthroplasty model mimics an intra-articular environment and accounts for an implant–polyethylene interface.¹⁵ Limitations of our study include the use of MSSA as opposed to MRSA. However, povidone-iodine has the same effects on both MSSA and MRSA.¹² We also treated our postoperative infection with 1 dose of antibiotics and not a course, although it should be noted that the single dose of ceftriaxone allowed us to isolate the independent effect of the Betadine lavage. A baseline level of infection severity could have been measured with cultures obtained at the time of irrigation and débridement. Also, a decrease in CFU does not directly correlate to a clinically significant outcome, such as a defined surgical site infection requiring intervention. Nevertheless, it is noteworthy that the decrease in bacterial counts on the stainless steel screws and polyethylene washers were maintained 1 week after the Betadine lavage.

Conclusion

Dilute Betadine lavage is a simple and inexpensive adjunct for the treatment of acute postoperative arthroplasty infection and may increase the rate of component retention. Additionally, the bactericidal and antibiofilm activities of Betadine may improve the effectiveness of systemic antibiotics. Further clinical investigation is warranted.

Dr. Gilotra is Orthopaedic Surgeon, and Dr. Nguyen and Dr. Jaffe are Orthopaedic Residents, Department of Orthopaedics, University of Maryland, Baltimore, Maryland. Dr. Sterling is Assistant Professor of Orthopaedic Surgery, Department of Orthopaedic Surgery, Johns Hopkins University School of Medicine, Baltimore, Maryland.

Acknowledgment: The authors thank senior editor and writer Dori Kelly, MA, for invaluable assistance with manuscript and figure preparation.

Address correspondence to: Robert Sterling, MD, Department of Orthopaedic Surgery, Johns Hopkins Bayview Medical Center, 4940 Eastern Avenue, Building A, 6th Floor, Baltimore, MD 21224 (tel, 410-550-6893; fax, 410-550-6899; e-mail, rsterli6@jhmi.edu).

Am J Orthop. 2015;44(2):E38-E41. Copyright Frontline Medical Communications Inc. 2015. All rights reserved.

References

- Wilson MG, Kelley K, Thornhill TS. Infection as a complication of total knee-replacement arthroplasty. Risk factors and treatment in sixty-seven cases. *J Bone Joint Surg Am.* 1990;72(6):878-883.
- Ridgeway S, Wilson J, Charlet A, Kafatos G, Pearson A, Coello R. Infection of the surgical site after arthroplasty of the hip. *J Bone Joint Surg Br.* 2005;87(6):844-850.
- Mahomed NN, Barrett JA, Katz JN, et al. Rates and outcomes of primary and revision total hip replacement in the United States medicare population. *J Bone Joint Surg Am.* 2003;85(1):27-32.
- Mahomed NN, Barrett J, Katz JN, Baron JA, Wright J, Losina E. Epidemiology of total knee replacement in the United States Medicare population. *J Bone Joint Surg Am.* 2005;87(6):1222-1228.
- Parvizi J, Zmistowski B, Adeli B. Periprosthetic joint infection: treatment options. *Orthopedics.* 2010;33(9):659.
- Poultides LA, Liaropoulos LL, Malizos KN. The socioeconomic impact of musculoskeletal infections. *J Bone Joint Surg Am.* 2010;92(11):e13.
- Chundamala J, Wright JG. The efficacy and risks of using povidone-iodine irrigation to prevent surgical site infection: an evidence-based review. *Can J Surg.* 2007;50(6):473-481.
- Brown NM, Cipriano CA, Moric M, Sporer SM, Della Valle CJ. Dilute betadine lavage before closure for the prevention of acute postoperative deep periprosthetic joint infection. *J Arthroplasty.* 2012;27(1):27-30.
- Kaysinger KK, Nicholson NC, Ramp WK, Kellam JF. Toxic effects of wound irrigation solutions on cultured tibiae and osteoblasts. *J Orthop Trauma.* 1995;9(4):303-311.
- Haley CE, Marling-Cason M, Smith JW, Luby JP, Mackowiak PA. Bactericidal activity of antiseptics against methicillin-resistant *Staphylococcus aureus*. *J Clin Microbiol.* 1985;21(6):991-992.
- Lacey RW, Catto A. Action of povidone-iodine against methicillin-sensitive and -resistant cultures of *Staphylococcus aureus*. *Postgrad Med J.* 1993;69(3 suppl):S78-S83.
- McLure AR, Gordon J. In-vitro evaluation of povidone-iodine and chlorhexidine against methicillin-resistant *Staphylococcus aureus*. *J Hosp Infect.* 1992;21(4):291-299.
- Suzuki J, Komatsuzawa H, Kozai K, Nagasaka N. In vitro susceptibility of *Staphylococcus aureus* including MRSA to four disinfectants. *ASDC J Dent Child.* 1997;64(4):260-263.
- Yasuda T, Yoshimura S, Katsuno Y, et al. Comparison of bactericidal activities of various disinfectants against methicillin-sensitive *Staphylococcus aureus* and methicillin-resistant *Staphylococcus aureus*. *Postgrad Med J.* 1993;69(3 suppl):S66-S69.
- Craig MR, Poelstra KA, Sherrell JC, Kwon MS, Belzile EL, Brown TE. A novel total knee arthroplasty infection model in rabbits. *J Orthop Res.* 2005;23(5):1100-1104.
- Hartman MB, Fehring TK, Jordan L, Norton HJ. Periprosthetic knee sepsis. The role of irrigation and debridement. *Clin Orthop.* 1991;273:113-118.
- Mont MA, Waldman B, Banerjee C, Pacheco IH, Hungerford DS. Multiple irrigation, debridement, and retention of components in infected total knee arthroplasty. *J Arthroplasty.* 1997;12(4):426-433.
- Azzam KA, Seeley M, Ghanem E, Austin MS, Purtil JJ, Parvizi J. Irrigation and debridement in the management of prosthetic joint infection: traditional indications revisited. *J Arthroplasty.* 2010;25(7):1022-1027.
- Stall AC, Becker E, Ludwig SC, Gelb D, Poelstra KA. Reduction of postoperative spinal implant infection using gentamicin microspheres. *Spine (Phila Pa 1976).* 2009;34(5):479-483.
- Hota B, Ellenbogen C, Hayden MK, Aroutcheva A, Rice TW, Weinstein RA. Community-associated methicillin-resistant *Staphylococcus aureus* skin and soft tissue infections at a public hospital: do public housing and incarceration amplify transmission? *Arch Intern Med.* 2007;167(10):1026-1033.
- Fridkin SK, Hageman JC, Morrison M, et al. Active Bacterial Core Surveillance Program of the Emerging Infections Program Network. Methicillin-resistant *Staphylococcus aureus* disease in three communities. *N Engl J Med.* 2005;352(14):1436-1444.
- Hosman AH, van der Mei HC, Buijstra SK, Busscher HJ, Neut D. Metal-on-metal bearings in total hip arthroplasties: influence of cobalt and chromium ions on bacterial growth and biofilm formation. *J Biomed Mater Res A.* 2009;88(3):711-716.
- Oduwole KO, Glynn AA, Molony DC, et al. Anti-biofilm activity of sub-inhibitory povidone-iodine concentrations against *Staphylococcus epidermidis* and *Staphylococcus aureus*. *J Orthop Res.* 2010;28(9):1252-1256.
- Cheng MT, Chang MC, Wang ST, Yu WK, Liu CL, Chen TH. Efficacy of dilute betadine solution irrigation in the prevention of postoperative infection of spinal surgery. *Spine (Phila Pa 1976).* 2005;30(15):1689-1693.
- Anderson RL, Vess RW, Panlilio AL, Favero MS. Prolonged survival of *Pseudomonas cepacia* in commercially manufactured povidone-iodine. *Appl Environ Microbiol.* 1990;56(11):3598-3600.
- Panlilio AL, Beck-Sague CM, Siegel JD, et al. Infections and pseudoinfections due to povidone-iodine solution contaminated with *Pseudomonas cepacia*. *Clin Infect Dis.* 1992;14(5):1078-1083.