

Comparison of Outcomes and Costs of Tension-Band and Locking-Plate Osteosynthesis in Transverse Olecranon Fractures: A Matched-Cohort Study

Michael H. Amini, MD, Frederick M. Azar, MD, Benjamin R. Wilson, BS, Richard A. Smith, PhD, Benjamin M. Mauck, MD, and Thomas W. Throckmorton, MD

Abstract

To determine if there are significant differences in outcomes and costs between tension-band and locking-plate fixation of transverse olecranon fractures in adults, we retrospectively compared functional outcomes, complications, and costs in 2 cohorts of displaced transverse olecranon fractures. These cohorts (10 patients each) were matched on age and length of follow-up.

There were no significant differences between the groups in range of motion, functional scores, or arthrosis. There were no infections or nonunions in either group. There was no significant difference in rate of implant removal or symptomatic implants, though a trend was found toward a higher rate of both with tension bands. Operative time was significantly ($P = .025$) less for tension-band than locking-plate fixation (55 vs 85 minutes). In the tension-band group, charges were significantly less for implant, index procedure, and overall operative charges including reoperations (\$6598.36 vs \$14,333.46; $P = .001$). If all tension bands and no locking plates had been removed, tension-band fixation still would have cost significantly less (\$7307.31 vs \$14,160.26; $P = .0005$).

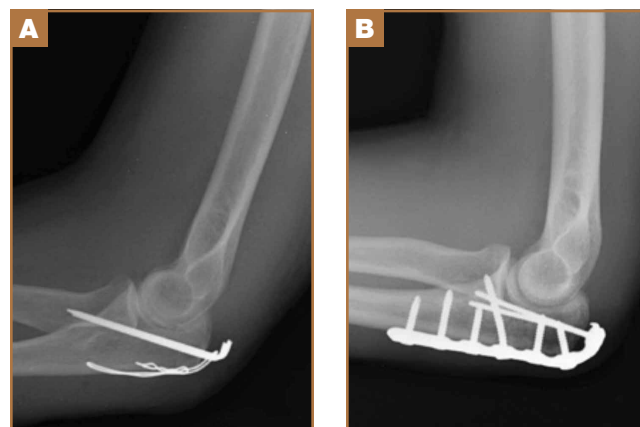
Olecranon fractures are a common injury, representing 10% of all upper extremity fractures.¹ Displaced fractures require fixation to restore anatomical alignment and minimize posttraumatic arthrosis.^{2,3} Multiple surgical techniques have been developed to treat these fractures, with implant choice largely dictated by fracture pattern and associated injuries. Simple, noncomminuted, transverse, proximal fractures can be treated with a tension-band construct, and

fractures that are comminuted, oblique, distal to the midpoint of the sigmoid notch, or associated with complex elbow injuries generally require locking-plate fixation.^{4,5} Although both tension bands and locking plates have been used successfully (Figures 1A, 1B), they remain some of the most frequently removed orthopedic implants, usually because of implant prominence.⁶

Both fixation devices have potential advantages and disadvantages. Tension-band fixation requires relatively “low-tech” instrumentation and implants and, as a result, has less cost and potentially less operative time for application. As it is smaller than a plate-and-screw construct, a tension band may be less prone to prominence, but this has not been substantiated in the literature.⁷⁻¹⁴ Implant migration has been a reported complication of tension-band fixation.^{7,11,13,15}

Locking-plate fixation has been shown to be biomechanically stronger,¹⁶ and some reports have shown fewer repeat operations for implant prominence than with tension-band

Figure 1. Postoperative radiographs of fixation of olecranon fracture with (A) tension-band construct and (B) plate construct.



Authors' Disclosure Statement: Dr. Throckmorton reports that he consults for Biomet and Zimmer and is a member of Biomet's speakers' bureau. The other authors report no actual or potential conflict of interest in relation to this article.

fixation.^{1,8,17-22} Because of more advanced product development and manufacturing, however, it comes at a higher cost. Plate fixation also requires more steps for application, which may require more operative time, and implant prominence has remained a problem, even with modern plates with lower profiles.¹⁹

Previous studies of olecranon fixation have included complex fractures and osteotomies or did not include current-generation precontoured locking plates. We found no other study that compared the outcomes, complications, and costs of tension-band and modern locking-plate fixation of isolated transverse olecranon fractures.

To determine if there are significant differences in outcomes and costs between tension-band and locking-plate fixation of transverse olecranon fractures in adults, we retrospectively compared functional outcomes, complications, and costs in 2 matched cohorts of displaced transverse olecranon fractures. We hypothesized that there would be no differences in functional outcomes, implant prominence, posttraumatic arthrosis, complications, or operative time, but that costs would be less with tension-band fixation.

Materials and Methods

After obtaining institutional review board approval, we retrospectively reviewed the medical records of patients who had undergone fixation of an isolated, transverse, noncomminuted olecranon fracture (Orthopaedic Trauma Association 21B1) at our institution between 2004 and 2011. Inclusion criteria included use of a tension-band construct or a precontoured locking plate, skeletal maturity at time of injury, and minimum 2-year follow-up. Exclusion criteria were open fractures, osteotomies, any other ipsilateral upper extremity fracture, and fractures with comminution, obliquity, or distal location.

Although, based on fracture pattern, tension-band fixation is appropriate for olecranon osteotomies used for distal humeral exposure, we did not include osteotomies because functional outcomes would likely be different from those of true olecranon fractures, in addition to the possibility that the soft-tissue injury from a distal humeral fracture and resultant exposure could result in a different level of implant prominence. To control for demographic variables, we used a cohort design in which patients were matched on age and length of follow-up.

During the study period, we treated 287 olecranon fractures. Forty-nine patients met the inclusion criteria. The study population consisted of 20 patients, 10 in each cohort matched

on age and length of follow-up. There were no statistically significant differences between groups in demographic variables, including dominant arm involved and number of worker's compensation claims (Table 1). Mechanisms of injury were similar in the groups. In the tension-band group, 9 patients fell directly onto their elbow, and 1 fell onto her outstretched hand. In the locking-plate group, 8 patients fell directly onto the elbow, 1 fell onto her outstretched hand, and 1 was injured in a motorcycle accident.

All surgeons, regardless of implant selected, used a posterior incision that curved slightly laterally about the tip of the olecranon. Surgeon preference determined which fixation construct to use. Tension-band fixation was performed using 2 bicortical Kirschner wires and a stainless-steel wire through a distal drill hole to complete the tension band. Of the 10 locking-plate constructs used, 4 were PERI-LOC olecranon locking plates (Smith & Nephew), 3 were LCP olecranon plates (Synthes), and 3 were periarticular proximal ulna locking plates (Zimmer).

All returning patients were seen by either Dr. Amini or Mr. Wilson and underwent range of motion (ROM) measurement with a goniometer; assessment for subjective and objective implant prominence (graded none, mild, moderate, or severe/already had implant removed); and functional scoring using the Mayo Elbow Performance Score (MEPS) and the Quick Disability of the Arm, Shoulder, and Hand (QDASH). Results were classified excellent (MEPS, >90), good (75-89), fair (60-74), and poor (<60).²³

Anteroposterior and lateral radiographs of the elbow were obtained at follow-up and were examined for maintenance/integrity of implants, radiographic union, and posttraumatic arthrosis. Arthrosis was graded using the Broberg and Morrey²⁴ classification: grade 0 (normal elbow), grade 1 (slight joint-space narrowing with minimal osteophyte formation), grade 2 (moderate joint-space narrowing with moderate osteophyte formation), grade 3 (severe degenerative changes with gross destruction of joint).

Medical records were examined to determine surgery time. Billing information was examined to determine charges related to each operation, specifically the charge for the implants and the overall charge for the operation, which included anesthesia charges. Subsequent operations were included as applicable.

Student t test was used to compare differences in normative data, and Pearson χ^2 test to compare differences in categorical data. Differences with $P < .05$ were considered significant.

Results

There were no clinically or statistically significant differences in ROM or functional outcomes (Table 2). According to MEPS, results were excellent in 8 and good in 2 patients in the tension-band group and excellent in 7 and good in 3 patients in the locking-plate group.

In patients who had implants removed, average time to subsequent procedure was 6.2 months, and all patients who underwent implant removal did so before 1-year follow-up. Implant removal was required in 4 tension-band patients and 1 locking-plate patient ($P = .12$). Similarly, 7 tension-band

Table 1. Patient Demographics

Demographic	Tension Band	Locking Plate	P
Age, y	51.7	55.2	.57
Follow-up, y	5.1	3.5	.09
Dominant arm	3/10	1/10	.58
Worker's compensation claim	1/10	1/10	NA

patients (including those with implants removed) and 3 locking-plate patients had implant-related symptoms, with the difference trending ($P = .07$) toward significance (Table 2).

Patients who elected to have their implants removed tended to be younger than those who did not (45.7 vs 56.0 years); the difference ($P = .14$) was not significant. Worker's compensation status did not affect the decision to undergo implant removal. At final follow-up, there were no differences in ROM or functional outcomes between patients who had implants removed and those who did not. No variable predicted which patients had implants removed or not (Table 3).

Implant charges were \$207.97 for the tension-band cohort and \$6688.52 for the locking-plate cohort ($P < .0001$). Operative charges for the index procedures were \$5171.06 for tension-band fixation and \$14,160.26 for locking-plate fixation ($P < .0001$). Overall operative charges, including charges for subsequent operations, were \$6598.36 in the tension-band

cohort and \$14,333.46 in the locking-plate cohort ($P = .001$). In a comparison of combined charges for index procedure and implant removal (excluding other repeat operations), charges were \$6025.56 for the tension-band cohort and \$14,333.46 for the locking-plate cohort ($P = .0002$). Even if all patients with tension-band fixation and no patients with locking-plate fixation had implant removal, mean charges for all operative care would still be significantly ($P = .0005$) less in the tension-band cohort than in the locking-plate cohort (\$7307.31 vs \$14,160.26) (Table 4).

Surgery time was significantly ($P = .025$) less for tension-band fixation than for locking-plate fixation (55.3 vs 85.4 minutes) (Table 2).

Four tension-band patients and 3 locking-plate patients had radiographic evidence of grade 1 posttraumatic arthrosis ($P = .64$). None required subsequent procedures. Patients with posttraumatic arthrosis had slightly less flexion, but there was no difference in overall flexion-extension arc or functional outcomes between patients with and without arthrosis (Table 5).

The locking-plate cohort had no other complications, and the tension-band cohort had 3. In 1 tension-band patient, the wire disengaged from the Kirschner wires. The fracture healed, but a subsequent procedure was required for symptomatic implant prominence (Figures 2A–2C). Another tension-band patient developed both posttraumatic arthrofibrosis and cubital tunnel syndrome, in addition to a prominent implant. She underwent capsular release, ulnar nerve transposition, and implant removal. At final follow-up, motion was improved, and ulnar nerve symptoms were resolved. There were no in-

Table 2. Outcomes

Outcome	Tension Band	Locking Plate	P
Flexion	140°	144°	.10
Extension	8°	12°	.27
Flexion/extension arc	132°	132°	NA
Supination	78°	76°	.67
Pronation	75°	75°	NA
Mayo Elbow Performance Score	97	95	.51
Quick Disability of the Arm, Shoulder, and Hand	10.0	10.5	.95
Implant removal	4/10	1/10	.12
Implant prominence	7/10	3/10	.07
Arthrosis	4/10	3/10	.64
Surgery time, min	55.3	85.4	.02

Table 3. Comparison of Patients Who Had Implants Removed and Patients Who Retained Implants

	Implant Removed	Implant Retained	P
Age, y	45.7	56.0	.14
Follow-up, y	4.2	4.4	.91
Dominant arm	3/10	1/10	.33
Worker's compensation claim	1/10	7/10	.52
Flexion	141°	143°	.53
Extension	8°	11°	.55
Mayo Elbow Performance Score	97	96	.71
Quick Disability of the Arm, Shoulder, and Hand	9.5	10.5	.91

Table 4. Analysis of Charges

	Tension Band	Locking Plate	P
Implants	\$207.97	\$6688.52	<.0001
Index operation	\$5171.06	\$14,160.26	<.0001
Index and implant removal	\$6025.56	\$14,333.46	.0002
Index and all reoperations	\$6598.36	\$14,333.46	.001
Removal of all tension bands vs no plates (hypothetical)	\$7307.31	\$14,160.26	.0005

Table 5. Comparison of Outcomes in Patients Who Developed Arthrosis and Patients Who Did Not

	Arthrosis	No Arthrosis	P
Flexion	138°	144°	.004
Extension	9°	11°	.66
Flexion/extension arc	129°	134°	.30
Mayo Elbow Performance Score	98	95	.37
Quick Disability of the Arm, Shoulder, and Hand	9.1	10.8	.81

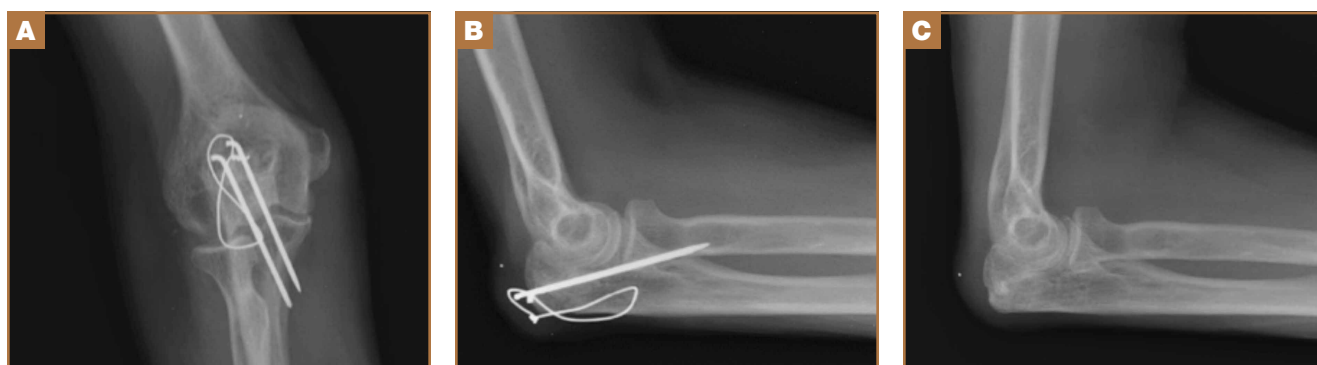

Figure 2. (A) Anteroposterior and (B) lateral radiographs of tension-band wire that disengaged from longitudinal Kirschner wires. (C) Radiograph after removal of implant because of prominence.

fections in either group. Overall, there were no statistically significant differences in complications between groups.

Discussion

We conducted this study to determine differences between tension-band and locking-plate fixation of isolated, closed, noncomminuted, transverse olecranon fractures. Few studies have directly compared tension-band and locking-plate fixation,^{8,10,19,25} particularly in reference to outcomes of functional scores, implant prominence, complications, operative time, and cost-effectiveness. We found no study that clinically compared these implants since the advent of precontoured locking plates, and no study that compared results in similar fracture patterns. In our study, we found no differences in functional or radiographic outcomes between groups, but significant differences in charges and overall cost of care.

Our findings suggest that patients return to high functional level an average of 4.3 years after fixation of an olecranon fracture with either a tension band or a locking plate. Both cohorts achieved QDASH scores equivalent to normative values for the general population,²⁶ and all patients in both cohorts achieved either good or excellent results based on MEPS values.²³ This is comparable to reported functional outcomes in the literature, with previous reports suggesting 86% to 92% of patients obtain good or excellent results.^{1,7,8,12,14,17,18,27} The rate of posttraumatic arthrosis in both cohorts was low, and, when present, arthrosis was radiographically mild (no patient had grade 2 or 3 arthrosis). Patients with and without radiographic evidence of arthrosis had similar ROM and functional outcomes.

Our findings also suggest a trend toward fewer implant-related symptoms and less need for implant removal in patients treated with locking plates. Although both implants have high rates of prominence requiring removal, most studies support our findings that tension bands are more prominent than locking plates. Fixation has been reported to cause prominence requiring removal in 42% to 82% of patients with tension bands⁷⁻¹⁴ and 0% to 47% of patients with locking plates.^{1,8,17,18,20-22,28} It is important to note that many earlier studies either were conducted before the advent of precontoured locking plates or were not comparative.^{1,7,9-14,17,18,20-22,28} In one

recent study, however, Edwards and colleagues¹⁹ surveyed 138 patients and found very similar implant removal rates: 63.6% for tension bands and 62.5% for locking plates. Nevertheless, implant removal rates for fixation of olecranon fractures remain high, regardless of implant used.

Our data did not reveal any difference in ROM or functional outcomes between patients who had and did not have implants removed. This suggests, first, that QDASH and MEPS may not be sensitive in identifying patients with implant prominence, as neither questionnaire incorporates implant prominence into its scoring, and, second, that implant removal does not significantly impair ROM. As a result, surgeons should consider asking patients specifically about symptoms of prominent implants once there is convincing evidence of union and counseling them about implant removal if appropriate.

To our knowledge, the differences in cost and operative time between tension-band and locking-plate fixation have not been previously reported. Our data suggest that the financial differences resulted mainly from implant charges; overall, tension-band fixation was roughly half the cost of locking-plate fixation. In addition, in patients who eventually had implants removed, the cost of implant removal was relatively small compared with the cost of the initial fixation in both cohorts. As a result, even if all patients in the tension-band cohort and no patients in the locking-plate cohort had implants removed, tension-band fixation and subsequent implant removal would still cost half as much as locking-plate fixation without implant removal. Moreover, fixation with a tension band took roughly 30 minutes less than fixation with a plate. Less time in the operating room likely contributed to the additional cost savings realized with tension-band fixation beyond those directly resulting from implant cost.

The strength of this study lies in the homogeneity of cohorts. Each cohort was matched primarily on age and secondarily on length of follow-up. All patients had closed, proximal, transverse fractures without comminution, and we excluded olecranon osteotomies as these represent an entity different from true fractures. Fractures with comminution or distal extension may represent more severe injuries, and functional scores, complications, hardware prominence, and operative

time might have been affected by inclusion of these fractures. Further, there were no infections in either group to skew the rate of implant prominence or removal.

The weaknesses of the study lie in its limited sample sizes, retrospective design, and lack of long-term follow-up. Group size was limited by our attempts to create homogenous cohorts. As a result, some patients were not included as participants because of strict exclusion criteria. Most notably, we excluded any fracture not appropriate for tension-band fixation, as well as open fractures and osteotomies. Despite the retrospective nature of the study, all patients were examined by the investigators at final follow-up (minimum, 2 years) for the purpose of this study. It is possible that these functional results may not be sustained over the long term, as the risk for posttraumatic arthrosis in articular injuries builds with time. Although some patients may want to have implants removed later, all our study patients who had implants removed had them removed within 1 year, and all 20 patients were reached at minimum 2-year follow-up. Thus, it is unlikely but possible that some of the other study patients will elect to have implants removed.

Dr. Amini is a Shoulder & Elbow Fellow, Cleveland Clinic, Cleveland, Ohio. Dr. Amini was an Orthopaedic Surgery Resident at the University of Tennessee–Campbell Clinic at the time the article was written. Dr. Azar is Professor, Department of Orthopaedic Surgery and Biomedical Engineering, University of Tennessee–Campbell Clinic, Memphis, Tennessee. Mr. Wilson is Medical Student, University of Tennessee Center for the Health Sciences, Memphis, Tennessee. Dr. Smith is Professor, Dr. Mauck is Instructor, and Dr. Throckmorton is Associate Professor, Department of Orthopaedic Surgery and Biomedical Engineering, University of Tennessee–Campbell Clinic, Memphis, Tennessee.

Address correspondence to: Thomas W. Throckmorton, MD, Department of Orthopaedic Surgery and Biomedical Engineering, University of Tennessee–Campbell Clinic, 1211 Union Ave, Suite 510, Memphis, TN 38104 (tel, 901-759-3270; fax, 901-759-3278; email, tthrockmorton@campbellclinic.com).

Am J Orthop. 2015;44(7):E211-E215. Copyright Frontline Medical Communications Inc. 2015. All rights reserved.

References

- Buijze G, Kloen P. Clinical evaluation of locking compression plate fixation for comminuted olecranon fractures. *J Bone Joint Surg Am.* 2009;91(10):2416-2420.
- Newman SD, Mauffrey C, Krikler S. Olecranon fractures. *Injury.* 2009;40(6):575-581.
- Veillette CJ, Steinmann SP. Olecranon fractures. *Orthop Clin North Am.* 2008;39(2):229-236.
- Baecher N, Edwards S. Olecranon fractures. *J Hand Surg Am.* 2013;38(3):593-604.
- Hak DJ, Golladay GJ. Olecranon fractures: treatment options. *J Am Acad Orthop Surg.* 2000;8(4):266-275.
- Busam ML, Esther RJ, Obremsky WT. Hardware removal: indications and expectations. *J Am Acad Orthop Surg.* 2006;14(2):113-120.
- Chalidis BE, Sachinis NC, Samoladas EP, Dimitriou CG, Pournaras JD. Is tension band wiring technique the “gold standard” for the treatment of olecranon fractures? A long term functional outcome study. *J Orthop Surg Res.* 2008;3:9.
- Hume MC, Wiss DA. Olecranon fractures: a clinical and radiographic comparison of tension-band wiring and plate fixation. *Clin Orthop Relat Res.* 1992;(285):229-235.
- Karlsson MK, Hasserius R, Besjakov J, Karlsson C, Josefsson PO. Comparison of tension-band and figure-of-eight wiring techniques for treatment of olecranon fractures. *J Shoulder Elbow Surg.* 2002;11(4):377-382.
- Lindhovius AL, Brouwer KM, Doornberg JN, Ring DC, Kloen P. Long-term outcome of operatively treated fracture-dislocations of the olecranon. *J Orthop Trauma.* 2008;22(5):325-331.
- Macko D, Szabo RM. Complications of tension-band wiring of olecranon fractures. *J Bone Joint Surg Am.* 1985;67(9):1396-1401.
- Romero JM, Miran A, Jensen CH. Complications and re-operation rate after tension-band wiring of olecranon fractures. *J Orthop Sci.* 2000;5(4):318-320.
- Rommens PM, Schneider RU, Reuter M. Functional results after operative treatment of olecranon fractures. *Acta Chir Belg.* 2004;104(2):191-197.
- Villanueva P, Osorio F, Commessatti M, Sanchez-Sotelo J. Tension-band wiring for olecranon fractures: analysis of risk factors for failure. *J Shoulder Elbow Surg.* 2006;15(3):351-356.
- Sahajpal D, Wright TW. Proximal ulna fractures. *J Hand Surg Am.* 2009;34(2):357-362.
- Rouleau DM, Sandman E, van Riet R, Galatz LM. Management of fractures of the proximal ulna. *J Am Acad Orthop Surg.* 2013;21(3):149-160.
- Anderson ML, Larson AN, Merten SM, Steinmann SP. Congruent elbow plate fixation of olecranon fractures. *J Orthop Trauma.* 2007;21(6):386-393.
- Bailey CS, MacDermid J, Patterson SD, King GJ. Outcome of plate fixation of olecranon fractures. *J Orthop Trauma.* 2001;15(8):542-548.
- Edwards SG, Cohen MS, Lattanza LL, et al. Surgeon perceptions and patient outcomes regarding proximal ulna fixation: a multicenter experience. *J Shoulder Elbow Surg.* 2012;21(12):1637-1643.
- Munoz-Mahamud E, Fernandez-Valencia JA, Riba J. Plate osteosynthesis for severe olecranon fractures. *J Orthop Surg.* 2010;18(1):80-84.
- Simpson NS, Goodman LA, Jupiter JB. Contoured LCDC plating of the proximal ulna. *Injury.* 1996;27(6):411-417.
- Tejwani NC, Garnham IR, Wolinsky PR, Kummer FJ, Koval KJ. Posterior olecranon plating: biomechanical and clinical evaluation of a new operative technique. *Bull Hosp Jt Dis.* 2002-2003;61(1-2):27-31.
- Morrey BF, An KN. Functional evaluation of the elbow. In: Morrey BF, Sanchez-Sotelo J, eds. *The Elbow and Its Disorders.* 4th ed. Philadelphia, PA: Elsevier; 2008:87-88.
- Broberg MA, Morrey BF. The results of delayed excision of the radial head for fracture. *J Bone Joint Surg Am.* 1986;68(5):669-674.
- Horne JG, Tanzer TL. Olecranon fractures: a review of 100 cases. *J Trauma.* 1981;21(6):469-472.
- Hunsaker FG, Cioffi DA, Amadio PC, Wright JG, Caughlin B. The American Academy of Orthopaedic Surgeons outcomes instruments: normative values from the general population. *J Bone Joint Surg Am.* 2002;84(2):208-215.
- Ikeda M, Fukushima Y, Kobayashi Y, Oka Y. Comminuted fractures of the olecranon. Management by bone graft from the iliac crest and multiple tension-band wiring. *J Bone Joint Surg Br.* 2001;83(6):805-808.
- Erturer RE, Sever C, Sonmez MM, Ozcelik IB, Akman S, Ozturk I. Results of open reduction and plate osteosynthesis in comminuted fracture of the olecranon. *J Shoulder Elbow Surg.* 2011;20(3):449-454.

This paper will be judged for the Resident Writer's Award.