

# Madelung Deformity and Extensor Tendon Rupture

Gholam Hossain Shahcheraghi, MD, FRCSC, Maryam Peyman, MD, and Kamran Mozafarian, MD

## Abstract

Extensor tendon rupture in chronic Madelung deformity, as a result of tendon attrition on the dislocated distal ulna, is a rare occurrence. It is, however, seen more often in rheumatoid arthritis. There are few case reports in the English-language literature on this issue. We report a case of multiple tendon ruptures in a previously undiagnosed Madelung deformity.

**E**xtensor tendon rupture in chronic Madelung deformity, as a result of tendon attrition on the dislocated distal ulna, occurs infrequently. However, it is often seen in patients with rheumatoid arthritis. This issue has been reported in only a few English-language case reports. Here we report a case of multiple tendon ruptures in a previously undiagnosed Madelung deformity. The patient provided written informed consent for print and electronic publication of this case report.

## Case Report

A 56-year-old active woman presented with 50 days' inability to extend the fourth and fifth fingers of her dominant right hand. The loss of finger extension progressed, over several weeks, to involve the third finger as well. The first 2 tendon ruptures had been triggered by lifting a light grocery bag, when she noticed a sharp sudden pain and "pop." The third rupture occurred spontaneously with a snapping sound the night before surgery.

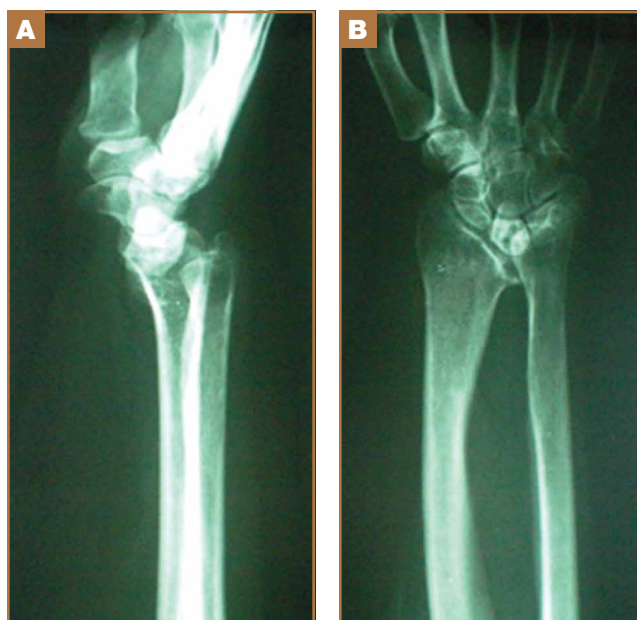
The patient had observed some prominence on the ulnar side of her right wrist since childhood but had never experienced any pain or functional disability. There was neither history of trauma, inflammatory disease, diabetes mellitus, or infection, nor positive family history of similar wrist deformity.

The physical examination showed a dorsally subluxated distal radioulnar joint, prominent ulnar styloid, and mild ulnar and volar deviation of the wrist along with limitation of wrist dorsiflexion. Complete loss of active extension of the 3 ulnar fingers was demonstrated, while neurovascular status and all other hand evaluations were normal. The wrist radiographs con-

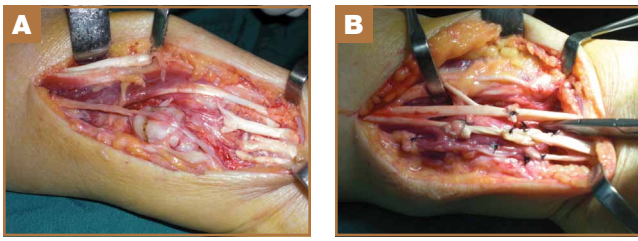
firmed the typical findings of Madelung deformity (Figure 1).

Repair of the ruptured tendons and resection of the prominent distal ulna (Darrach procedure) was planned. (Given the patient's age and evidence of degenerative changes in the radiocarpal joint, correction of the Madelung deformity did not seem necessary). At time of surgery, the recently ruptured third finger extensor tendon was easily found and approximated, and end-to-end repair was performed. The fourth and fifth fingers, however, had to be fished out more proximally from dense granulation tissue. After the distal ulna was resected for a distance of 1.5 cm, meticulous repair of the ulnar collateral ligament and the capsule and periosteum over the end of the ulna was performed. Then, for grafting of the ruptured tendons, the extensor indicis proprius tendon was isolated and transected at the second metacarpophalangeal joint level. A piece of this tendon was used as interpositional graft for the fourth extensor tendon, and the main tendon unit was transferred to the fifth finger extensor. The extensor digiti quinti tendon, which was about to rupture, was further reinforced

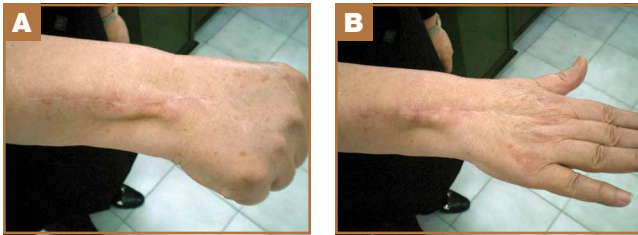**Figure 1.** Right wrist radiographs with the features of Madelung deformity: (A) lateral view, (B) anteroposterior view.



**Authors' Disclosure Statement:** The authors report no actual or potential conflict of interest in relation to this article.



**Figure 2.** (A) Operative findings: dorsal dislocation of the ulnar head and ruptured tendons. (B) Tendon repair and grafts.



**Figure 3.** (A) The wrist deformity has been corrected, (B) with full active extension of fingers.

by suturing it side to side to the muscle and tendon of the extensor indicis proprius (Figure 2).

Postoperatively, the wrist was kept in extension in a cast for 3 weeks while the fingers were free for active movement. A removable wrist splint was used for an additional month. At 3-month follow-up, the patient had regained full and strong finger extension and wrist motion.

At 3-year follow-up, the patient was pain-free, and had full extension of all fingers, full forearm rotation, and near-normal motion (better than her preoperative motion). The grip power on the operated right hand was 215 N, and pinch power was 93 N. (The values for the left side were 254 N and 83 N, respectively, using the Jamar hydraulic hand dynamometer [Patterson Medical].) The patient has had no additional tendon rupture (Figure 3).

## Discussion

Madelung deformity was first described by Madelung in 1878 and several cases have reported this deformity. However, extensor tendon rupture caused by Madelung deformity is very rare, reported in few cases.<sup>1</sup>

Extensor tendon rupture caused by chronic Madelung deformity has been reported few times in the English literature. Goodwin<sup>1</sup> apparently published the first report of such an occurrence in 1979. Ducloyer and colleagues<sup>2</sup> from France reported 6 cases of extensor tendon rupture as a result of inferior distal radioulnar joint deformity of Madelung. Jebson and colleagues<sup>3</sup> reported bilateral spontaneous extensor tendon ruptures in Madelung deformity in 1992.

The mechanism of tendon rupture seems to be mechanical, resulting from continuous rubbing and erosion of tendons over the deformed ulnar head, which has a rough irregular surface<sup>4</sup>

and leads to fraying of the tendons and eventual rupture and retraction of the severed tendon ends. This rupture usually progresses stepwise from more medial to the lateral tendons.<sup>2</sup> Older patients are, therefore, subject to chronic repetitive attritional trauma leading to tendon rupture.

Tendons may rupture as a result of a variety of conditions, such as chronic synovitis in rheumatoid arthritis, systemic lupus erythematosus, mixed connective tissue disease, or crystal deposition in gout.<sup>5-8</sup> Some other metabolic or endocrine conditions that involve tendon ruptures include diabetes mellitus, chronic renal failure, and hyperparathyroidism. Steroid injection into the tendons also has a detrimental effect on tendon integrity and may cause tendon tear.<sup>9</sup> Mechanical factors, such as erosion on bony prominences, are well-known etiologies for tendon rupture, as commonly seen in rheumatoid arthritis, and have been reported in Kienböck disease,<sup>10</sup> thumb carpometacarpal arthritis,<sup>11</sup> Colles fracture, scaphoid fracture nonunion,<sup>12</sup> and Madelung deformity.

## Conclusion

Our case reflects the usual middle-aged female presentation of such a tendon rupture. The tendon ruptures were spontaneous in the reported order of ulnar to radial, beginning with the little and ring fingers, and progressed radially. The patient had isolated Madelung deformity with no other sign of dyschondrosteosis<sup>13</sup> or dwarfism, conditions commonly mentioned in association with Madelung deformity. This case report should raise awareness about possible tendon rupture in any chronic case of Madelung deformity.

Dr. Shahcheraghi is Professor of Orthopedics, Shiraz University of Medical Sciences, Shiraz, Iran. Dr. Peyman is Research Assistant, Dena Hospital, Shiraz, Iran. Dr. Mozafarian is Associate Professor of Orthopedics, Shiraz University of Medical Sciences, Shiraz, Iran.

Address correspondence to: Gholam Hossain Shahcheraghi, MD, FRCSC, PO Box 315-71955, Shiraz, Iran (tel, 00987136240678; fax, 00987136490433; email, gshahcheraghi@yahoo.ca).

*Am J Orthop.* 2015;44(7):E242-E244. Copyright Frontline Medical Communications Inc. 2015. All rights reserved.

## References

1. Goodwin DR, Michels CH, Weissman SL. Spontaneous rupture of extensor tendons in Madelung's deformity. *Hand.* 1979;11(1):72-75.
2. Ducloyer P, Leclercq C, Lisfrance R, Saffar P. Spontaneous rupture of the extensor tendons of the fingers in Madelung's deformity. *J Hand Surg Br.* 1991;16(3):329-333.
3. Jebson PJ, Blair WF. Bilateral spontaneous extensor tendon ruptures in Madelung's deformity. *J Hand Surg Am.* 1992;17(2):277-280.
4. Schulstad I. Madelung's deformity with extensor tendon rupture. Case report. *Scand J Plast Reconstr Surg.* 1971;5(2):153-155.
5. Gong HS, Lee JO, Baek GH, et al. Extensor tendon rupture in rheumatoid arthritis: a survey of patients between 2005 and 2010 at five Korean hospitals. *Hand Surg.* 2012;17(1):43-47.
6. Oishi H, Oda R, Morisaki S, Fujiwara H, Tokunaga D, Kubo T. Spontaneous tendon rupture of the extensor digitorum communis in systemic lupus erythematosus. *Mod Rheumatol.* 2013;23(3):608-610.
7. Kobayashi A, Futami T, Tadano I, Fujita M. Spontaneous rupture of extensor tendons at the wrist in a patient with mixed connective tissue disease. *Mod Rheumatol.* 2002;12(3):256-258.
8. Iwamoto T, Toki H, Ikari K, Yamanaka H, Momohara S. Multiple extensor tendon ruptures caused by tophaceous gout. *Mod Rheumatol.* 2010;20(2): 210-212.

9. Nquyen ML, Jones NF. Rupture of both abductor pollicis longus and extensor pollicis brevis tendon after steroid injection for de quervain tenosynovitis. *Plast Reconstr Surg*. 2012;129(5):883e-886e.
10. Hernández-Cortés P, Pajares-López M, Gómez-Sánchez R, Garrido-Gómez, Lara-García F. Rupture of extensor tendon secondary to previously undiagnosed Kienböck disease. *J Plast Surg Hand Surg*. 2012;46(3-4):291-293.
11. Apard T, Marcucci L, Jarriges J. Spontaneous rupture of extensor pollicis longus in isolated trapeziometacarpal arthritis. *Chir Main*. 2011;30(5):349-351.
12. Harvey FJ, Harvey PM. Three rare causes of extensor tendon rupture. *J Hand Surg Am*. 1989;14(6):957-962.
13. Duro EA, Prado GS. Clinical variations in Léri-Weill dyschondrosteosis. *An Esp Pediatr*. 1990;33(5):461-463.