

# Closed Rupture of the Flexor Profundus Tendon of Ring Finger: Case Report and Treatment Recommendations

Eitan Melamed, MD, Steven J. Fineberg, MD, and Steven Beldner, MD

## Abstract

Zone III midsubstance flexor tendon rupture without underlying pathology is rare. The most common mechanism of injury for a spontaneous rupture is forced extension of an actively flexed distal interphalangeal joint.

We describe a patient who experienced closed midsubstance zone III rupture of the flexor digitorum profundus (FDP) tendon of the ring finger at the lumbrical origin in the palm while lifting a heavy object. On exploration, there was no evidence of underlying tendon pathology, and primary end-to-end repair of the FDP was possible. This case highlights the importance of correct preoperative clinical localization of the rupture level, as well as a suggested surgical plan in equivocal cases.

Flexor tendons are considered the strongest component of the musculotendinous unit; they generally do not rupture unless weakened by an underlying pathologic condition.<sup>1</sup> According to traditional teaching, when the musculotendinous unit is subjected to excessive forces, failure invariably occurs at the tendon insertion, at the musculotendinous junction, within the muscle substance, or at its origin from the bone before the tendon itself ruptures.<sup>1</sup>

Midsubstance tears in nonrheumatoid patients are less frequent and are typically attributable to an underlying cause.<sup>2</sup> Possible pathologic conditions include, but are not limited to, osteoarthritis of the pisotriquetral joint,<sup>3</sup> nonunion fracture of the hook of the hamate,<sup>4</sup> lunate dislocation,<sup>5</sup> accessory carpal bone,<sup>6</sup> gouty infiltration of the flexor tendon,<sup>7</sup> and tumor.<sup>8</sup> In 1960, Boyes and colleagues<sup>9</sup> presented a series of 80 flexor tendon ruptures in 78 patients over a 13-year period. Only 3 cases had no identifiable cause. The authors recommended using the term *spontaneous* for those ruptures that occur within the tendon substance without underlying or associated pathologic changes.

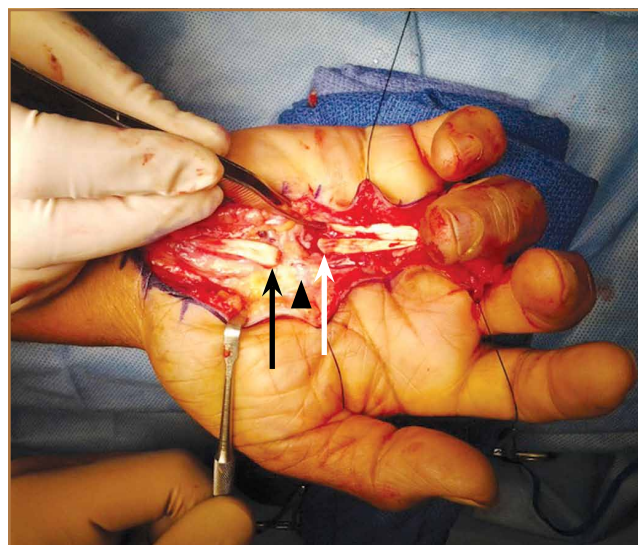
We describe a patient with spontaneous rupture of the flexor digitorum profundus (FDP) tendon at zone III, satisfying

Boyes' definition of the term *spontaneous*. The patient provided written informed consent for print and electronic publication of this case report.

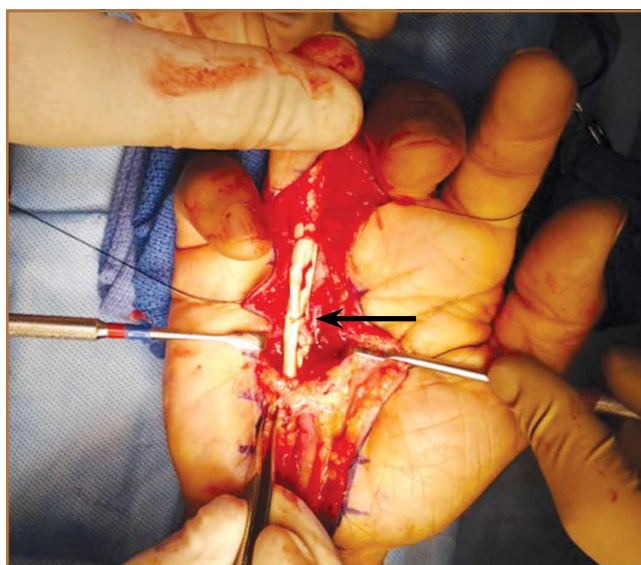
## Case Report

A 65-year-old, right-handed manual worker was assessed in our hand clinic 3 days after he felt a cramp in his left palm while lifting a heavy object. Shortly thereafter, he noted he could not flex his ring finger distal interphalangeal (DIP) joint. He could not recall any previous injury to his finger. No predisposing pathologic conditions or bone abnormalities were identified. Clinically, there was no tenderness, swelling, or ecchymosis evident. He had full passive range of motion (ROM) of his ring finger, and proximal interphalangeal (PIP) joint active ROM was 0/110°; however, he had no activity of the FDP of the ring finger. Preoperative radiographs were normal. The hook of the hamate was clinically and radiographically normal.

**Figure 1.** Surgical findings. The black arrow indicates the flexor digitorum profundus (FDP) proximal stump. The white arrow indicates the FDP distal stump, which appears to have been cut sharply as with a knife. The superficial palmar arch (black arrowhead) occupies the space between the stumps.



**Authors' Disclosure Statement:** The authors report no actual or potential conflict of interest in relation to this article.



**Figure 2.** Surgical repair site (black arrow), showing end-to-end repair of the tendon stumps, as well as side-to-side tenodesis to the intact ring flexor superficialis tendon.

A preoperative diagnosis of FDP avulsion from the distal phalanx was made, and the operation was carried out 16 days after injury. Surgical exploration started in zone II and extended proximally into the distal palmar crease, but no stump was found in either location. Therefore, exploration was carried out to the midpalmar region, revealing the tendon rupture in zone III, in the region of the origin of the ring finger lumbrical muscle (Figure 1). The flexor digitorum superficialis tendon was intact. Macroscopically, both tendon and carpal tunnel appeared normal, with no evidence of tendon attrition; thus, the tendon was not sent for histologic examination. The ends of the ruptured FDP tendon to the ring finger were at the level of the superficial palmar arch, with the distal end appearing as though it had been cut sharply with a knife. Because of the short period of time from injury to exploration, delayed primary tendon repair was possible, along with side-to-side tenodesis to the intact ring finger flexor superficialis tendon in the palm (Figure 2). Two days after surgery, the patient started a controlled mobilization program using the Duran method.<sup>10</sup>

At final follow-up of 18 months, total active motion was 126°, which corresponds to a good outcome, according to the Strickland and Glogovac criteria.<sup>11</sup> Grip strength was 50 kg, which was 84% of grip strength on the uninjured side. The patient was back to recreational activity but had not returned to work.

## Discussion

Most flexor tendon ruptures result from avulsion of the FDP tendon at its distal phalanx insertion, commonly known as *Jersey finger*. However, true midsubstance spontaneous ruptures are infrequent. Reports of spontaneous tendon ruptures of all types, including those of the hand, have increased in incidence in most countries.<sup>12</sup> Bois and colleagues,<sup>13</sup> who have reviewed the literature over a 50-year period, found a total of 50 spon-

taneous ruptures of “normal” flexor tendon in 43 cases. The authors point to unique historical and physical examination findings that help differentiate spontaneous tendon ruptures from the more common FDP avulsions. Such findings include the sensation of a pop or snap, or a sudden sharp pain or cramp within the palmar region. In contrast, most avulsion ruptures cause discomfort within the region of the digit. In type I avulsion injuries of the FDP tendon, the proximal tendon stump usually retracts proximal to the digital tendon sheath, causing a tender mass in the palm.<sup>14</sup> Flexor digitorum profundus tendon avulsions, however, are not typically associated with a snap or pop in the palm. When spontaneous ruptures of the hand occur, they typically involve the profundus tendon of the small finger, in the area of the lumbrical origin.<sup>13</sup>

In equivocal cases when the site of rupture is uncertain, ultrasound and magnetic resonance imaging may assist in making the diagnosis and provide important preoperative information for surgical decision-making and planning; this information may decrease postoperative morbidity by minimizing surgical dissection.

The etiology of spontaneous ruptures is incompletely understood. For any rupture of the ulnar flexor tendons, the hook of the hamate should be examined to rule out a previous fracture as a cause of tendon attrition.<sup>15</sup> Tendon vascularization may be a cause for tendon rupture in the hand. When the blood supply of the lumbrical muscles was examined in 100 upper extremities from human cadavers using vascular injection studies,<sup>16</sup> it was discovered that each lumbrical muscle received its arterial supply from 4 sources: the superficial palmar arch, the common palmar digital artery, the deep palmar arch, and the dorsal digital artery. There were no anastomoses between the networks supplying the lumbrical muscles and the FDP tendons within the palm, suggesting a possible watershed zone between the FDP tendon and lumbrical muscle origin. The patient described in this case had the tendon rupture in the area of potential hypovascularity at the lumbrical origin.

Important factors in the decision-making process for surgical treatment include the length of time between rupture and treatment, the site of rupture, and the condition of the ruptured tendon ends. Patients who present in the first 3 weeks of injury can be treated by primary tendon repair, provided that the ruptured tendon ends are not significantly frayed or attenuated. For patients presenting more than 3 weeks after injury, interposition tendon grafts or tendon transfers are suitable options for ruptures in zone III. Distal interphalangeal joint arthrodesis is another alternative in specific cases where reconstruction is not possible. In this case, direct end-to-end repair was possible, as well as tenodesis to the intact ring finger superficialis in order to prevent stretching of the repair.

Localizing the level of the tendon rupture clinically is difficult. When the site of the profundus tendon rupture is uncertain, and there is no tenderness in zone I or the PIP joint, the first incision should be made at the metacarpophalangeal joint level. This first incision will indicate if the rupture occurred in zone III. If the tendon is intact at that location, then the next incision should be at the level of the PIP joint.

## Conclusion

We report a patient treated for spontaneous rupture of the flexor tendon in zone III. He was treated in the acute setting with direct tendon repair. It is important to consider spontaneous rupture of the tendon in patients presenting with a snap/pop and the sudden inability to flex a finger. A tendon rupture can be diagnosed as spontaneous in the absence of an underlying pathologic condition such as rheumatoid arthritis, gout, or occult carpal fractures. In the acute setting, these may be repaired primarily; however, if presenting after a few weeks, alternative surgical options, including interposition tendon grafts, tendon transfer, and DIP joint arthrodesis, should be considered.

Dr. Melamed is Fellow, Division of Hand Surgery, Beth Israel Medical Center, New York, New York. Dr. Fineberg is Resident Physician, Department of Orthopaedic Surgery, New York Medical College, Valhalla, New York. Dr. Beldner is Attending Surgeon, Division of Hand Surgery, Beth Israel Medical Center, New York, New York.

Address correspondence to: Eitan Melamed, MD, Division of Hand Surgery, Beth Israel Medical Center, 321 East 34th Street, New York, NY 10016 (tel, 212-340-0000; fax, 212-340-0038; email, eitanme2000@yahoo.com).

*Am J Orthop.* 2015;44(8):373-375. Copyright Frontline Medical Communications Inc. 2015. All rights reserved.

## References

1. McMaster PE. Tendon and muscle ruptures, clinical and experimental studies on the causes and location of subcutaneous ruptures. *J Bone Joint Surg Am.* 1933;15(3):705-722.
2. Folmar RC, Nelson CL, Phalen GS. Ruptures of the flexor tendons in hands of non-rheumatoid patients. *J Bone Joint Surg Am.* 1972;54(3):579-584.
3. Grant I, Berger AC, Ireland DC. Rupture of the flexor digitorum profundus tendon to the small finger within the carpal tunnel. *Hand Surg.* 2005;10(1):109-114.
4. Hartford JM, Murphy JM. Flexor digitorum profundus rupture of the small finger secondary to nonunion of the hook of the hamate: a case report. *J Hand Surg Am.* 1996;21(14):621-623.
5. Johnston GH, Bowen CV. Attritional flexor tendon ruptures by an old lunate dislocation. *J Hand Surg Am.* 1988;13(5):701-703.
6. Koizumi M, Kanda T, Satoh S, Yoshizu T, Maki Y, Tsubokawa N. Attritional rupture of the flexor digitorum profundus tendon to the index finger caused by accessory carpal bone in the carpal tunnel: a case report. *J Hand Surg Am.* 2005;30(1):142-146.
7. Wurapa RK, Zelouf DS. Flexor tendon rupture caused by gout: a case report. *J Hand Surg Am.* 2002;27(4):591-593.
8. Masada K, Kanazawa M, Fuji T. Flexor tendon ruptures caused by an intraosseous ganglion of the hook of the hamate. *J Hand Surg Br.* 1997;22(3):383-385.
9. Boyes JH, Wilson JN, Smith JW. Flexor-tendon ruptures in the forearm and hand. *J Bone Joint Surg Am.* 1960;42(4):637-646.
10. Duran R, Houser R, Coleman C, et al. A preliminary report in the use of controlled passive motion following flexor tendon repair in zones II and III [abstract]. *J Hand Surg.* 1976;1(1):79.
11. Strickland JW, Glogovac SV. Digital function following flexor tendon repair in Zone II: A comparison of immobilization and controlled passive motion techniques. *J Hand Surg Am.* 1980;5(6):537-543.
12. Kannus P, Jozsa L. Histopathological changes preceding spontaneous rupture of a tendon. A controlled study of 891 patients. *J Bone Joint Surg Am.* 1991;73(10):1507-1525.
13. Bois AJ, Johnston G, Classen D. Spontaneous flexor tendon ruptures of the hand: case series and review of the literature. *J Hand Surg Am.* 2007;32(7):1061-1071.
14. Leddy JP, Packer JW. Avulsion of the profundus tendon insertion in athletes. *J Hand Surg Am.* 1977;2(1):66-69.
15. Jebson PJ, Ferlic RJ, Engber WF. Spontaneous rupture of ulnar-sided digital flexor tendons: don't forget the hamate. *Iowa Orthop J.* 1995;15:225-227.
16. Zbrodowski A, Mariéthoz E, Bednarkiewicz M, Gajisin S. The blood supply of the lumbrical muscles. *J Hand Surg Br.* 1998;23(3):384-388.