

Congenital Absence of the Anterior Cruciate Ligament

Jothi Murali, MD, Keith Monchik, MD, and Paul Fadale, MD

Abstract

The incidence of congenital absence of the anterior cruciate ligament (ACL) is extremely low. Congenital ACL absence has most often been found in association with conditions such as knee dislocation, knee dysplasia, proximal focal femoral deficiency, and fibular hemimelia.

We report on the incidental finding of ACL aplasia in a patient with a medial meniscal tear and history of leg-length discrepancy. As has been found in prior case studies, this patient had hypertrophy of the meniscomfemoral ligament of Humphrey, which likely lent her stability. This case highlights the importance of differentiating between a stable and an unstable knee in congenital absence of the ACL.

Congenital absence of the anterior cruciate ligament (ACL) is a rare occurrence and has been seen most often in conjunction with conditions such as knee dislocation, knee dysplasia, proximal focal femoral deficiency, and fibular hemimelia.

We report on the incidental finding of ACL aplasia in a patient with a medial meniscal tear and history of leg-length discrepancy. Similar to earlier cases, this patient had hypertrophy of the meniscomfemoral ligament of Humphrey, which likely provided stability. This case report emphasizes the importance of distinguishing between a stable and an unstable knee in congenital absence of the ACL. The patient provided written informed consent for print and electronic publication of this case report.

Case Report

A 20-year-old woman presented for orthopedic evaluation with worsening medial left knee pain. Her pain was intermittent in nature, occurring about every 1 to 2 months and of 1 to 2 days' duration. Onset was while using the elliptical machine, walking on uneven ground, or navigating stairs. She denied any buckling, catching, locking, instability, or swelling.

Her history was significant for a breech delivery and leg anisomelia, for which she had a contralateral distal femoral

and proximal tibial percutaneous epiphysiodesis performed at age 10 years. Family history was negative for limb deformities.

Physical examination was notable for absence of global ligamentous laxity, overall valgus alignment of the left lower extremity, minimally decreased motion, trace effusion, positive medial joint line tenderness, positive McMurray test, and 1+ Lachman test with guarding on pivot shift testing.

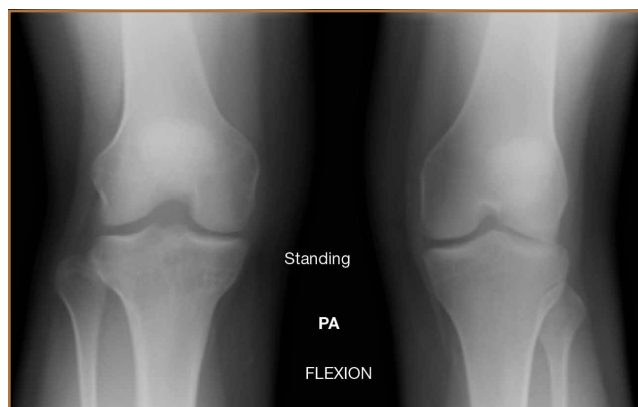Plain films showed valgus alignment with narrowing of the lateral compartment, narrow intercondylar notch, and hypoplasia of the tibial eminences and lateral femoral condyle (Figure 1). Magnetic resonance imaging showed a large tear in the posterior horn of the medial meniscus, hypertrophy of the meniscomfemoral ligament of Humphrey (Figure 2A), and nonvisualization of the ACL with a small remnant (Figure 2B).

Arthroscopy showed complete absence of fibers of the ACL, hypertrophy of the meniscomfemoral ligament of Humphrey, and a large posterior horn medial meniscal tear. A partial medial meniscectomy was performed. More than 2 years after surgery, the patient was doing very well without pain or instability, and was exercising regularly without difficulty.

Discussion

Our patient had left-sided congenital absence of the ACL with associated limb-length discrepancy of more than 2.5 cm. Iso-

Figure 1. Anteroposterior view of both knees shows left knee valgus alignment with narrowing of the lateral compartment, narrow intercondylar notch, and hypoplastic tibial eminences and lateral femoral condyle.



Authors' Disclosure Statement: The authors report no actual or potential conflict of interest in relation to this article.

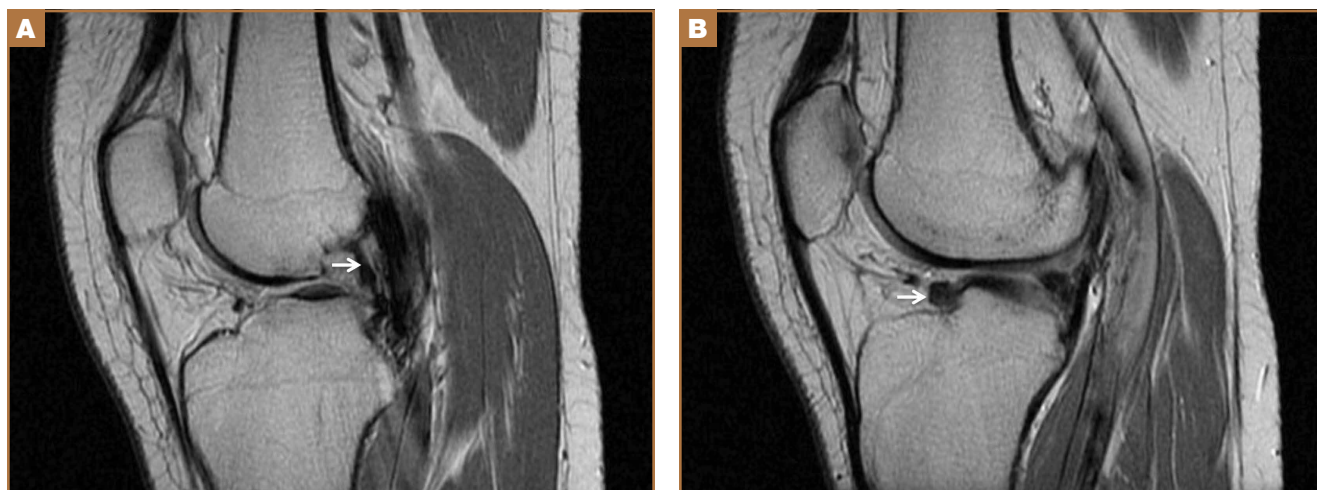


Figure 2. (A) Sagittal T2-weighted proton-density magnetic resonance imaging (MRI) shows a large meniscofemoral ligament of Humphrey (white arrow). (B) MRI shows small remnant of aplastic anterior cruciate ligament (white arrow).

lated absence of the ACL has been described in a few case reports in the literature. Congenital ACL absence has most often been found in association with conditions such as knee dislocation (occurring with a frequency of .017/1000 births),¹ knee dysplasia,^{2,3} fibular hemimelia,⁴ and proximal focal femoral deficiency.⁵ Johansson and Aparisi^{5,6} linked the finding of ACL absence with instability in those patients with known limb-length discrepancy and symptomatic instability. This report presents a patient who has congenital absence of the ACL in a foreshortened limb and torn medial meniscus. The classification of the patient's cruciate dysplasia would be type I, as described by Manner and colleagues.⁷ The incidence of meniscal tears in association with congenital ACL absence is unknown. There have been reports of absence of the ACL associated with a ring meniscus,⁸ absence of both cruciate ligaments and menisci,⁹ and a bucket-handle tear of the medial meniscus.¹⁰

Gabos and colleagues⁴ recommend reconstructive surgery for patients with congenital absence of the ACL and symptomatic knee instability. Limb lengthening/shortening and realignment procedures have allowed patients such as ours to have functionally anatomic limbs and high activity levels. Surgical treatment is pursued to restore mechanical alignment and stability. Our patient had no symptoms of instability.

Similar to 3 of the 4 patients presented by Gabos and colleagues,⁴ our patient had marked hypertrophy of the meniscofemoral ligament of Humphrey. The report by Gabos and colleagues⁴ of this finding was the first in the literature. The hypertrophy of this ligament suggests it has a role in stabilizing the knee with a congenitally absent ACL. Our patient had no instability in her left knee but presented because of episodes of pain.

Of significant concern is the long-term outcome of patients with congenital ACL aplasia. Crawford and colleagues¹¹ reported 11 patients with ACL deficiency and fibular hemimelia at a mean age of 37 years, showing similar functional outcomes

to age-matched controls. However, there was no radiographic follow-up reported in regard to the development of osteoarthritis. To our knowledge, there have been no series published comparing surgical and nonsurgical treatment of congenital absence of the ACL. In the study by Gabos and colleagues,⁴ all patients were treated with reconstruction because these patients had symptomatic instability.

Conclusion

This report presents a patient whose symptoms improved after resection of her medial meniscal tear. This patient will be followed long-term to delineate her clinical course and to monitor for instability and/or development of osteoarthritis. Future studies should compare the treatment of congenital absence of the ACL with reconstruction and with conservative management.

Dr. Murali is an Orthopaedic Surgeon specializing in Sports Medicine and Trauma, Muir Orthopaedic Specialists, Walnut Creek, California. Dr. Monchik is Orthopaedic Surgeon, Foundry Orthopedics & Sports Medicine, Providence, Rhode Island. Dr. Fadale is Surgeon-in-Chief, Division of Sports Medicine, University Orthopedics, Providence, Rhode Island.

Address correspondence to: Jothi Murali, MD, Muir Orthopaedic Specialists, 2405 Shadelands Drive, Walnut Creek, CA 94598 (tel, 925-939-8585; fax, 925-930-8159; email, jothi.b.murali@gmail.com).

Am J Orthop. 2015;44(8):E283-E285. Copyright Frontline Medical Communications Inc. 2015. All rights reserved.

References

1. Tachdjian MO. *Pediatric Orthopedics*. 2nd ed. Philadelphia: Saunders; 1990.
2. Thomas NP, Jackson AM, Aichroth PM. Congenital absence of the anterior cruciate ligament: A common component of knee dysplasia. *J Bone Joint Surg Br.* 1985;67(4):572-575.
3. Hejgaard N, Kjaerulff H. Congenital aplasia of the anterior cruciate ligament. Report of a case in a seven-year-old girl. *Int Orthop.* 1987;11(3):223-225.
4. Gabos PG, El Rassi G, Pahys J. Knee reconstruction in syndromes with congenital absence of the anterior cruciate ligament. *J Pediatr Orthop.* 2005;25(2):210-214.

5. Johansson E, Aparisi T. Missing cruciate ligament in congenital short femur. *J Bone Joint Surg Am.* 1983;65(8):1109-1115.
6. Johansson E, Aparisi T. Congenital absence of the cruciate ligaments. A case report and review of the literature. *Clin Orthop Relat Res.* 1982;162:108-111.
7. Manner HM, Radler C, Ganger R, Grill F. Dysplasia of the cruciate ligaments: radiographic assessment and classification. *J Bone Joint Surg Am.* 2006;88(1):130-137.
8. Noble J. Congenital absence of the anterior cruciate ligament associated with a ring meniscus. *J Bone Joint Surg Am.* 1975;57(8):1165-1166.
9. Tolo VT. Congenital absence of the menisci and cruciate ligaments of the knee. A case report. *J Bone Joint Surg Am.* 1981;63(6):1022-1024.
10. Kaelin A, Hulin PH, Carlöz H. Congenital aplasia of the cruciate ligaments. A report of six cases. *J Bone Joint Surg Br.* 1986;68(5):827-828.
11. Crawford DA, Tompkins BJ, Baird GO, Caskey PM. The long term function of the knee in patients with fibular hemimelia and anterior cruciate ligament deficiency. *J Bone Joint Surg Br.* 2012;94(3):328-333.