

# Isolated Radiopalmar Dislocation of Fifth Carpometacarpal Joint: A Rare Presentation

Atmananda S. Hegde, MS (Ortho), MRCSEd, R. M. Shenoy, MS (Ortho), Salauddin Arif, MS (Ortho), Abhishek Shetty, MS (Ortho), and Rajan Babu, MS (Ortho)

## Abstract

Carpometacarpal (CMC) joint dislocations are uncommon injuries that account for less than 1% of hand injuries. Dorsal dislocations of the CMC joints are more frequent than volar dislocations. Palmar dislocations can be either ulnopalmar or radiopalmar. There are very few reports of isolated radiopalmar dislocations of the fifth CMC joint in the English-language literature. In our case of radiopalmar dislocation, diagnosis was delayed, and attempts at closed reduction were unsuccessful. Therefore, it was treated by open reduction and Kirschner-wire fixation. This article reports a rare type of injury and discusses its management.

Isolated dislocation of the carpometacarpal (CMC) joint of the hand is a rare injury. While the dislocation can be dorsal or palmar, dorsal dislocation is more common. Palmar dislocations can be either ulnopalmar or radiopalmar. There are very few reports of isolated radiopalmar dislocations of the fifth CMC joint in the English-language literature.<sup>1-3</sup> We present a case of delayed presentation and management of radiopalmar dislocation of the fifth CMC joint. The patient provided written informed consent for print and electronic publication of this case report.

## Case Report

A 42-year-old man presented with polytrauma to our emergency department. He was stabilized initially, and open fractures were treated by débridement and external fixator application. During an examination 3 days after admission, swelling was noted in the right hand. On further study, there was splaying of the fifth digit and tenderness over the fourth and fifth CMC joints (Figure 1). No abnormal mobility or crepitus could be elicited. Plain radiographs of the right hand in anteroposterior and lateral views revealed radiopalmar dislocation of the fifth CMC joint (Figure 2). It was decided to reduce the dislocation immediately after the patient was declared fit for surgery.

Under axillary block, closed reduction was unsuccessful. Open reduction of the fifth CMC joint was performed through

a dorsal incision. The base of the fifth metacarpal bone was found to be stripped of soft-tissue attachments and lying in a radiopalmar location. Reduction, which was checked under image intensifier, was found to be satisfactory (Figure 3). Reduction was stabilized by passing a smooth Kirschner wire (K-wire) from the fifth metacarpal to the hamate bone. After

Figure 1. (A, B) Clinical photographs showing splaying of fifth digit and swelling of the hand.

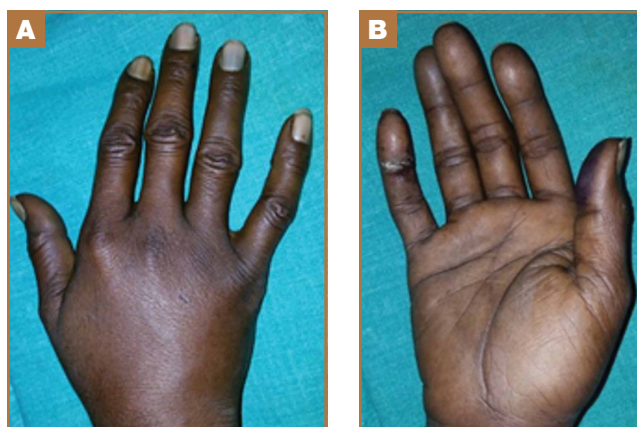
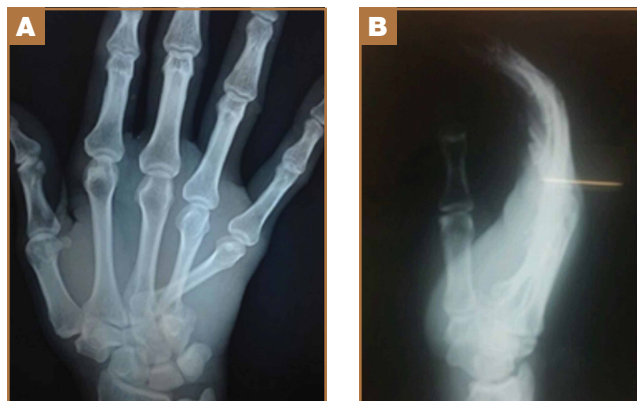
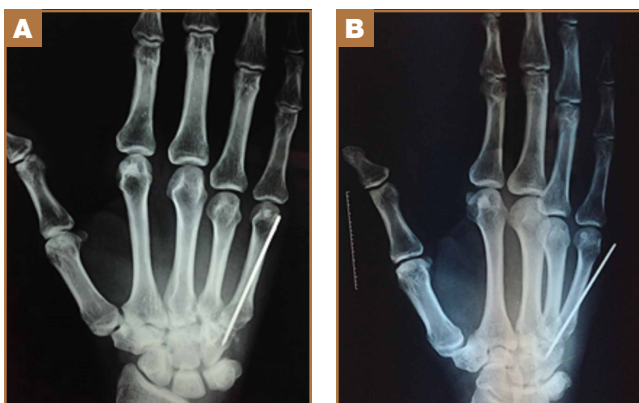


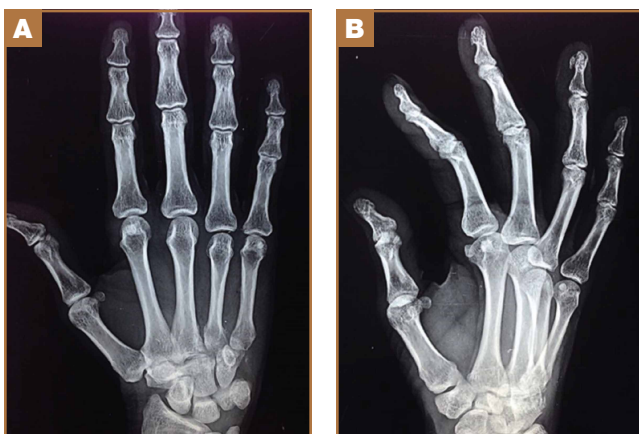Figure 2. Preoperative (A) anteroposterior and (B) lateral radiographs showing radiopalmar dislocation of the fifth carpometacarpal joint.



**Authors' Disclosure Statement:** The authors report no actual or potential conflict of interest in relation to this article.



**Figure 3.** Postoperative (A) anteroposterior and (B) lateral radiographs showing reduced fifth carpometacarpal joint stabilized by Kirschner wire.



**Figure 4.** (A) Anteroposterior and (B) lateral radiographs at 2-month follow-up showing satisfactory position of the fifth carpometacarpal joint.

achieving hemostasis, the wound was closed in layers and a below-elbow splint was applied. The perioperative period was uneventful, and sutures were removed on postoperative day 10. The K-wire was removed after 4 weeks, and radiographs showed satisfactory position of the fifth CMC joint. Gentle active and passive mobilization of fingers and wrist were started. The patient had regained good function of the wrist and fingers 2 months after surgery (Figure 4).

### Discussion

Carpometacarpal joint dislocations are uncommon injuries and account for less than 1% of hand injuries.<sup>4</sup> They are classified as dorsal and volar (palmar) dislocations. Dorsal dislocations of the CMC joints occur more frequently than do volar dislocations, mainly affecting the fourth and fifth digits.<sup>5</sup> Isolated volar or palmar dislocation of the fifth CMC joint is an uncommon injury that was first reported in 1918 by McWhorter.<sup>6</sup> In 1968, Nalebuff<sup>7</sup> classified the volar dislocations into 2 groups according to the direction of the displacement

of the fifth metacarpal base: radiopalmar and ulnopalmar. Berg and Murphy<sup>8</sup> found the hook of the hamate to deviate the metacarpal bone to either the ulnar or radial side. Tearing of all ligament and tendon attachments of the base of the fifth metacarpal results in radiopalmar dislocation.<sup>7</sup> The attachments of ligaments and tendons remain intact in the ulnopalmar dislocation.<sup>7</sup>

The clinical features of this injury are pain and swelling about the base of the fifth metacarpal and axial deformity of the little finger with apparent shortening. The deep motor branch of the ulnar nerve lies volar to the fifth CMC joint as it courses around the hook of the hamate. It is vulnerable to injury in both dorsal<sup>9,10</sup> and volar<sup>11</sup> CMC dislocations. For radiologic evaluation, in addition to standard anteroposterior and lateral radiographs, a lateral view in 30° pronation of the hand can provide an improved view of the fifth CMC joint, as suggested by Bora and Didizian.<sup>12</sup>

The treatment of ulnopalmar dislocation has evolved. Ulnopalmar dislocations have been successfully treated by closed reduction without fixation,<sup>8</sup> and by open reduction and K-wire fixation.<sup>3,7,13</sup>

Radiopalmar dislocations are inherently unstable because of the tearing of all ligament and tendon attachments of the base of the fifth metacarpal.<sup>7</sup> In our case of radiopalmar dislocation, diagnosis was delayed and attempts at closed reduction were unsuccessful. Therefore, it was treated by open reduction and K-wire fixation. In our case, open reduction and K-wire fixation for radiopalmar dislocation of the fifth CMC joint provided promising results.

### Conclusion

Radiopalmar dislocation of the fifth CMC joint is a rare injury, and very few cases have been reported in the English-language literature. We report one such case, which was successfully treated with open reduction and K-wire fixation.

Dr. Hegde is Associate Professor, Department of Orthopaedics, Kasturba Medical College, Manipal University, Mangalore, India. Dr. Shenoy and Dr. Arif are Professors, and Dr. Shetty and Dr. Babu are Assistant Professors, Department of Orthopaedics, Yenepoya Medical College, Mangalore, India.

Address correspondence to: Atmananda S. Hegde, MS (Ortho), MRCSEd, Department of Orthopaedics, Kasturba Medical College, Mangalore 575018, India (tel, 09740557222; email, atmananda-hegde@gmail.com).

*Am J Orthop.* 2015;44(9):E347-E349. Copyright Frontline Medical Communications Inc. 2015.

### References

1. Buzby BF. Palmar carpometacarpal dislocation of the fifth metacarpal. *Ann Surg.* 1934;100:555-557.
2. Chen VT. Dislocation of carpometacarpal joint of the little finger. *J Hand Surg.* 1987;12(2):260-263.
3. Dennyson WG, Stother IG. Carpometacarpal dislocation of the little finger. *Hand.* 1976;8(2):161-164.
4. Domingo A, Font L, Saz L, Arandes JM. Isolated radial palmar dislocation of the fifth carpometacarpal joint with ulnar neuropathy associated: successful treatment with closed reduction and internal fixation. *Eur J Orthop Surg Traumatol.* 19(2):101-107.

5. Fisher MR, Rogers LF, Hendrix RW. Systematic approach to identifying fourth and fifth carpometacarpal joint dislocations. *AJR Am J Roentgenol*. 1983;140(2):319-324.
6. McWhorter GL. Isolated and complete dislocation of the fifth carpometacarpal joint: open operation. *Surg Clin Chic*. 1918;2:793-796.
7. Nalebuff EA. Isolated anterior carpometacarpal dislocation of the fifth finger: classification and case report. *J Trauma*. 1968;8(6):1119-1123.
8. Berg EE, Murphy DF. Ulnopalmar dislocation of the fifth carpometacarpal joint – successful closed reduction: review of the literature and anatomic reevaluation. *J Hand Surg Am*. 1986;11(4):521-525.
9. Peterson P, Sacks S. Fracture-dislocation of the base of the fifth metacarpal associated with injury to the deep motor branch of the ulnar nerve: a case report. *J Hand Surg Am*. 1986;11(4):525-528.
10. Young TB. Dorsal dislocation of the metacarpal base of the little and ring fingers with ulnar nerve branch compression. *Injury*. 1987;18(1):65-66.
11. O'Rourke PJ, Quinlan W. Fracture dislocation of the fifth metacarpal resulting in compression of the deep branch of the ulnar nerve. *J Hand Surg Br*. 1993;18(2):190-191.
12. Bora FW Jr, Didizian NH. The treatment of injuries to the carpometacarpal joint of the little finger. *J Bone Joint Surg Am*. 1974;56(7):1459-1463.
13. Tountas AA, Kwok JM. Isolated volar dislocation of the fifth carpometacarpal joint. Case report. *Clin Orthop Relat Res*. 1984;187:172-175.