

# Open Carpal Tunnel Release With Use of a Nasal Turbinate Speculum

Raghuveer C. Muppavarapu, MD, Sean S. Rajaei, MD, David E. Ruchelsman, MD, and Mark R. Belsky, MD

## Abstract

Incomplete release of the transverse carpal ligament (TCL) and median nerve injury are complications of carpal tunnel release (CTR).

In this article, we describe a modified mini-open release using a fine nasal turbinate speculum to aid in the proximal release with direct visualization of the proximal limb of the TCL and the distal volar forearm fascia (DVFF). The technique begins with a 2.5-cm palmar longitudinal incision, and standard distal release of the TCL is completed. A fine nasal turbinate speculum is inserted into the plane above the proximal limb of the TCL and the DVFF. A long-handle scalpel is used to incise the TCL and the DVFF under direct visualization.

We retrospectively analyzed a cohort of 101 consecutive CTR cases (63 right, 38 left). Carpal tunnel syndrome symptoms were relieved in all patients with a high degree of satisfaction.

This modified mini-open technique provides surgeons with a reproducible and inexpensive method to ensure a safe proximal release of the TCL.

Carpal tunnel syndrome (CTS) is a disorder characterized by entrapment of the median nerve at the wrist, which may lead to symptoms of pain, paresthesia, and, ultimately, thenar muscle atrophy. Surgical intervention is indicated with persistent or progressive symptoms despite nonoperative management. Timely surgical decompression aims to halt progression of this disorder and prevent permanent peripheral nerve injury.

Carpal tunnel release (CTR) is the most common hand and wrist surgery in the United States, with about 400,000 operations performed annually.<sup>1,2</sup> Several methods of decompressing the carpal tunnel have been described.<sup>3</sup> These include standard open CTR (OCTR), mini-open approaches, and various endoscopic techniques. OCTR was initially described by Sir James Learmonth in 1933,<sup>4</sup> and it remains the gold-standard surgical treatment for patients with symptomatic CTS. Uniform excellent results with high patient

satisfaction and low complication rates have been reported in several series.<sup>5-9</sup> Common to all techniques is complete proximal-to-distal division of the transverse carpal ligament (TCL). Magnetic resonance imaging studies have shown that TCL transection and the resulting diastasis between the radial and ulnar leaflets cause a significant increase in the volume of the carpal tunnel, leading to decreased pressure.<sup>10,11</sup>

Endoscopic CTR (ECTR) techniques were developed in an effort to reduce complications, scar sensitivity, and pillar pain and facilitate more rapid return to work.<sup>12-17</sup> Outcome studies have demonstrated that both open and endoscopic releases yield patient-reported subjective improvements over preoperative symptoms.<sup>18-22</sup> A randomized, controlled trial by Trumble and colleagues<sup>23</sup> in 2002 found that ECTR led to improved patient outcomes in the early postoperative period (first 3 months), though differences in outcomes were reduced at final follow-up. More recently (2007), a Cochrane review of 33 trials concluded there was no strong evidence favoring use of alternative techniques over OCTR.<sup>3</sup> Further, OCTR has been found to be technically less demanding and associated with decreased complications and costs.<sup>24</sup>

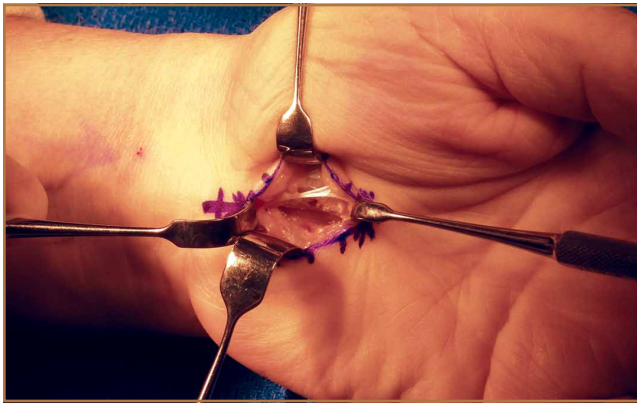
## Indications

The benefit of median nerve decompression at the wrist for CTS is clear.<sup>6,7</sup> Indications for surgery in patients with CTS include persistent symptoms despite nonoperative treatment, objective sensory disturbance or motor weakness, and thenar atrophy. Symptomatic response to corticosteroid injection is predictive of success after carpal tunnel surgery.<sup>25</sup> More than 87% of patients who gain symptomatic relief from corticosteroid injection have an excellent surgical outcome.

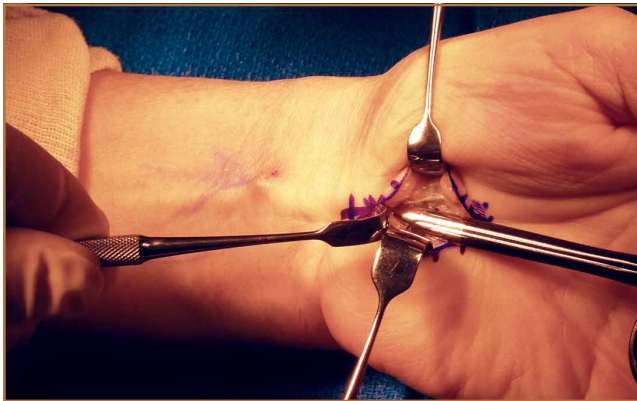## Technique

OCTR allows direct visualization of the TCL and the distal volar forearm fascia (DVFF) and evaluation for the presence of anomalous branching patterns of the median nerve. OCTR traditionally was performed through a 4- to 5-cm longitudinal incision extending from the wrist crease proximally to the Kaplan cardinal line distally. The mini-open technique is identical with the exception of incision length. We routinely use a 2.5- to 3-cm incision. Regardless of incision length, each OCTR should proceed through the same reproducible steps.

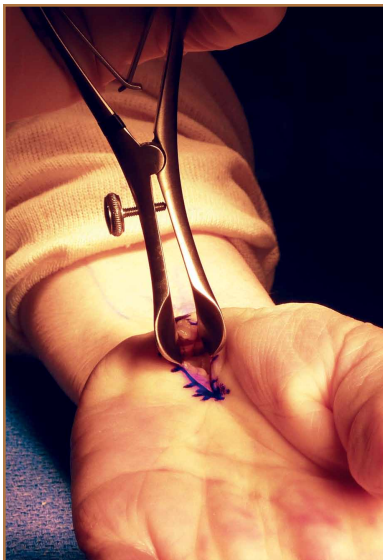
**Authors' Disclosure Statement:** The authors report no actual or potential conflict of interest in relation to this article.



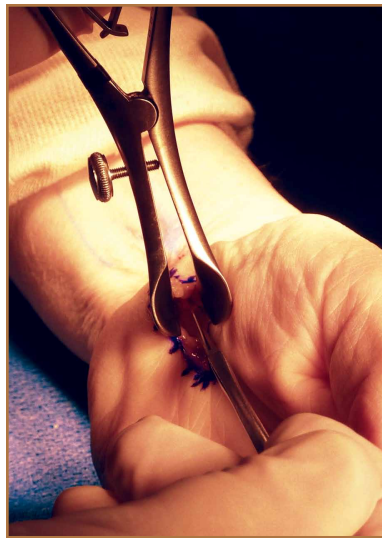**Figure 1.** Longitudinal incision (2.5 cm) is made, and subcutaneous fat is mobilized.



**Figure 2.** Mobilization of subcutaneous fat above transverse carpal ligament is performed using curved Mayo scissors.



**Figure 3.** Nasal turbinate speculum is then inserted into plane above proximal limb of transverse carpal ligament.



**Figure 4.** Long-handle scalpel is used to incise transverse carpal ligament and distal volar forearm fascia under direct visualization.

We perform OCTR under tourniquet control. Choice of anesthesia is surgeon and patient preference. We prefer local anesthesia with conscious sedation. After conscious sedation is administered, we infiltrate the carpal tunnel and surrounding subcutaneous tissue with 10 mL of a 50:50 mixture of 0.5% bupivacaine and 1% lidocaine without epinephrine.

A 2.5- to 3-cm longitudinal incision is made along the axis of the radial border of the ring finger from the Kaplan cardinal line<sup>26</sup> and extending about 3 cm proximally toward the wrist flexion crease ulnar to the palmaris longus if present (**Figure 1**).

After the skin is incised longitudinally, the subcutaneous fat is mobilized and cutaneous sensory branches identified and protected. The underlying superficial palmar fascia is incised in line with the skin incision. The underlying mid-portion of the TCL is now visualized.

### Transverse Carpal Ligament Release

Occasionally, the investing fascia along the ulnar edge of the thenar musculature is mobilized radialward (if the thenar musculature is well developed) to visualize the proximal limb of the TCL. Injury to any anomalous motor branch of the median nerve is avoided by directly visualizing and then incising the TCL (**Figure 2**). The TCL is incised along its ulnar border just radial to the hook of hamate from distal to proximal in line with the radial border of the ring finger. Staying near the ulnar attachment of the TCL keeps the plane of ligament division farther away from the median nerve and its recurrent motor branches. Although the ulnar neurovascular bundle typically resides ulnar to the hook of hamate in the canal of Guyon, the surgeon must be aware that it can be located radial to the hook in some instances.<sup>27,28</sup> In the elderly, the ulnar artery may be tortuous and enter the field and require retraction. The TCL is incised distally until the sentinel fat pad, which marks the superficial palmar arterial arch, is visualized. This bed of adipose tissue marks the distal edge of the TCL.<sup>29</sup>

Proximally, subcutaneous tissues above the proximal limb of the TCL and DVFF are mobilized to about 2 cm proximal to the wrist flexion crease to create a plane for the fine long nasal turbinate speculum. The nasal turbinate speculum is then inserted into this plane above the proximal limb of the TCL and DVFF (**Figure 3**). Once inserted to the level of the confluence of the TCL and the DVFF, the speculum is opened.

Topside visualization is now encountered with the ulnar neurovascular bundle protected by the ulnar blade of the speculum. A long-handle scalpel is used to incise the TCL and the DVFF under direct visualization from proximal to distal in line with the previously completed distal release (**Figure 4**). As the nasal turbinate speculum is stretching

**Table. Characteristics of 101 Cases of Open Carpal Tunnel Release With Use of a Nasal Turbinate Speculum Over 1 Year**

Hands, N	101 (63 right, 38 left)
Patients, N	88 (51 female, 37 male)
Mean age, y	62.8
Mean tourniquet time, <sup>a</sup> min	16
Mean follow-up, d	78.8
Symptom improvement, %	100
Significant complications, %	0
Minor complications (improved but residual numbness), %	4.0 (4/101)

<sup>a</sup>Based on isolated cases of carpal tunnel release only.

the TCL and putting it under tension, the TCL can be heard splitting as it is being incised. Once the TCL and the DVFF are divided, the speculum is slowly closed and removed. Wide diastasis of the radial and ulnar leaflets of the TCL and the DVFF is directly visualized. Complete decompression of the median nerve from the distal forearm fascia to the superficial palmar arch is confirmed.

Adhesions between the undersurface of the radial leaflet and the flexor tendons and median nerve are mobilized. The median nerve is assessed for “hourglass” morphology or atrophy. The flexor tendons can be swept radialward with a free elevator to inspect the floor of the carpal tunnel. Flexor tenosynovectomy is not routinely performed. The incision is closed with interrupted simple sutures using 4-0 nylon.

## Study Results

This study was conducted at Hand Surgery PC, Newton-Wellesley Hospital, Tufts University School of Medicine. Over a 10-month interval, 101 consecutive mini-OCTRs (63 right hands, 38 left hands) were performed with this proximal release modification in 88 patients (51 females, 37 males) by Dr. Ruchelsman and Dr. Belsky (Table). CTRs performed in the setting of wrist and/or carpal trauma were excluded. Mean age was 62.8 years. Mean follow-up was 11.3 weeks (~3 months). For isolated cases of CTR, mean tourniquet time was 16 minutes. CTS symptoms were relieved in all patients with a high degree of satisfaction as measured with history and examination findings at follow-up visits. There were no major complications (eg, infection, neural or vascular damage, severe residual pain). Four patients reported minor residual numbness in the fingers at latest follow-up but nevertheless had major improvement over preoperative baseline. These 4 patients had preoperative electromyograms or nerve conduction studies documenting the extent of their disease. There was 1 case of minor wound complication. Three weeks after surgery, the patient had a 1-cm wound opening, which closed with local wound care. The patient did not develop any drainage, infection, bleeding, or neurologic symptoms.

## Discussion

Open release of the TCL—the gold standard of surgical treatment for CTS—produces reliable symptom relief in the vast majority of patients.<sup>25,30</sup> Given that the most common complication of carpal tunnel surgery is incomplete release of the TCL,<sup>31,32</sup> this technique, which uses a nasal turbinate speculum to better visualize the median nerve, could potentially reduce the reoperation rate. The nasal turbinate speculum allows the surgeon to see the confluence of the TCL and the DVFF. In addition, as the complete release can be visualized, there is minimal chance of injury.

The 2007 Cochrane review<sup>3</sup> found no strong evidence supporting replacing

OCTR with endoscopic techniques. Previous investigators have questioned the utility of ECTR given that it is higher in cost and more resource-intensive than OCTR<sup>1,33,34</sup> and is associated with higher rates of certain complications.<sup>5,22,35-37</sup> A 2004 meta-analysis of 13 randomized, controlled trials found a higher rate of reversible nerve damage with an odds ratio of 3.1 for ECTR versus OCTR.<sup>35</sup> A more recent (2006) review of more than 80 studies found transient neurapraxias in 1.45% of ECTR cases and 0.25% of OCTR cases.<sup>5</sup> The same study reported overall complication rates (reversible and major neurovascular structural injuries) of 0.74% for OCTR and 1.63% for ECTR ( $P < .005$ ). Another limitation of ECTR is that endoscopic techniques require a higher degree of surgical skill, which makes teaching residents and fellows more challenging.

The novel nasal turbinate speculum technique presented here is easily reproducible and allows first-time surgeons to visualize all important structures. Given that this technique does not require an endoscope or an endoscope-viewing tower, it is likely more cost-effective and requires less time for turnover between cases. Patients obtain good relief of their CTS symptoms with this technique, and most return to their daily activities within weeks after operation.

Dr. Muppavarapu is Hand Fellow, Department of Orthopaedic Surgery, New York University, Hospital of Joint Diseases, New York, New York. Dr. Muppavarapu was a resident at Tufts University School of Medicine at the time this article was written. Dr. Rajaei is Resident, Division of Orthopaedic Surgery, Department of Surgery, Cedars-Sinai Medical Center, Los Angeles, California. Dr. Ruchelsman is Assistant Chief of Division of Hand Surgery, and Clinical Assistant Professor, Hand Surgery PC, Newton-Wellesley Hospital, Tufts University School of Medicine, Newton, Massachusetts; and Consultant, Hand, Upper Extremity, and Microvascular Surgery Service, Department of Orthopaedic Surgery, Massachusetts General Hospital/Harvard Medical School, Boston, Massachusetts. Dr. Belsky is Clinical Professor of Orthopaedic Surgery, Hand Surgery PC, Newton-Wellesley Hospital, Tufts University School of Medicine, Newton, Massachusetts.

Address correspondence to: David E. Ruchelsman, MD, Hand Surgery PC, 2000 Washington St, Blue Building, Suite 201, Newton, MA 02462 (tel, 617-965-4263; fax, 617-928-0597; email, druchelsman@mgh.harvard.edu).



*Am J Orthop.* 2015;44(11):495-498. Copyright Frontline Medical Communications Inc. 2015. All rights reserved.

## References

1. Ono S, Clapham PJ, Chung KC. Optimal management of carpal tunnel syndrome. *Int J Gen Med.* 2010;3(4):255-261.
2. Concannon MJ, Brownfield ML, Puckett CL. The incidence of recurrence after endoscopic carpal tunnel release. *Plast Reconstr Surg.* 2000;105(5):1662-1665.
3. Scholten RJ, Mink van der Molen A, Uitdehaag BM, Bouter LM, de Vet HC. Surgical treatment options for carpal tunnel syndrome. *Cochrane Database Syst Rev.* 2007;(4):CD003905.
4. In memoriam Sir James Learmonth, K.C.V.O., C.B.E., hon. F.R.C.S. (1895-1967). *Ann R Coll Surg Engl.* 1967;41(5):438-439.
5. Benson LS, Bare AA, Nagle DJ, Harder VS, Williams CS, Visotsky JL. Complications of endoscopic and open carpal tunnel release. *Arthroscopy.* 2006;22(9):919-924, 924.e1-e2.
6. Jarvik JG, Comstock BA, Kliot M, et al. Surgery versus non-surgical therapy for carpal tunnel syndrome: a randomised parallel-group trial. *Lancet.* 2009;374(9695):1074-1081.
7. Verdugo RJ, Salinas RA, Castillo JL, et al. Surgical versus non-surgical treatment for carpal tunnel syndrome. *Cochrane Database Syst Rev.* 2008;(4):CD001552.
8. Garland H, Langworth EP, Taverner D, et al. Surgical treatment for the carpal tunnel syndrome. *Lancet.* 1964;1(7343):1129-1130.
9. Gerritsen AA, de Vet HC, Scholten RJ, et al. Splinting vs surgery in the treatment of carpal tunnel syndrome: a randomized controlled trial. *JAMA.* 2002;288(10):1245-1251.
10. Gelberman RH, Hergenroeder PT, Hargens AR, et al. The carpal tunnel syndrome. A study of carpal canal pressures. *J Bone Joint Surg Am.* 1981;63(3):380-383.
11. Sucher BM. Myofascial manipulative release of carpal tunnel syndrome: documentation with magnetic resonance imaging. *J Am Osteopath Assoc.* 1993;93(12):1273-1278.
12. Pereira EE, Miranda DA, Sere I, et al. Endoscopic release of the carpal tunnel: a 2-portal-modified technique. *Tech Hand Up Extrem Surg.* 2010;14(4):263-265.
13. Louis DS, Greene TL, Noellert RC. Complications of carpal tunnel surgery. *J Neurosurg.* 1985;62(3):352-356.
14. Mirza MA, King ET Jr, Tanveer S. Palmar uniportal extrabursal endoscopic carpal tunnel release. *Arthroscopy.* 1995;11(1):82-90.
15. Brown MG, Keyser B, Rothenberg ES. Endoscopic carpal tunnel release. *J Hand Surg Am.* 1992;17(6):1009-1011.
16. Agee JM, McCarroll HR Jr, Tortosa RD, et al. Endoscopic release of the carpal tunnel: a randomized prospective multicenter study. *J Hand Surg Am.* 1992;17(6):987-995.
17. Okutsu I, Ninomiya S, Takatori Y, et al. Endoscopic management of carpal tunnel syndrome. *Arthroscopy.* 1989;5(1):11-18.
18. Ghaly RF, Saban KL, Haley DA, et al. Endoscopic carpal tunnel release surgery: report of patient satisfaction. *Neurol Res.* 2000;22(6):551-555.
19. Lee WP, Plancher KD, Strickland JW. Carpal tunnel release with a small palmar incision. *Hand Clin.* 1996;12(2):271-284.
20. Biyani A, Downes EM. An open twin incision technique of carpal tunnel decompression with reduced incidence of scar tenderness. *J Hand Surg Br.* 1993;18(3):331-334.
21. Brown RA, Gelberman RH, Seiler JG 3rd, et al. Carpal tunnel release. A prospective, randomized assessment of open and endoscopic methods. *J Bone Joint Surg Am.* 1993;75(9):1265-1275.
22. Chow JC. Endoscopic release of the carpal ligament for carpal tunnel syndrome: 22-month clinical result. *Arthroscopy.* 1990;6(4):288-296.
23. Trumble TE, Diao E, Abrams RA, et al. Single-portal endoscopic carpal tunnel release compared with open release: a prospective, randomized trial. *J Bone Joint Surg Am.* 2002;84(7):1107-1115.
24. Gerritsen AA, Uitdehaag BM, van Geldere D, et al. Systematic review of randomized clinical trials of surgical treatment for carpal tunnel syndrome. *Br J Surg.* 2001;88(10):1285-1295.
25. Edgell SE, McCabe SJ, Breidenbach WC, et al. Predicting the outcome of carpal tunnel release. *J Hand Surg Am.* 2003;28(2):255-261.
26. Vella JC, Hartigan BJ, Stern PJ. Kaplan's cardinal line. *J Hand Surg Am.* 2006;31(6):912-918.
27. Kwon JY, Kim JY, Hong JT, et al. Position change of the neurovascular structures around the carpal tunnel with dynamic wrist motion. *J Korean Neurosurg Soc.* 2011;50(4):377-380.
28. Netscher D, Polsen C, Thornby J, et al. Anatomic delineation of the ulnar nerve and ulnar artery in relation to the carpal tunnel by axial magnetic resonance imaging scanning. *J Hand Surg Am.* 1996;21(2):273-276.
29. Madhav TJ, To P, Stern PJ. The palmar fat pad is a reliable intraoperative landmark during carpal tunnel release. *J Hand Surg Am.* 2009;34(7):1204-1209.
30. Kulick MI, Gordillo G, Javidi T, et al. Long-term analysis of patients having surgical treatment for carpal tunnel syndrome. *J Hand Surg Am.* 1986;11(1):59-66.
31. Bland JD. Treatment of carpal tunnel syndrome. *Muscle Nerve.* 2007;36(2):167-171.
32. MacDonald RI, Lichtman DM, Hanlon JJ, et al. Complications of surgical release for carpal tunnel syndrome. *J Hand Surg Am.* 1978;3(1):70-76.
33. Atroshi I, Larsson GU, Ornstein E, Hofer M, Johnsson R, Ranstam J. Outcomes of endoscopic surgery compared with open surgery for carpal tunnel syndrome among employed patients: randomised controlled trial. *BMJ.* 2006;332(7556):1473.
34. Ferdinand RD, MacLean JG. Endoscopic versus open carpal tunnel release in bilateral carpal tunnel syndrome. A prospective, randomised, blinded assessment. *J Bone Joint Surg Br.* 2002;84(3):375-379.
35. Thoma A, Veltri K, Haines T, et al. A meta-analysis of randomized controlled trials comparing endoscopic and open carpal tunnel decompression. *Plast Reconstr Surg.* 2004;114(5):1137-1146.
36. Murphy RX Jr, Jennings JF, Wukich DK. Major neurovascular complications of endoscopic carpal tunnel release. *J Hand Surg Am.* 1994;19(1):114-118.
37. Palmer DH, Paulson JC, Lane-Larsen CL, et al. Endoscopic carpal tunnel release: a comparison of two techniques with open release. *Arthroscopy.* 1993;9(5):498-508.

---

*This paper will be judged for the Resident Writer's Award.*

---