

# Medial Patellar Subluxation: Diagnosis and Treatment

Michael G. Saper, DO, and David A. Shneider, MD

## Abstract

Medial patellar subluxation is a poorly recognized clinical condition characterized by chronic anterior knee pain that is exacerbated with knee flexion. Additional symptoms include instability, limited knee motion, and pain with squatting and stair climbing. Full characterization of the patient's knee pain requires an accurate history and physical examination. Diagnosis is typically confirmed during diagnostic arthroscopy.

When nonsurgical management (eg, physical rehabilitation, patella-stabilizing bracing) fails, surgery (eg, medial retinacular release, lateral retinacular imbrication, newer techniques to repair or reconstruct the lateral retinaculum/lateral patellofemoral ligament) can lead to good results. Further study is needed to confirm current understanding of medial patellar subluxation and to better define treatment options and prevention strategies.

**M**edial patellar subluxation (MPS) is a disabling condition caused by an imbalance in the medial and lateral forces in the normal knee, allowing the patella to displace medially. Normally, the patella glides appropriately in the femoral trochlea, but alteration in this medial–lateral equilibrium can lead to pain and instability.<sup>1</sup> MPS was first described in 1987 by Betz and colleagues<sup>2</sup> as a complication of lateral retinacular release. Since then, multiple cases of iatrogenic, traumatic, and isolated medial subluxation have been reported.<sup>3–15</sup> However, MPS after lateral release is the most common cause, accounting for the majority of published cases, whereas only 8 cases of isolated MPS have been reported to date.

Optimal treatment for MPS is not well understood. To better comprehend and manage MPS, we must fully appreciate the pathoanatomy, biomechanics, and current research. In this review, we focus on the anatomy of the lateral retinaculum, diagnosis and treatment of MPS, and outcomes of current treatment techniques.

## Anatomy

In 1980, Fulkerson and Gossling<sup>16</sup> delineated the anatomy of the knee joint lateral retinaculum. They described a 2-layered

system with separate distinct anatomical structures. The lateral retinaculum is oriented longitudinally with the knee extended but exerts a posterolateral force on the lateral aspect of the patella as the knee is flexed. The superficial layer is composed of oblique fibers of the lateral retinaculum originating from the iliotibial band and the vastus lateralis fascia and inserting into the lateral margin of the patella and the patella tendon. The deep layer of the retinaculum consists of several structures, including the deep transverse retinaculum, lateral patellofemoral ligament (LPFL), and the patellotibial band.

Over the years, several studies have described the importance of the lateral retinaculum and, in particular, the LPFL. Examining the functional anatomy of the knee in 1962, Kaplan<sup>17</sup> first described the *lateral epicondylopatellar ligament* as a palpable thickening of the joint capsule. Reider and colleagues<sup>18</sup> later named this structure the *lateral patellofemoral ligament* in their anatomical study of 21 fresh cadaver knees. They described its width as ranging from 3 to 10 mm. In a comprehensive cadaveric study of the LPFL, Navarro and colleagues<sup>19,20</sup> found it to be a distinct structure present in all 20 of their dissected specimens. They found its femoral insertion at the lateral epicondyle with a fanlike expansion of the fibers predominantly in the posterior region proximal to the lateral epicondyle. The patellar insertion was found in the posterior half and upper lateral aspect, also with expanded fibers. Mean length of the LPFL is 42.1 mm, and mean width is 16.1 mm.

Medial and lateral forces are balanced in a normal knee, and the patella glides appropriately in the femoral trochlea. Alteration in this medial–lateral equilibrium can lead to pain and instability.<sup>1</sup> Normally, the patella lies laterally with the knee extended, but in early flexion the patella moves medially as it engages in the trochlea. As the knee continues to flex, the patella flexes and translates distally.<sup>21</sup> By 45°, the patella is fully engaged in the trochlear groove throughout the remainder of the knee's range of motion (ROM).

Lateral release procedures, as described in the literature, result in sectioning of both layers of the lateral retinaculum. In a biomechanical study, Merican and colleagues<sup>22</sup> found that staged release of the lateral retinaculum reduced the medial stability of the patellofemoral joint progressively, making it easier to push the patella medially. At 30° of flexion, the transverse fibers of the midsection of the lateral retinaculum were found to be the main contributor to the lateral restraint of the patella.

---

**Authors' Disclosure Statement:** The authors report no actual or potential conflict of interest in relation to this article.

When the release extends too far proximally, the transverse fibers that anchor the lateral patella and the vastus lateralis oblique tendon to the iliotibial band are disrupted. Subsequent loss of a dynamic muscular pull in the orientation of the lateral stabilizing structures results in medial subluxation in a range from full knee extension to about 30° of flexion.

Furthermore, the attachments of the LPFL and the orientation of its fibers suggest that the LPFL may have a significant role in limiting medial excursion of the patella. Vieira and colleagues<sup>23</sup> resected the LPFL in 10 fresh cadaver knees. They noticed that, after resection, the patella spontaneously traveled medially, demonstrating the importance of this ligament in patellar stability. In cases of isolated MPS, there have been no reports of associated pathology, such as muscular imbalance

or coronal/rotational malalignment of the lower extremity. With an intact lateral retinaculum, medial subluxation is likely caused by pathology in the normal histologic structure of the LPFL and lateral retinaculum. However, the histologic structure of the LPFL and its contribution to the understanding of the pathoetiology of MPS have not been documented.

### Diagnosis

MPS diagnosis can be challenging. Often, clinical examination findings are subtle, and radiographs may not show significant pathology. The most accurate diagnosis is obtained by combining patient history, physical examination findings, imaging studies, and diagnostic arthroscopy.

### Patient History

Patients with MPS report chronic pain localized to the inferior medial patella and anterior-medial joint line. Occasionally, they complain of crepitus and intermittent swelling. Other symptoms include pain with knee flexion activity, such as squatting and climbing or descending stairs. Some patients describe episodes of giving way and feelings of instability. Often, they are aware the direction of instability is medial. The pain typically is not relieved by medication, physical therapy, or bracing.

### Physical Examination

MPS must be identified by clinical examination. Peripatellar tenderness is typically noted. There is often no effusion or crepitus, but the patella is unstable in early flexion. Active and passive ROM is painful through the first 30° of knee flexion. The patient may have a positive medial apprehension test<sup>7</sup> in which he or she experiences apprehension of the patella being subluxated with a medially directed force on the lateral border of the patella.

The gravity subluxation test described by Nonweiler and DeLee<sup>6</sup> is useful in detecting MPS after lateral release and indicates that the vastus lateralis muscle has been detached from the patella and that the lateral retinaculum is lax. In this test, the patient is positioned in the lateral decubitus position with the involved knee farthest from the table. In this position, gravity causes the patella to subluxate out of the trochlea. The test is positive for MPS when a voluntary contraction of the quadriceps does not center the patella into the trochlear groove. Patients with MPS without previous lateral release can have the patella subluxate medially in the lateral decubitus position, but it is pulled back into the trochlea with active quadriceps contraction (Figure 1).

Patients with MPS often have lateral patellar laxity (LPL), which allows the patella to rotate upward on the lateral side and skid across the medial facet of the femoral trochlea. A physical examination sign combining lateral patellar glide and tilt was described by Shneider<sup>24</sup> to identify LPL. This “lateral patellar float” sign is present when the patella translates laterally and rotates or tilts upward with medial pressure on the patella (Figure 2). Another maneuver to test for subtle MPS involves manually centering the patella in the trochlea during

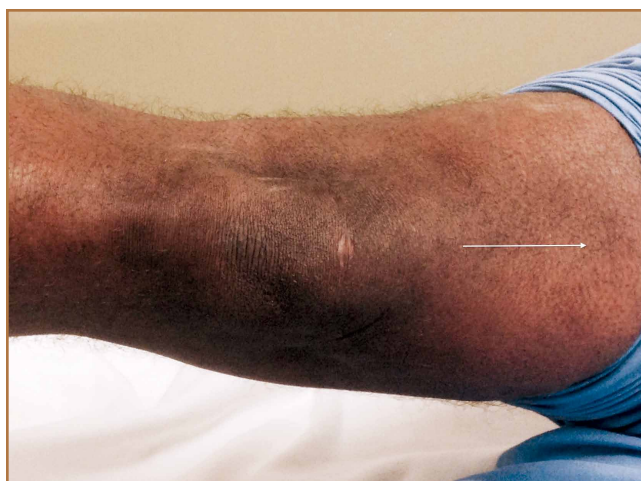

Figure 1. Right knee of patient in left lateral decubitus position. Leg is passively abducted by examiner with quadriceps relaxed and knee extended. With active quadriceps contraction (white arrow), patella is pulled back into trochlea. This is the negative gravity subluxation test.

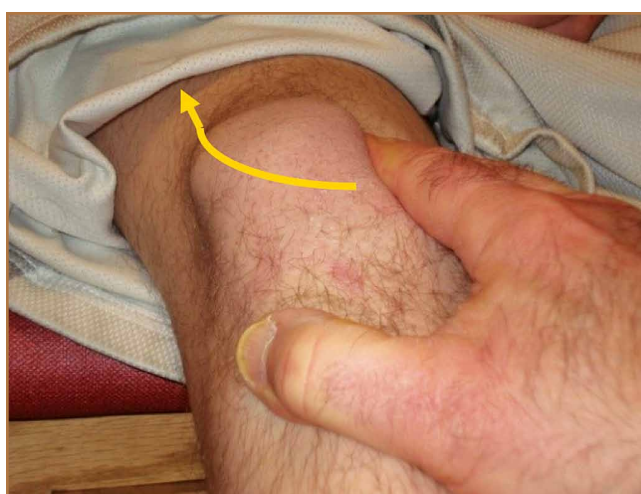

Figure 2. Lateral patellar float sign identifying lateral patellar laxity.

active knee flexion and extension. The involved knee is examined in the seated position. The examiner attempts to center the patella in the trochlea with a laterally directed force from the examiner's thumb on the medial border of the patella. This will usually provide immediate relief as the patient actively ranges the knee.

### Imaging Studies

Diagnostic imaging is a crucial component of the evaluation and treatment decision process. Plain radiographs often are not helpful in diagnosing MPS but may provide additional information.<sup>5</sup> A variety of radiographic measurements have been described as indicators of structural disease, but there is a lack of comprehensive information recommending radiographic evaluation and interpretation of patients with patellofemoral

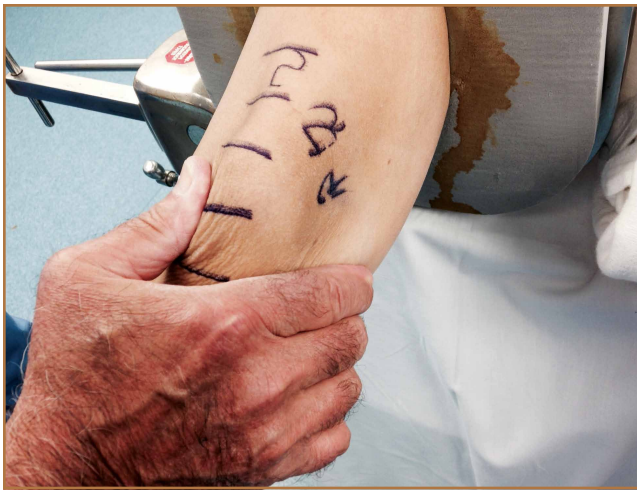dysfunction. It is crucial that orthopedic surgeons have common and consistent radiographic views for plain radiographic assessment that can serve as a basis for accurate diagnosis and surgical decision-making.

Standard knee radiographs should include a standing anteroposterior view of bilateral knees, a standing lateral view of the symptomatic knee in 30° of flexion, a patellar axial view, and a tunnel view. These views, occasionally combined with magnetic resonance imaging (MRI), can yield information vital to surgical decision-making. Image quality is highly technique-dependent, and variability in patient positioning can substantially affect the ability to properly diagnose structural abnormalities. For improved diagnostic accuracy and disease classification, radiographs must be obtained with use of the same standardized imaging protocol.

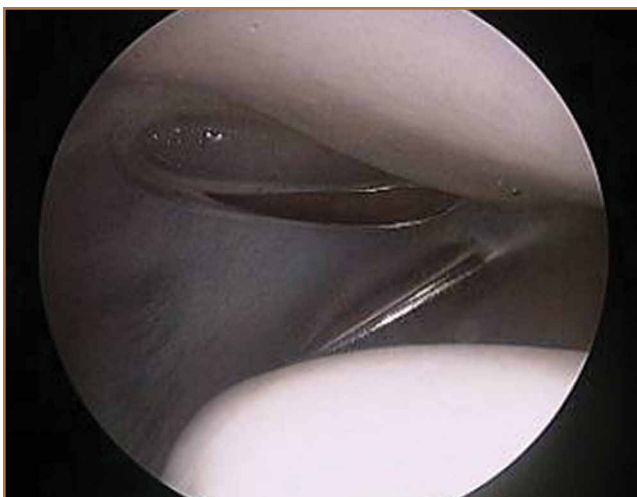Kinetic MRI was shown by Shellock and colleagues<sup>25</sup> to provide diagnostic information related to patellar malalignment. As kinetic MRI can image the patellofemoral joint within the initial 20° to 30° of flexion, it is useful in detecting some of the more subtle patellar tracking problems. In their study of 43 knees (40 patients) with symptoms after lateral release, Shellock and colleagues<sup>25</sup> found that 27 knees (63%) had medial subluxation of the patella as the knee moved from extension to flexion. Furthermore, MPS was noted on the contralateral, unoperated knee in 17 (43%) of the 40 patients.

### Diagnostic Arthroscopy

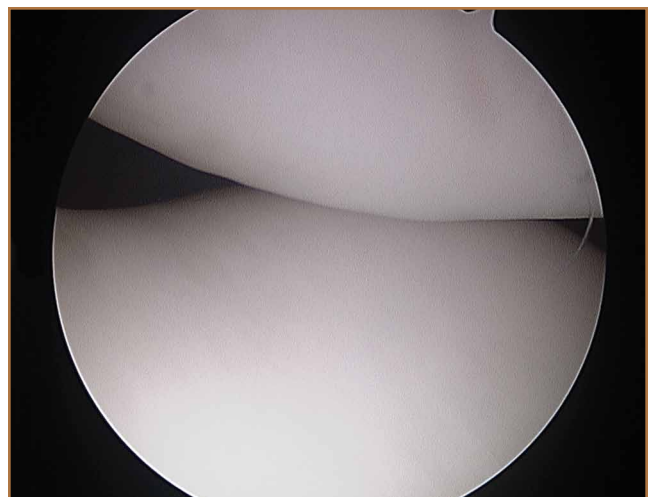
Once MPS is suspected after a thorough history and physical examination, examination under anesthesia accompanied by diagnostic arthroscopy confirms the diagnosis. Lateral forces are applied to the patella in full knee extension and 30° of flexion (Figure 3). During arthroscopy, the patellofemoral compartment is viewed from the anterolateral portal. With the knee at full extension, the lateral laxity and medial tilt of the patella can be identified (Figure 4). As the knee is flexed



**Figure 3.** Examination of right knee with patient under anesthesia reveals medial subluxation at 30° of knee flexion.



**Figure 4.** Arthroscopic picture of patellofemoral compartment (right knee) viewed from anterolateral portal shows lateral patellar laxity at full knee extension.



**Figure 5.** Arthroscopic picture of patellofemoral compartment (right knee) viewed from anterolateral portal shows medial patellar subluxation at 30° of knee flexion.

to 30°, the patella moves medially and can subluxate over the edge of the medial facet of the trochlea (Figure 5).

### Treatment

#### Nonsurgical Management

Treatment of MPS depends entirely on making an accurate diagnosis and determining the degree of impairment. Patients with symptomatic MPS should initially undergo supervised rehabilitation focusing on balancing the medial and lateral forces that influence patellar tracking. Patients should be evaluated for specific muscle tightness, weakness, and biomechanical abnormalities. Each problem should be addressed with an individualized rehabilitation prescription. Emphasis is placed on balance, proprioception, and strengthening of the quadriceps, hip abductors/external rotators, and abdominal core muscle groups.

In some patients, symptomatic MPS may be reduced with a patella-stabilizing brace with a medial buttress.<sup>3,5,26</sup> Although bracing should be regarded as an adjuvant to a structured physical therapy program, it can also be helpful in confirming the diagnosis of MPS. Shannon and Keene<sup>3</sup> reported that all patients in their study experienced significant pain relief and decreased medial patellar subluxations when they wore a medial patella-stabilizing brace. Shellock and colleagues<sup>25</sup> used

kinematic MRI to investigate the effect of a patella-realignment brace and found that bracing counteracted patellar subluxation in the majority of knees studied.

#### Surgical Management

When conservative management fails and patients continue to experience pain and instability, surgical intervention is often required. Although various surgical techniques have been used (Table),<sup>3-6,8-10,14,15,27,28</sup> the optimal surgical treatment for MPS has not been identified.

**Lateral Retinaculum Imbrication.** Lateral retinaculum imbrication has been used to centralize patella tracking and stabilize the patella. Richman and Scheller<sup>5</sup> reported on a 17-year-old patient who had isolated medial subluxation of the patella without having undergone a previous lateral release. At 3-month follow-up, there was no recurrent instability; there was only intermittent medial knee soreness with weight-bearing activity.

**Lateral Retinaculum Repair/Reconstruction.** Hughston and colleagues<sup>8</sup> treated 65 knees for MPS. Most had undergone lateral release. Of the 65 knees, 39 were treated with direct repair of the lateral retinaculum, and 26 with reconstruction of the lateral patellotibial ligament using locally available tissue,

**Table. Operative Treatment Options for Medial Patellar Subluxation**

Treatment	Literature	Study Design	Outcome
Lateral retinaculum imbrication	Richman & Scheller <sup>5</sup>	Report of 1 patient with 3-month follow-up	No patellar instability; intermittent soreness with weight-bearing
Medial retinaculum release	Shannon & Keene <sup>3</sup>	Review of 9 patients with mean follow-up of 2.7 years	Excellent (6), good (3)
Lateral retinaculum reconstruction	Hughston et al <sup>8</sup>	Review of 63 patients (65 knees) with mean follow-up of 53.7 months	Good or excellent (80%), fair or poor (20%)
	Nonweiler & DeLee <sup>6</sup>	Review of 5 patients with mean follow-up of 3.3 years	Excellent (3), good (2)
	Akşahin et al <sup>28</sup>	Report of 1 patient with 1-year follow-up	Vigorous recreational activity
	Abhaykumar & Craig <sup>9</sup>	Review of 4 knees with follow-up of 5-7 years	Normal patellar tracking, full range of motion, painful scar
	Johnson & Wakeley <sup>26</sup>	Report of 1 patient with 12-month follow-up	Light activity fine, patellofemoral pain with strenuous activity
	Sanchis-Alfonso et al <sup>14</sup>	Review of 17 patients with mean follow-up of 56 months	Improvement in Lysholm score from 36.4 preoperatively to 86.1 postoperatively Good or excellent (65%)
Lateral patellofemoral ligament reconstruction	Teitge & Torga Spak <sup>10</sup>	Review of 60 patients; follow-up not applicable	Excellent (100%)
	Saper & Shneider <sup>4</sup>	Report of 1 patient with 2-year follow-up	Excellent functional outcome
	Saper & Shneider <sup>27</sup>	Review of 5 patients with mean follow-up of 17.4 months	No residual instability Good or excellent (100%) Mean postoperative Kujala score of 92 points
	Borbas et al <sup>15</sup>	Report of 1 patient with 1 year follow-up	Free of pain and very satisfied

such as strips of iliotibial band or patellar tendon. Results were good to excellent in 80% of patients at a mean follow-up of 53.7 months. Nonweiler and DeLee<sup>6</sup> reconstructed the lateral retinaculum in 5 patients with MPS that developed after isolated lateral retinacular release. Four (80%) of the 5 patients had no symptoms or physical signs of instability at a mean follow-up of 3.3 years. Results were excellent (3 knees) and good (2 knees) according to the Merchant and Mercer rating scale. Akşahin and colleagues<sup>28</sup> reported on a single case of spontaneous medial patellar instability. At surgery, imbrication of the lateral structures failed to prevent the medial subluxation. Lateral patellofemoral ligament augmentation was performed using an iliotibial band flap that effectively corrected the instability. At 1 year, the patient was characterized as engaging in vigorous recreational activity, according to the clinical score defined by Hughston and colleagues.<sup>8</sup> He had mild pain with competitive sports but no pain with daily activity. Abhaykumar and Craig<sup>9</sup> reported on 4 surgically treated knees with medial instability. They reconstructed the lateral retinaculum using a strip of fascia lata. By follow-up (5-7 years), each knee had its instability resolved and full ROM restored. Johnson and Wakeley<sup>26</sup> reported on a case of iatrogenic MPS after lateral release. Treatment consisted of mobilization and direct repair of the lateral retinaculum. At 12-month follow-up, there was no instability. Although symptom-free with light activity, the patient had patellofemoral pain with strenuous activity. Sanchis-Alfonso and colleagues<sup>14</sup> reported the results of isolated lateral retinacular reconstruction for iatrogenic MPS in 17 patients. At mean follow-up of 56 months, results were good or excellent in 65% of patients, and the Lysholm score improved from 36.4 preoperatively to 86.1 postoperatively.

**Medial Retinaculum Release.** Medial retinaculum release has been used as an alternative to open reconstruction. Shannon and Keene<sup>3</sup> reported the results of medial retinacular release procedures on 9 knees. Four (44%) of the 9 patients had either spontaneous or traumatic onset of instability. All cases were treated with arthroscopic medial retinacular release, extending 2 cm medial to the superior pole of the patella down to the anteromedial portal. This avoided releasing the attachment of the vastus medialis oblique muscle to the patella and removing its dynamic medial stabilizing force. At a mean follow-up of 2.7 years, both medial subluxation and knee pain were relieved in all 9 knees without complications or further realignment surgery. Results were excellent in 6 knees (66.7%) and good in 3 knees (33.3%). Shannon and Keene<sup>3</sup> emphasized that the procedure should not be used in patients with hypermobile patellae or in cases of failed lateral retinacular releases in which MPS is not clearly and carefully documented.

**LPFL Reconstruction.** Before coming to our practice, most patients have tried several months of formal physical rehabilitation, medications, and bracing. Many have already had surgical procedures, including arthroscopy, lateral release, and tibial tubercle transfer. When the diagnosis of MPS is suspected after a thorough history and physical examination, LPFL reconstruction is offered. Management of MPS with LPFL reconstruction has yielded excellent and reliable clinical results. Teitge and

Torga Spak<sup>10</sup> described an LPFL reconstruction technique that is used as a salvage procedure in managing medial iatrogenic patellar instability (the patient's own quadriceps tendon is used). In their experience, direct repair or imbrication of the lateral retinaculum failed to provide long-term stability because medial excursion usually appeared after 1 year. The 60 patients' outcomes were excellent with respect to patellar stability, and there were no cases of recurrent subluxation. Borbas and colleagues<sup>15</sup> reported a case of LPFL reconstruction in a symptomatic medial subluxated patella resulting from TKA and extended lateral release. Using a free gracilis autograft through patellar bone tunnels to reconstruct the LPFL, the patient was free of pain and very satisfied with the result at 1 year postoperatively. Our current strategy is anatomical reconstruction of the LPFL using a quadriceps tendon graft and no bone tunnels, screws, or anchors in the patella.<sup>27</sup> We previously reported a single case of isolated medial instability.<sup>4</sup> At 2-year follow-up, there was no recurrent instability, and the functional outcome was excellent. This LPFL reconstruction method has been used in 10 patients with isolated MPS. There has been no residual medial subluxation on follow-up ranging from 3 months to 2 years. Outcome studies are in progress.

**Rehabilitation.** The initial goal of rehabilitation after surgical reconstruction of the lateral retinaculum or LPFL is to protect the healing soft tissues, restore normal knee ROM, and normalize gait. The knee is immobilized in a brace for weight-bearing activity for 4 to 6 weeks, until limb control is sufficient to prevent rotational stress on the knee. Gradual increase to full weight-bearing without bracing is permitted as quadriceps strength is restored. As motion is regained, strength, balance, and proprioception are emphasized for the entire lower extremity and core.

Functional limb training, including rotational activity, begins at 12 weeks. As strength and neuromuscular control progress, single-leg activity may be started with particular attention to proper alignment of the pelvis and the entire lower extremity. For competitive or recreational athletes, the final stages of rehabilitation focus on dynamic lower extremity control during sport-specific movements. Patients return to unrestricted activity by 6 months to 1 year after surgery.

## Summary

MPS is a disabling condition that can limit daily functional activity because of apprehension and pain. Initially described as a complication of lateral retinacular release, isolated MPS can occur in the absence of a previous lateral release. Thorough physical examination and identification during arthroscopy are crucial for proper MPS diagnosis and management. When nonsurgical measures fail, LPFL reconstruction can provide patellofemoral stability and excellent functional outcomes.

Dr. Saper is Fellow, The Andrews Institute for Orthopaedics & Sports Medicine, Gulf Breeze, Florida. Dr. Saper was a resident at McLaren Greater Lansing at the time the article was written. Dr. Shneider is Professor, Department of Orthopaedic Surgery, McLaren Greater Lansing, Lansing, Michigan; and Orthopaedic Surgeon, Mid-Michigan Orthopaedic Institute, East Lansing, Michigan.

Address correspondence to: David A. Shneider, MD, 830 West Lake Lansing Road #190, East Lansing, MI 48823 (tel, 517-333-3777; email, f27david@aol.com).

*Am J Orthop.* 2015;44(11):499-504. Copyright Frontline Medical Communications Inc. 2015. All rights reserved.

### References

1. Marumoto JM, Jordan C, Akins R. A biomechanical comparison of lateral retinacular releases. *Am J Sports Med.* 1995;23(2):151-155.
2. Betz RR, Magill JT, Lonergan RP. The percutaneous lateral retinacular release. *Am J Sports Med.* 1987;15(5):477-482.
3. Shannon BD, Keene JS. Results of arthroscopic medial retinacular release for treatment of medial subluxation of the patella. *Am J Sports Med.* 2007;35(7):1180-1187.
4. Saper MG, Shneider DA. Medial patellar subluxation without previous lateral release: a case report. *J Pediatr Orthop B.* 2014;23(4):350-353.
5. Richman NM, Scheller AD Jr. Medial subluxation of the patella without previous lateral retinacular release. *Orthopedics.* 1998;21(7):810-813.
6. Nonweiler DE, DeLee JC. The diagnosis and treatment of medial subluxation of the patella after lateral retinacular release. *Am J Sports Med.* 1994;22(5):680-686.
7. Hughston JC, Deese M. Medial subluxation of the patella as a complication of lateral retinacular release. *Am J Sports Med.* 1988;16(4):383-388.
8. Hughston JC, Flandry F, Brinker MR, Terry GC, Mills JC 3rd. Surgical correction of medial subluxation of the patella. *Am J Sports Med.* 1996;24(4):486-491.
9. Abhaykumar S, Craig DM. Fascia lata sling reconstruction for recurrent medial dislocation of the patella. *The Knee.* 1999;6(1):55-57.
10. Teitge RA, Torga Spak R. Lateral patellofemoral ligament reconstruction. *Arthroscopy.* 2004;20(9):998-1002.
11. Kusano M, Horibe S, Tanaka Y, et al. Simultaneous MPFL and LPFL reconstruction for recurrent lateral patellar dislocation with medial patellofemoral instability. *Asia-Pac J Sports Med Arthrosc Rehabil Technol.* 2014;1:42-46.
12. Saper MG, Shneider DA. Simultaneous medial and lateral patellofemoral ligament reconstruction for combined medial and lateral patellar subluxation. *Arthrosc Tech.* 2014;3(2):e227-e231.
13. Udagawa K, Niki Y, Matsumoto H, et al. Lateral patellar retinaculum reconstruction for medial patellar instability following lateral retinacular release: a case report. *Knee.* 2014;21(1):336-339.
14. Sanchis-Alfonso V, Montesinos-Berry E, Monllau JC, Merchant AC. Results of isolated lateral retinacular reconstruction for iatrogenic medial patellar instability. *Arthroscopy.* 2015;31(3):422-427.
15. Borbas P, Koch PP, Fucentese SF. Lateral patellofemoral ligament reconstruction using a free gracilis autograft. *Orthopedics.* 2014;37(7):e665-e668.
16. Fulkerson JP, Gossling H. Anatomy of the knee joint lateral retinaculum. *Clin Orthop Relat Res.* 1980;153:183-188.
17. Kaplan E. Some aspects of functional anatomy of the human knee joint. *Clin Orthop Relat Res.* 1962;23:18-29.
18. Reider B, Marshall J, Koslin B, Ring B, Girgis F. The anterior aspect of the knee joint. *J Bone Joint Surg Am.* 1981;63(3):351-356.
19. Navarro MS, Navarro RD, Akita Junior J, Cohen M. Anatomical study of the lateral patellofemoral ligament in cadaver knees. *Rev Bras Ortop.* 2008;43(7):300-307.
20. Navarro MS, Beltrani Filho CA, Akita Junior J, Navarro RD, Cohen M. Relationship between the lateral patellofemoral ligament and the width of the lateral patellar facet. *Acta Orthop Bras.* 2010;18(1):19-22.
21. Salsich GB, Ward SR, Terk MR, Powers CM. In vivo assessment of patellofemoral joint contact area in individuals who are pain free. *Clin Orthop Relat Res.* 2003;417:277-284.
22. Merican AM, Kondo E, Amis AA. The effect on patellofemoral joint stability of selective cutting of lateral retinacular and capsular structures. *J Biomech.* 2009;42(3):291-296.
23. Vieira EL, Vieira EÁ, da Silva RT, Berfein PA, Abdalla RJ, Cohen M. An anatomic study of the iliotibial tract. *Arthroscopy.* 2007;23(3):269-274.
24. Shneider DA. Lateral patellar laxity—identification, significance, treatment. Poster session presented at: Annual Meeting of the American Academy of Orthopaedic Surgeons; February 25-28, 2009; Las Vegas, NV.
25. Shellock FG, Mink JH, Deutsch A, Fox JM, Ferkel RD. Evaluation of patients with persistent symptoms after lateral retinacular release by kinematic magnetic resonance imaging of the patellofemoral joint. *Arthroscopy.* 1990;6(3):226-234.
26. Johnson DP, Wakeley C. Reconstruction of the lateral patellar retinaculum following lateral release: a case report. *Knee Surg Sports Traumatol Arthrosc.* 2002;10(6):361-363.
27. Saper MG, Shneider DA. Lateral patellofemoral ligament reconstruction using a quadriceps tendon graft. *Arthrosc Tech.* 2014;3(4):e445-e448.
28. Akshahin E, Yumrukcal F, Yüksel HY, Doğruyol D, Celebi L. Role of pathophysiology of patellofemoral instability in the treatment of spontaneous medial patellofemoral subluxation: a case report. *J Med Case Rep.* 2010;4:148.

---

*This paper will be judged for the Resident Writer's Award.*

---