

Total Shoulder Arthroplasty Outcome for Treatment of Osteoarthritis: A Multicenter Study Using a Contemporary Implant

Thomas W. Wright, MD, Pierre-Henri Flurin, MD, Lynn Crosby, MD, Aimee M. Struk, MEd, ATC, and Joseph D. Zuckerman, MD

Abstract

In this article, we present clinical results of primary total shoulder arthroplasty for osteoarthritis using an implant that provides dual eccentricity and variable neck and version angles for reconstruction of proximal humeral anatomy.

Two hundred one patients with symptomatic osteoarthritis underwent 218 total shoulder arthroplasties with a fourth-generation anatomical shoulder and a replicator plate at 4 centers between August 1, 2006, and December 31, 2010. Fourth-generation implants allow for varying humeral neck and version angles and have dual eccentricity so as to be consistently able to cover the humeral head cut.

At a mean follow-up of 3 years (minimum, 2 years), there was an 81% follow-up rate. At final follow-up, 3 objective

measures were significantly ($P < .05$) improved over preoperative levels: average active elevation (preoperative, 92°; postoperative, 137°), active external rotation (pre, 15°; post, 42°), and active internal rotation (pre, S3; post, L2).

The functional outcome scores that were significantly ($P < .05$) improved at final follow-up were Constant normalized (pre, 39; post, 79), Shoulder Pain and Disability Index (pre, 86; post, 20), Simple Shoulder Test (pre, 3.3; post, 10), UCLA Shoulder Rating Scale (pre, 13; post, 31), and American Shoulder and Elbow Surgeons Shoulder Assessment (pre, 33; post, 85). Complications were noted in 11% of the shoulders. The most common complications were rotator cuff failure (13, 6%) and infection (5, 2%).

Anatomical total shoulder arthroplasty (TSA) is an effective treatment for advanced osteoarthritis (OA) of the glenohumeral joint.¹⁻⁴ Over the past 40 years, since the early reports appeared, the implants have evolved from the early monoblock humeral component to modular components, variable neck angled components with eccentric heads, and components that can provide variable neck angles, version angles, and dual eccentricity to match the anatomy of the proximal humerus. The goal of the new implants is to replicate the individual patient's native anatomy using a combination of modularity, multiple neck and version angles, and dual eccentricity of the neck and head. The flexibility of the implant system is made possible by a replicator plate. There are few reports on outcomes of using these new implants for OA.

In this article, we report outcomes of using a dual eccentric, variable neck angle, variable version angle implant with a replicator plate for the treatment of OA of the shoulder at 4 centers.

Materials and Methods

The Western Institutional Review Board approved this study, and consent was prospectively obtained and retrospectively reviewed.

The data banks of a 4-center consortium were queried. Only primary TSA patients treated for OA with a fourth-generation Exactech Equinoxe implant (Exactech, Inc.) were included. For the center to be included, it had to have an 80% patient follow-up rate at a minimum of 2 years. Four centers qualified for inclusion: University of Florida, Medical College of Georgia, New York University, and Bordeaux-Merignac Clinic. Data were obtained on surgeries sequentially performed between August 1, 2006, and December 31, 2010. All data were obtained prospectively using a common data collection format.

The Equinoxe anatomical TSA allows for independent adaptation of neck angle and humeral version and provides 2 variable offset times (1 on replicator plate, 1 on humeral head) for matching the native anatomy in more than 99% of cases⁵ (Figure). The replicator plate is eccentric and can be angled 7.5° in any direction and rotated 360° to provide humeral head coverage. Once its optimal position is obtained, the plate is permanently fixed to the humeral stem using a breakaway screw. Some contemporary implants have similar features.

There were 218 primary shoulder arthroplasties performed on 201 patients (98 male, 103 female). Mean age at time of

Authors' Disclosure Statement: Ms. Struk's salary was supported in part by an institutional grant from Exactech, the manufacturer of the implant used in the study reported here. Dr. Wright, Dr. Flurin, Dr. Crosby, and Dr. Zuckerman are consultants for and receive royalties from Exactech.

surgery was 67 years (range, 31-87 years), and mean follow-up was 36 months (range, 24-72 months). The collective follow-up rate at the 3-year mean follow-up and 2-year minimal follow-up was 81%. Eleven shoulders had a cemented stem, and 207 had an uncemented stem. Forty-eight shoulders used the 1.5-mm replicator plate, and 170 used the 4.5-mm offset replicator plate. The patients in this study were typically not very healthy: mean American Society of Anesthesiologists (ASA) score was 2.57 (range, 1-3).

Five outcome scores were calculated from the prospectively obtained data: Constant normalized, Shoulder Pain and Disability Index (SPADI), Simple Shoulder Test (SST), UCLA Shoulder Rating Scale (UCLA), and American Shoulder and Elbow Surgeons Shoulder Assessment (ASES). Before initiating data collection, we developed the Metric Form⁶ so we could calculate multiple scores while asking the minimal possible number of questions. This could be done for all 5 outcome scores, as their questions have significant overlap.

Objective outcomes included active external rotation, active scaption, active abduction, and active internal rotation. Complications, including revisions, were noted and analyzed. We focus on functional outcomes and do not present radiographic outcomes.

Results

A 2-tailed unpaired t test was used to compare preoperative values with final outcome values ($P < .05$). Four objective outcomes were significantly improved over preoperative levels: active external rotation (preoperative, 15°; postoperative, 42°), active scaption (pre, 92°; post, 137°), active abduction (pre,

80°; post, 121°), and active internal rotation (pre, S3; post, L2). The functional outcome scores that were significantly ($P < .05$) improved at final follow-up were Constant normalized (pre, 39; post, 79), SPADI (pre, 86; post, 20), SST (pre, 3.3; post, 10), UCLA (pre, 13; post, 31), and ASES (pre, 33; post, 85).

The outcome improvements at latest follow-up were active external rotation (+28), active scaption (+45), active abduction (+42), active internal rotation (+6 anatomical segments), Constant normalized (+40), SPADI (-66), SST (+6.7), UCLA (+18), and ASES (+52).

There were 32 complications in 25 shoulders. There were no bilateral complications. Seven shoulders had multiple complications, of which many were not independent events. For example, rotator cuff deficiency was associated with instability, and infection was associated with glenoid loosening. One patient had 2 procedures, the first an arthroscopic release and the second a revision shoulder arthroplasty for glenoid loosening. The most common postoperative complication was rotator cuff failure (RCF) or suspected RCF (13 shoulders, including 8 treated with revision arthroplasty). RCF occurred most commonly at the rotator cuff interval, followed by the subscapularis and the supraspinatus. RCF location was based on computed tomography scan or intraoperative observation. The few subscapularis failures occurred with both subscapularis tendon repair and osteotomy. The high RCF rate may derive from scrutinizing postoperative radiographs and was not necessarily confirmed with repeat surgery. We think this represents a more realistic estimate of true postoperative rotator cuff dysfunction, rather than including only reoperated cases. The second most common complication was infection

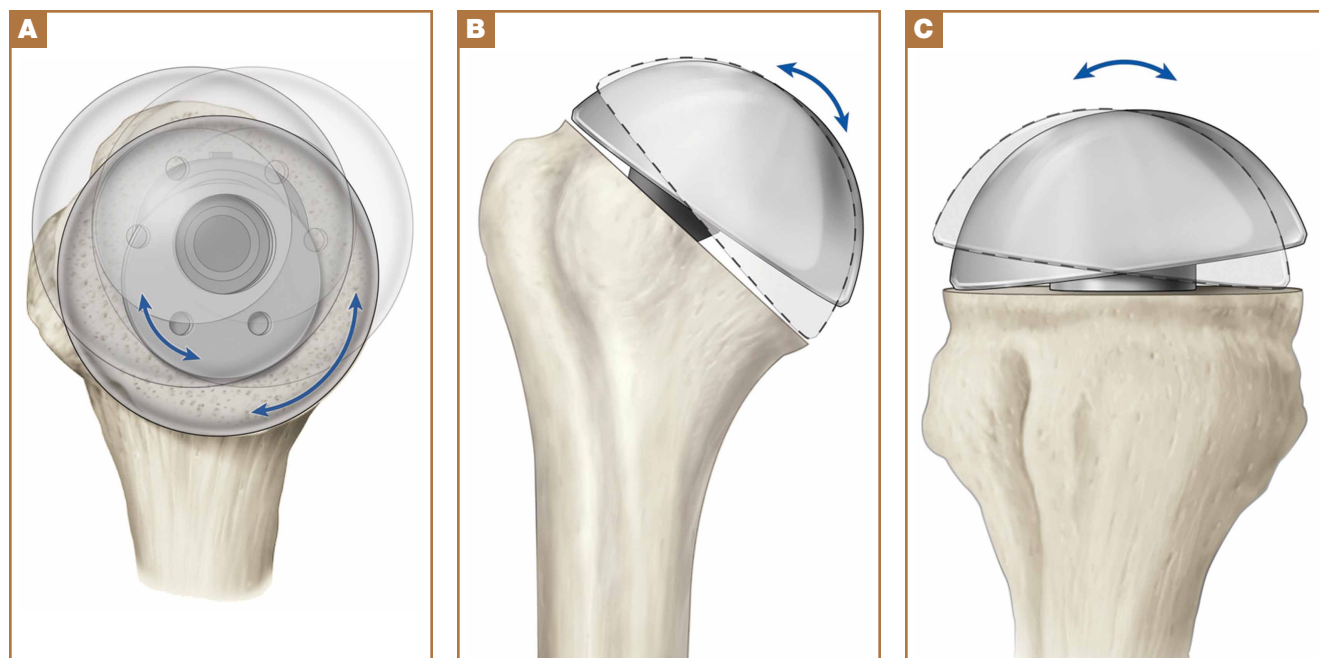


Figure. (A) Schematic of replicator plate shows dual eccentricity of replicator plate and humeral head that covers more than 99% of humeral head cuts. (B) Replicator plate accommodates any humeral neck angle (varus–valgus) from 125° to 140°. (C) Version can be changed from 7.5° anteversion relative to implanted stem to 7.5° retroversion relative to implanted stem.

Table. Total Shoulder Arthroplasties (N = 218), Complications and Treatments

Treatment	Complication							Total
	Rotator Cuff Failure/Deficiency	Joint Infection	Stiffness	Instability	Implant Loosening	Nerve Issue	Wound Complication	
Revision	8	5	0	3	4	1	0	21
Nonrevision surgery	0	0	3	0	0	0	2	5
Nonsurgery	5	0	0	1	0	0	0	6
Total	13	5	3	4	4	1	2	32

(6 shoulders, 1 with a superficial suture abscess and 5 with deep infections). Other complications were instability (4, with 2 caused by rotator cuff insufficiency), glenoid loosening (4, with 2 caused by infection), stiffness (3), nerve issue (1), and hematoma evacuation (1).

In 21 shoulders, these complications were treated with revision shoulder arthroplasty (16 shoulders), arthroscopic capsular release (3), evacuation of postoperative hematoma (1), and débridement of suture abscess (1). The 16 revision shoulder arthroplasties performed were conversion to reverse shoulder arthroplasty (11 shoulders) and placement of an antibiotic spacer for infection (5). The stem was left in place for all revisions, excluding those for infection. This is a significant advantage of the modular platform stem. Details of the complications and treatments are listed in the **Table**. There was no difference in health status between patients with a complication (ASA, 2.57) and those without one (ASA, 2.56).

Discussion

The implant described in this article consists of a metaphyseal press-fit stem, a replicator plate, multiple eccentric humeral heads, and a glenoid of multiple sizes with 2 radii of curvatures used to match the patient's native anatomy and still maintain the appropriate radius of curvature mismatch between the humeral head and the glenoid. Between the eccentricity in the replicator plate and the eccentricity in the humeral head, almost any humeral head cut can be covered, more than 99% of the time.¹ However, it remains to be seen if a versatile implant that comes close to matching the patient's native anatomy will make a difference clinically.

The objective and functional outcomes in this study compare well with those of other, large TSA studies using older prostheses.¹⁻⁴ There are few reports on contemporary implants with sufficient follow-up numbers for the single diagnosis of OA. Norris and Iannotti² reported on a multicenter study of 176 patients with a Depuy Global TSA. The design of their study comes closest to that of our clinical outcome study. Nineteen surgeons were involved in their study. The follow-up rate is not clear. Their outcomes (with ours in parentheses for comparison) were active external rotation of 45° (42°), active elevation of 138° (137°), ASES of 84 (85), and SST of 9.2 (10). Norris and Iannotti² noted an overall complication rate of 13% (12% in our series). Their most common postoperative complications were RCF and glenoid loosening; ours were RCF and infec-

tion. Another multicenter study with short-term results using a contemporary prosthesis included 268 shoulders followed for a minimum of 12 months.¹ At final follow-up, Constant score was 97, active elevation was 145°, and the complication rate was 8.6%. Godenèche and colleagues¹ also noted a glenoid lucent-line rate of 58% and reported that rotator cuff pathology adversely affected outcome.

Although the overall clinical outcome results are encouraging and the complication rate is in the reported range, we believe that a focus on the major complication categories may have a significant positive impact on our patients. The present article places significant importance on reporting complications prospectively, which is more accurate than retrospective reporting. The rates of both RCF and infection, the most common complications in our study, need to be decreased. Aldinger and colleagues⁷ reported a 12% complication rate in 485 primary shoulder arthroplasties—a rate identical to ours here. In their study, nerve injuries and humeral fractures were both more common than rotator cuff tears. We think that rotator cuff deficiency after TSA is underreported because it is often based on revision surgery alone. It is also interesting that the majority of the cuff deficiencies were through the upper subscapularis rotator interval and were not a complete failure of the subscapularis repair. Not all these patients will undergo revision surgery. In the future, the RCF rate may drop with the increasingly common use of reverse shoulder arthroplasty for substandard rotator cuffs.

Use of this contemporary variable neck angle, variable version angle, dual eccentric shoulder arthroplasty with a replicator plate provides satisfying short-term clinical outcomes. Patients with less than optimal health (mean ASA, 2.57) seem to tolerate the procedure well. Continued focus on RCF and infection will have the greatest impact on the overall complication rate.

Dr. Wright is Professor of Orthopaedic Surgery, Department of Orthopaedics and Rehabilitation, University of Florida, Gainesville, Florida. Dr. Flurin is Orthopaedic Surgeon, Bordeaux-Merignac Clinic, Bordeaux-Merignac, France. Dr. Crosby is Professor and Director of Shoulder Surgery, Department of Orthopaedics, Medical College of Georgia at Georgia Regents University, Augusta, Georgia. Ms. Struk is Clinical Research Coordinator, Department of Orthopaedics and Rehabilitation, University of Florida, Gainesville, Florida. Dr. Zuckerman is Professor and Chairman of Orthopaedic Surgery, Department of Orthopaedic Surgery, New York University Hospital for Joint Diseases, New York, New York.

Address correspondence to: Thomas W. Wright, MD, Department of Orthopaedics and Rehabilitation, University of Florida, 3450 Hull Rd, 3rd Floor, Gainesville, FL 32608 (tel, 352-273-7375; email, wrightw@ortho.ufl.edu).

Am J Orthop. 2015;44(11):523-526. Copyright Frontline Medical Communications Inc. 2015. All rights reserved.

References

1. Godenèche A, Boileau P, Favard L, et al. Prosthetic replacement in the treatment of osteoarthritis of the shoulder: early results of 268 cases. *J Shoulder Elbow Surg.* 2002;11(1):11-18.
2. Norris TR, Iannotti JP. Functional outcome after shoulder arthroplasty for primary osteoarthritis: a multicenter study. *J Shoulder Elbow Surg.* 2002;11(2):130-135.
3. Razmjou H, Holtby R, Christakis M, Axelrod T, Richards R. Impact of prosthetic design on clinical and radiologic outcomes of total shoulder arthroplasty: a prospective study. *J Shoulder Elbow Surg.* 2013;22(2):206-214.
4. Walch G, Young AA, Melis B, Gazielly D, Loew M, Boileau P. Results of a convex-back cemented keeled glenoid component in primary osteoarthritis: multicenter study with a follow-up greater than 5 years. *J Shoulder Elbow Surg.* 2011;20(3):385-394.
5. Irlenbusch U, Rott O, Gebhardt K, Werner A. Reconstruction of the rotational centre of the humeral head with double eccentric adaptable shoulder prosthesis [abstract]. In: Proceedings of the European Federation of National Associations of Orthopaedics and Traumatology (EFORT); May 29-June 1, 2008; Nice, France.
6. Flurin PH, Roche CP, Wright TW, Zuckerman J, Johnson D, Christensen M. A correlation of five commonly used clinical metrics to measure outcomes in shoulder arthroplasty. In: Transactions of the 58th Annual Meeting of the Orthopaedic Research Society (ORS); February 4-7, 2012; San Francisco, CA.
7. Aldinger PR, Raiss P, Rickert M, Loew M. Complications in shoulder arthroplasty: an analysis of 485 cases. *Int Orthop.* 2010;34(4):517-524.

CALL FOR PAPERS

TIPS OF THE TRADE

We invite you to use the journal as a forum for sharing your diagnostic and treatment tips with your colleagues.

All submitted manuscripts will be subject to the journal's standard review process.

Manuscripts should be submitted via our online submission system, Editorial Manager®, at www.editorialmanager.com/AmJOrthop.

Please follow the Submission Guidelines found on our website, www.amjorthopedics.com.

