

# Successful Surgical Treatment of an Intra-neural Ganglion of the Common Peroneal Nerve

Garret L. Sobol, BA, and Todd M. Lipschultz, MD

## Abstract

Intra-neural ganglion cysts of peripheral nerves occurring within the epineural sheath are rare, and their mechanism of formation and treatment options are debated. We present a case of a 41-year-old man who presented with a complaint of lateral-sided left knee pain with numbness on the lateral side of the foot who was diagnosed with an intra-neural ganglion of the common peroneal nerve (CPN). He was treated initially with common peroneal epineural decompression only to have symptoms recur 6 weeks

postoperatively. The patient was subsequently treated utilizing the suggestions of the “unified articular theory,” which proposes a small recurrent articular branch of the CPN as the source of cyst fluid. This branch was surgically detached, leading to complete alleviation of his symptoms. When the patient was reevaluated 2 years postoperatively, his preoperative symptoms had resolved, and a follow-up magnetic resonance image showed resolution of the enlargement of the CPN.

Intra-neural ganglion cysts of peripheral nerves occurring within the epineural sheath are rare.<sup>1-7</sup> Case reports exist primarily within the neurosurgical literature, but very little in the orthopedic literature describes this condition. The peripheral nerve most commonly affected by an intra-neural ganglion is the common peroneal nerve (CPN).<sup>2,8,9</sup> Such ganglia most often afflict middle-aged men with a history of micro- or macro-trauma and present with typical clinical manifestations of calf pain and progressive symptoms of ipsilateral foot drop and lower leg paresthesia.<sup>2-5,10-12</sup> The mechanism by which these ganglia form is not well understood and, as a result, treatment options are debated.<sup>6</sup> Recent development of a “unified articular theory,” suggests that such intra-neural ganglia of the CPN are fed by a small, recurrent articular branch of the CPN.<sup>6,12,13</sup> Cadaveric studies indicate that this branch originates from the deep peroneal nerve, just millimeters distal to the bifurcation of the CPN, and extends to the superior tibiofibular joint, providing direct access for cyst fluid to enter the CPN following the path of least resistance.<sup>7,8,12,14</sup> Therefore, according to the unified articular theory, the recommended treatment involves division of the articular branch, allowing the ganglion to be decompressed.<sup>6</sup>

We present a case of a 41-year-old man with an intra-neural ganglion cyst of the CPN who was successfully treated, according to the recommendations of the unified articular theory. It is important for orthopedic surgeons to read about and recognize this condition, because knowledge of the operative technique

outlined in our report allows it to be treated quite effectively. The patient provided written informed consent for print and electronic publication of this case report.

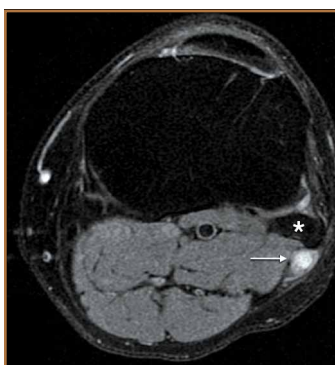
## Case Report

A 41-year-old man presented with a 2-month history of traumatic left lateral knee pain with numbness and weakness to the left foot and ankle. Initial examination showed a mild restriction of lumbosacral range of motion, with no complaints of lower back pain. Sciatic root stretch signs were negative. Strength testing of the lower extremities revealed 3+/5 strength of ankle dorsiflexion and great toe extension on the left side. There was a mild alteration in sensation to light touch on the lateral side of the left foot. Tenderness, without swelling, was present around the left fibular head. There was a positive Tinel sign over the peroneal nerve at the level of the fibular neck.

The patient was initially treated with anti-inflammatories and activity modification. An electromyogram (EMG)/nerve conduction study of the lower extremity showed a left peroneal nerve neurapraxia at the level of the fibular head. Noncontrast magnetic resonance imaging (MRI) of the left knee showed a “slightly prominent vein coursing posterior to the fibular head near the expected location of the common peroneal nerve,” according to the radiologist’s notes (Figure 1). The patient exhibited improvement with use of anti-inflammatories over several months. There was an increase in his ankle dorsiflexion strength to 4/5 and improvement in his pain and numbness.

**Authors’ Disclosure Statement:** The authors report no actual or potential conflict of interest in relation to this article.

Approximately 7 months after his initial presentation, the patient developed a marked worsening—increased numbness and weakness to ankle dorsiflexion—of his original symptoms. A repeat EMG/nerve conduction study of the lower extremity showed a persistent peroneal nerve neuropathy with a persistent denervation of the extensor hallucis longus, tibialis anterior, and extensor digitorum brevis muscles.



**Figure 1.** Axial T2-weighted magnetic resonance imaging taken prior to the first operation showing the dilated and fluid-filled common peroneal nerve (arrow), posterior to the fibular head (asterisk).

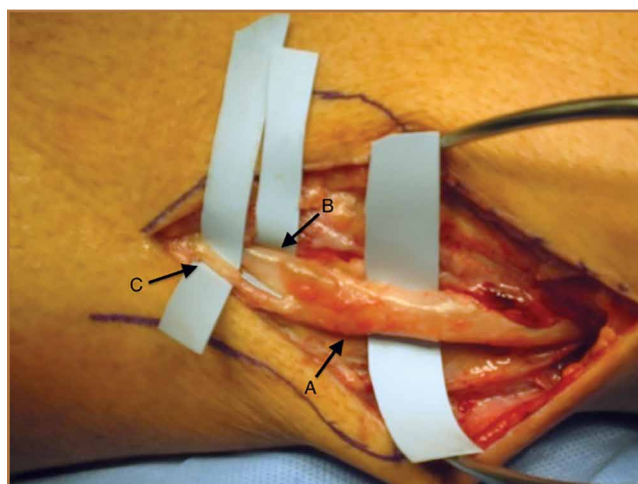
Because of continuing symptoms and increasing pain, the patient had surgery 8 months after his initial presentation. At that time, a markedly thickened peroneal nerve was identified. An incision in the epineurial sheath released a clear gelatinous fluid consistent with a ganglion cyst. Through the epineurial incision, the nerve was decompressed by manually “milking” the fluid from within the sheath. Approximately 30 mL of mucinous fluid was obtained and sent to pathology. No cells were identified.

Postoperatively, the patient noted a marked improvement in his pain. By 2 weeks postoperatively, the numbness in his foot had resolved. At 6 weeks after surgery, the strength of his tibialis anterior and extensor hallucis longus muscles had improved from 3+ to 4-, and he was free of pain.

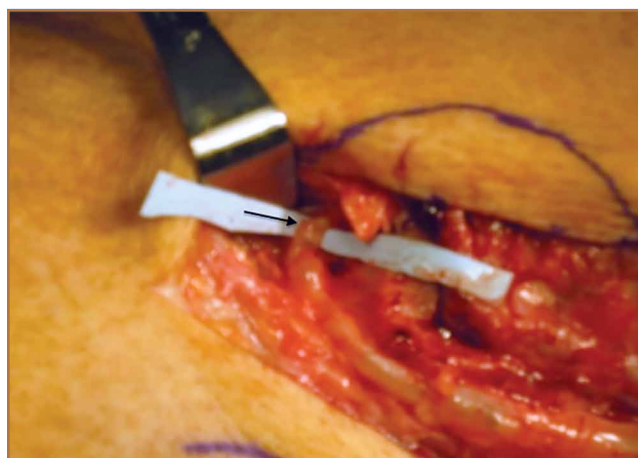
At 2 months postoperatively, the patient redeveloped pain and numbness, and noted progressive weakness of his left foot and ankle. A repeat MRI of the left knee showed a dilated tubular structure corresponding to the course of the CPN. Comparison of this MRI with the initial MRI showed that the “prominent vein” was actually the dilated CPN.

He was taken to the operating room again 5 months after his first operation. At this time, the CPN was again noted to be markedly dilated (Figure 2). The nerve was explored and a recurrent branch to the proximal tibiofibular joint was identified and divided (Figures 3, 4). Through the divided branch, the CPN could be decompressed by manually “milking” the nerve in a proximal-to-distal direction, expressing clear gelatinous fluid consistent with a ganglion cyst (Figure 5). Pathology of the excised portion of the recurrent nerve was consistent with an intraneural ganglion cyst.

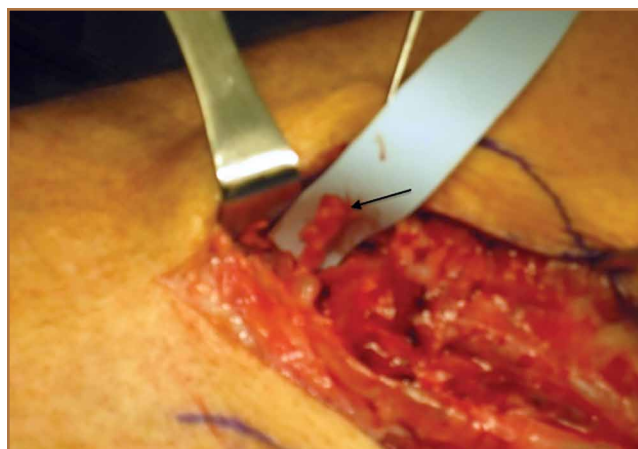
By 2 weeks postoperatively, the numbness of the patient’s left foot had completely resolved, as did his pain. By 3 months after surgery, his extensor hallucis longus strength was 5/5, and ankle dorsiflexion was 4-/5. At 6 months, his ankle dorsiflexion strength was 5/5, and he was completely asymptomatic. At 2 years postoperatively, he remained completely asymptomatic. A follow-up MRI of the left knee showed a ganglion cyst present at the proximal tibiofibular joint with



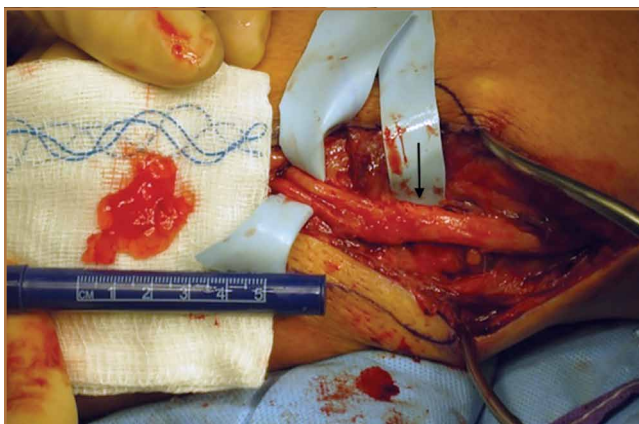
**Figure 2.** Appearance of common peroneal nerve (arrow A), deep peroneal nerve (arrow B), and superficial peroneal nerve (arrow C) prior to initial decompression.



**Figure 3.** Isolation of the articular branch of the common peroneal nerve (arrow); note its dilated appearance.



**Figure 4.** Stump of the disconnected articular branch (arrow).



**Figure 5.** Common peroneal nerve (arrow) after decompression with expressed fluid.

resolution of the intraneural ganglion cyst within the CPN (Figure 6).

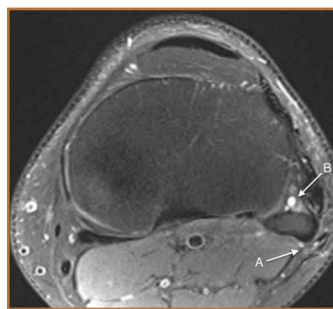
### Discussion

Intraneural ganglia of peripheral nerves are relatively rare, most commonly occurring in the CPN.<sup>6,8,9</sup> A literature search reveals that this condition is only sparsely reported in orthopedic journals. This report, therefore, describes this rare, yet curable, condition. As noted, without appropriate intervention, the condition has a high likelihood of recurrence with only a brief interruption of symptoms.<sup>6,8,9,12</sup>

The operative technique delineated in this report relies heavily on research demonstrating that peroneal intraneural ganglia develop from the superior tibiofibular joint and gain access to the CPN via the recurrent articular branch.<sup>8,13</sup> Research indicates that such ganglia preferentially proceed proximally along the deep portion of the CPN, within the epineurium.<sup>6</sup> This hypothesis was corroborated in our case by the swollen appearance of the CPN proximal to its bifurcation.

Currently, there is no consensus on treatment of intraneural ganglion cysts of the CPN. However, evidence suggests that disconnection of the recurrent branch of the CPN may be important in successfully treating the condition.<sup>6,9,14</sup> This unified articular theory was initially proposed by Spinner and colleagues<sup>12</sup> in 2003 and recommends that surgical treatment focus on the articular branch as the source of cyst fluid.<sup>6,9,12,14</sup> This theory by Spinner and coauthors<sup>12,14</sup> was substantiated in our case: Once the articular branch was disconnected, cyst fluid was easily expressed via antegrade massage through the disconnected end. Pathologic analysis of a portion of the detached articular branch is also recommended to rule out other cystic lesions, such as cystic schwannomas.<sup>14</sup>

The history of the unified articular theory began in the mid-1990s, when Dr. Robert Spinner, board certified in both orthopedic and neurologic surgery, began researching causes of intraneural ganglion cysts. At the time, such ganglia were often treated by radical resection of the nerve and the cyst. Based on his review of literature, and his own cases, Spinner<sup>15</sup> devel-



**Figure 6.** Axial T2-weighted magnetic resonance imaging 2 years after the second operation. Note the resolution of the intraneural ganglion (arrow A) with small fluid accumulation (arrow B) within the proximal tibiofibular joint.

oped the theory that, just as with extraneural ganglia, these cysts are fed by fluid from the joint. According to Spinner,<sup>9</sup> the sources of such connections were very small articular nerve branches that connect the nerve to the joint. His research led him to the original citation of such an intraneural ganglion of the ulnar nerve, first described by Dr. M. Beauchene, a French physician, in 1810.<sup>16</sup> Spinner also discovered that Beauchene's

original dissection specimen had been preserved and was displayed in a medical museum in Paris. When Spinner went to France to view the specimen, he indeed found an intraneural ganglion of the ulnar nerve. On closer inspection, Spinner also discovered a small articular nerve branch containing a "hollow lumen" that would have been capable of allowing the passage of fluid into the nerve and leading to the development of a cyst.<sup>16</sup>

In our case, in the first operation, a simple incisional decompression of the CPN was performed. Unfortunately, the ganglion cyst quickly recurred, as did the patient's symptoms. In the second surgical procedure, the articular branch connecting the peroneal nerve to the proximal tibiofibular joint was incised and disconnected from the nerve. This allowed the nerve to be decompressed and prevented a recurrence of the ganglion cyst within the nerve with complete resolution of the patient's symptoms. This difference alone most likely accounts for the rapid recurrence of symptoms after the initial operation, since the fluid was simply drained, but the source was not detached, allowing the ganglion to recur.<sup>6,12,14</sup> This is similar in theory to excising the attachment of a ganglion cyst at the wrist from the underlying joint capsule rather than performing a needle aspiration or puncturing of the cyst.<sup>12</sup>

Regarding the imaging techniques used to identify intraneural ganglia, it is essential that the surgeon be aware of the unified articular theory and the likely presence of an articular branch. Such branches are extremely small and may be easily missed on imaging and intraoperatively.<sup>17,18</sup> MRI is the best method to image these cysts because of its superior ability to visualize soft-tissue lesions.<sup>18,19</sup> Intraneural ganglion cysts typically appear as homogenous, lobulated, well-circumscribed masses that are hyperintense on T2-weighted MRI.<sup>3,19</sup> Gadolinium may also offer diagnostic utility, because these masses do not enhance with its use on T1-weighted MRI.<sup>3,17,19</sup> By employing these techniques, one may easily view most of the ganglion cyst. To image the small articular branch, Spinner and colleagues<sup>17</sup> recommend thin-section images with high-spatial resolution T2-imaging. They also advocate obtaining multiple image views and planes



to increase the likelihood of successful imaging.<sup>17</sup>

The applications of the unified articular theory also extend beyond intra-neural ganglia of the CPN. While the CPN is the most common location for intra-neural ganglion occurrence,<sup>6,17,20</sup> cases have also been described of intra-neural ganglion cysts of the tibial nerve at the proximal tibiofibular joint, as well as via the posterior tibial and medial plantar nerves at the subtalar joint within the tarsal tunnel.<sup>11,18-23</sup> Most cases involving the posterior tibial and medial plantar nerves were found in patients presenting with signs of tarsal tunnel syndrome.<sup>22,23</sup> Intra-neural ganglia have also been found within the superficial peroneal nerve arising from the inferior tibiofibular joint.<sup>20</sup> In certain cases, these ganglia have also been noted to connect to the joint via a small articular branch.<sup>19,22</sup> In 1 case of an intra-neural ganglion of the tibial nerve at the superior tibiofibular joint, initial conservative surgery led to early recurrence of symptoms.<sup>19</sup> Just as in our case, the patient returned to the operating room and, after isolation and ligation of an articular branch, the patient experienced long-term resolution of both the symptoms and the cyst.<sup>19</sup>

Given the overwhelming evidence in support of the unified articular theory, we agree with the recommendation by Spinner and colleagues<sup>19</sup> to search for an articular branch both via preoperative imaging and during the operation itself in all cases of intra-neural ganglia. Assuming the mechanism of cyst formation is the same in most cases of intra-neural ganglia, one could reasonably apply the same surgical techniques used in our case to the management of all intra-neural ganglia, drastically reducing recurrence rates.

### Conclusion

Based on research and corroborated by this case, the key to successful operative treatment of a common peroneal intra-neural ganglion is division of the recurrent articular branch, which connects the proximal tibiofibular joint to the CPN.<sup>6,9,11,12,14</sup> Evidence has shown that disconnecting the articular branch and disrupting the source of the intra-neural ganglion can resolve the condition and dramatically diminish the chance of recurrence.<sup>6,8,12,14</sup> This has become known as the unified articular theory.<sup>6,12,14</sup> Reports also suggest that, without disconnecting this articular branch, intra-neural ganglion recurrence rates may be higher than 30%.<sup>6,12,14,19</sup> This case, therefore, supports the findings of previous authors<sup>9-11,14</sup> and provides an example of successful utilization of the treatment protocol delineated by Spinner and colleagues.<sup>10,11</sup>

Mr. Sobol is a fourth-year medical student, Sidney Kimmel Medical College at Thomas Jefferson University, Philadelphia, Pennsylvania. Dr. Lipschultz practices general orthopedics with a subspecialty in upper extremity in Marlton, New Jersey.

Address correspondence to: Garret L. Sobol, BA, 522 B Lippincott Dr., Marlton, NJ 08053 (tel, 614-738-3688; e-mail, gsobol118@gmail.com).

*Am J Orthop.* 2015;44(4):E123-E126. Copyright Frontline Medical Communications Inc. 2015. All rights reserved.

### References

- Coakley FV, Finlay DB, Harper WM, Allen MJ. Direct and indirect MRI findings in ganglion cysts of the common peroneal nerve. *Clin Radiol.* 1995;50(3):168-169.
- Coleman SH, Beredjickian PK, Weiland AJ. Intra-neural ganglion cyst of the peroneal nerve accompanied by complete foot drop. A case report. *Am J Sports Med.* 2001;29(2):238-241.
- Dubuisson AS, Stevenaert A. Recurrent ganglion cyst of the peroneal nerve: radiological and operative observations. Case report. *J Neurosurg.* 1996;84(2):280-283.
- Lee YS, Kim JE, Kwak JH, Wang IW, Lee BK. Foot drop secondary to peroneal intra-neural cyst arising from tibiofibular joint. *Knee Surg Sports Traumatol Arthrosc.* 2013;21(9):2063-2065.
- Leijten FS, Arts WF, Puylaert JB. Ultrasound diagnosis of an intra-neural ganglion cyst of the peroneal nerve. Case report. *J Neurosurg.* 1992;76(3):538-540.
- Spinner RJ, Desy NM, Rock MG, Amrami KK. Peroneal intra-neural ganglia. Part I. Techniques for successful diagnosis and treatment. *Neurosurg Focus.* 2007;22(6):E16.
- Spinner RJ, Desy NM, Amrami KK. Cystic transverse limb of the articular branch: a pathognomonic sign for peroneal intra-neural ganglia at the superior tibiofibular joint. *Neurosurgery.* 2006;59(1):157-166.
- Spinner RJ, Carmichael SW, Wang H, Parisi TJ, Skinner JA, Amrami KK. Patterns of intra-neural ganglion cyst descent. *Clin Anat.* 2008;21(3):233-245.
- Spinner RJ, Atkinson JL, Scheithauer BW, et al. Peroneal intra-neural ganglia: the importance of the articular branch. Clinical series. *J Neurosurg.* 2003;99(2):319-329.
- Spillane RM, Whitman GJ, Chew FS. Peroneal nerve ganglion cyst. *AJR Am J Roentgenol.* 1996;166(3):682.
- Spinner RJ, Hébert-Blouin MN, Amrami KK, Rock MG. Peroneal and tibial intra-neural ganglion cysts in the knee region: a technical note. *Neurosurgery.* 2010;67(3 Suppl Operative):ons71-78.
- Spinner RJ, Atkinson JL, Tiel RL. Peroneal intra-neural ganglia: the importance of the articular branch. A unifying theory. *J Neurosurg.* 2003;99(2):330-343.
- Spinner RJ, Amrami KK, Wolanskyj AP, et al. Dynamic phases of peroneal and tibial intra-neural ganglia formation: a new dimension added to the unifying articular theory. *J Neurosurg.* 2007;107(2):296-307.
- Spinner RJ, Desy NM, Rock MG, Amrami KK. Peroneal intra-neural ganglia. Part II. Lessons learned and pitfalls to avoid for successful diagnosis and treatment. *Neurosurg Focus.* 2007;22(6):E27.
- Spinner RJ; Mayo Clinic. 200-year-old mystery solved: intra-neural ganglion cyst [video]. YouTube. [www.youtube.com/watch?v=5Xk4kq-yygg](http://www.youtube.com/watch?v=5Xk4kq-yygg). Published October 13, 2008. Accessed February 23, 2015.
- Spinner RJ, Vincent JF, Wolanskyj AP, Scheithauer BW. Intra-neural ganglion cyst: a 200-year-old mystery solved. *Clin Anat.* 2008;21(7):611-618.
- Spinner RJ, Dellon AL, Rosson GD, Anderson SR, Amrami KK. Tibial intra-neural ganglia in the tarsal tunnel: Is there a joint connection? *J Foot Ankle Surg.* 2007;46(1):27-31.
- Spinner RJ, Amrami KK, Rock MG. The use of MR arthrography to document an occult joint communication in a recurrent peroneal intra-neural ganglion. *Skeletal Radiol.* 2006;35(3):172-179.
- Spinner RJ, Atkinson JL, Harper CM Jr, Wenger DE. Recurrent intra-neural ganglion cyst of the tibial nerve. Case report. *J Neurosurg.* 2000;92(2):334-337.
- Stamatis ED, Manidakis NE, Patouras PP. Intra-neural ganglion of the superficial peroneal nerve: a case report. *J Foot Ankle Surg.* 2010;49(4):400.e1-4.
- Patel P, Schucany WG. A rare case of intra-neural ganglion cyst involving the tibial nerve. *Proc (Bayl Univ Med Cent).* 2012;25(2):132-135.
- Høgh J. Benign cystic lesions of peripheral nerves. *Int Orthop.* 1988;12(4):269-271.
- Poppi M, Giuliani G, Pozzati E, Acciarri N, Forti A. Tarsal tunnel syndrome secondary to intra-neural ganglion. *J Neurol Neurosurg Psychiatr.* 1989;52(8):1014-1015.