

Lateral Ulnar Collateral Ligament Reconstruction: An Analysis of Ulnar Tunnel Locations

Oke A. Anakwenze, MD, Krishn Khanna, MD, William N. Levine, MD, and Christopher S. Ahmad, MD

Abstract

We conducted a study to determine precise ulnar tunnel location during lateral ulnar collateral ligament reconstruction to maximize bony bridge and graft construct perpendicularity.

Three-dimensional computer models of 15 adult elbows were constructed. These elbow models were manipulated for simulated 4-mm tunnel drilling. The proximal ulna tunnels were placed at the radial head-neck junction and sequentially 0, 5, and 10 mm posterior to the supinator crest. The bony bridges created by these tunnels were measured.

Location of the humeral isometric point was determined and marked as the humeral tunnel location. Graft configuration was simulated. Using all the simulated ulna tunnels, we measured the proximal and distal limbs of the graft. In addition, we measured the degree of perpendicularity of the graft limbs.

The ulnar tunnel bony bridge was significantly longer with more posterior placement of the proximal tunnel relative to the supinator crest. An increase in degree of perpendicularity of graft to ulnar tunnels was noted with posterior shifts in proximal tunnel location.

Posterior placement of the proximal ulna tunnel allows for a larger bony bridge and a more geometrically favorable reconstruction.

Posterolateral rotatory instability (PLRI) of the elbow is well recognized¹ and is the most common type of chronic elbow instability. PLRI is often an end result of traumatic elbow dislocation.² The “essential lesion” in patients with PLRI of the elbow is injury to the lateral ulnar collateral ligament (LUCL).¹ However, more recent research has emphasized the importance of other ligaments in the lateral ligament complex (radial collateral and annular ligaments) in preventing PLRI.³⁻⁵ Nevertheless, when conservative treatment fails, the most commonly used surgical treatment involves LUCL reconstruction.^{1,6-11}

Numerous techniques for LUCL reconstruction have been described.^{1,7-9,11-13} The chosen technique ideally restores normal anatomy. Therefore, the isometric point of origin at the lateral epicondyle and insertion at the supinator tubercle are important landmarks for creating tunnels that reproduce isometry, function, and normal anatomy. Most often, 2 tunnels are created in the ulna to secure the graft. It has been our experience that ulnar tunnel creation can affect the length of the bony bridge and the orientation of the graft.

We conducted a study to identify the precise proximal ulna tunnel location—anterior to posterior, with the distal tunnel at the supinator tubercle on the crest—that allows for the largest bony bridge and most geometrically favorable construct. We hypothesized that a most posteriorly placed proximal tunnel would increase bony bridge size and allow for a more isosceles graft configuration. An isosceles configuration with the humerus tunnel at the isometric location would allow for anterior and posterior bands of the same length with theoretically equal force distribution.

Methods

After obtaining institutional review board approval, we retrospectively reviewed the cases of 17 adults with elbow computed tomography (CT) scans for inclusion in this study. The scans were previously performed for diagnostic workup of several pathologies, including valgus instability, olecranon stress fracture, and valgus extension overload. The scan protocol involved 0.5-mm axial cuts with inclusion of the distal humerus through the proximal radius and ulna in the DICOM (Digital Imaging and Communications in Medicine) format. Exclusion criteria included poor CT quality, inadequate visualization of the entire supinator crest, and age under 18 years. Fifteen patients with adequate CT scans met the inclusion criteria. MIMICS (Materialise’s Interactive Medical Image Control System) software was used to convert scans into patient-specific 3-dimensional (3-D) computer models. (Use of this software to produce anatomically accurate models has been verified in shoulder¹⁴ and elbow¹⁵ models.) These models were uploaded into Magics rapid prototyping software (Materialise) and manipulated for simulated tunnel drilling by precise bone subtraction methods. This software was used to define an ulnar

Authors’ Disclosure Statement: The authors report no actual or potential conflict of interest in relation to this article.

Cartesian coordinate system with anatomical landmarks as reference points in order to standardize the position of each model (Figure 1).¹⁶ The y-axis was defined by the longitudinal axis of the ulna, and the x-axis was the transepicondylar axis, defined as the perpendicular line connecting the y-axis with the supinator crest. The z-axis was then established as the line

perpendicular to the x- and y-axes—yielding a 3-D coordinate system that allowed us to manipulate the models in standardized fashion, maintaining the exact positions of the ulna while making measurements.

Surgical simulations were performed in the rapid prototyping software by creating a cylinder and placing it at the desired location of each tunnel. Cylinder diameter was 4 mm, matching the diameter of the drill we use to create each tunnel in our practice. The cylinder was inserted into the bone, perpendicular to the surface of the ulna at the point of insertion, so the cylinder's deepest point entered the medullary canal of the ulna. Using a Boolean operation in the rapid prototyping software, we subtracted cylinder from bone to create a tunnel (Figure 2).¹⁵

In a previous study,¹⁷ we determined that the radial head junction is reproducibly about 15 mm proximal to the distinct supinator tubercle, which may be absent or not readily appreciated in up to 50% of cases. Therefore, proximal ulnar tunnels were placed 0, 5, and 10 mm posterior to the supinator crest at the radial head junction. Distal tunnels were placed 15 mm anterior to the radial head junction on the supinator crest (Figure 2). The bony bridges created by these tunnels were measured, as was the distance between the distal tunnel and the supinator tubercle.

as was the distance between the distal tunnel and the supinator tubercle.

Ideal graft configuration was described as an isosceles triangle with ulna tunnels perpendicular to the humeral tunnel (Figure 3).¹¹ Location of the humeral origin in the sagittal plane was determined by finding the isometric point of the lateral humerus using only bony landmarks. Similar techniques have been used to

find the isometric point on the medial epicondyle for medial ulnar collateral ligament reconstruction.^{15,18} With a circle fit into the trochlear notch of the ulna, the isometric point can be determined by the center of the circle. This point was then superimposed on the humerus to identify the starting point (Figure 4). In our simulation, we measured the isosceles configuration by drawing a line between the proximal and distal tunnels, and then another line connecting the bisecting point of the first line with the isometric point on the humerus from which the graft would originate. The angle between the 2 lines was measured; if isosceles, the angle was 90° (Figure 5). Length of the more proximal limb of the graft and the more distal limb of the graft was determined by measuring the distance from the isometric point to the proximal and distal tunnels, respectively (Figure 6).

One-way analysis of variance was used to compare all the tunnels' bony bridge sizes, graft lengths, and angles to the isometric point. For all comparisons, statistical significance was set at $P < .05$. As no other studies have compared bony bridges by varying tunnel creation parameters, and as the

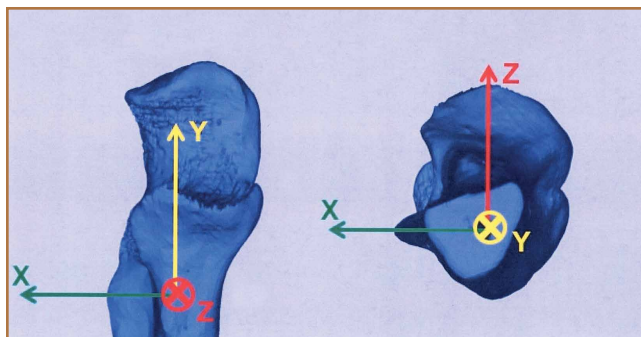


Figure 1. Ulnar computed tomography simulation model. Y axis is longitudinal; X axis is transepicondylar; Z axis is perpendicular to Y and X and is used to create 3-dimensional model.

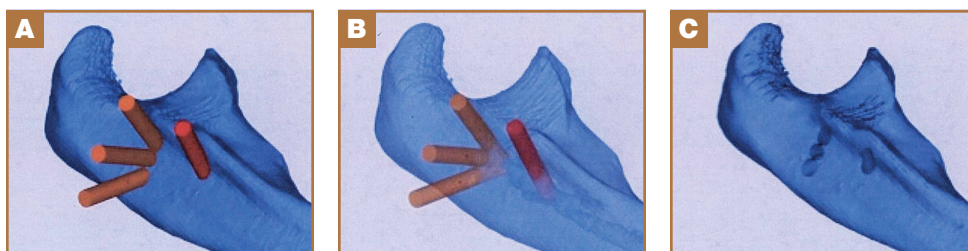

Figure 2. Bone subtraction software creation of ulnar tunnels at radial head junction. (A) Ulna tunnel drill simulation, (B) representation of bony subtraction, and (C) ulna after simulated ulna tunnel drilling.

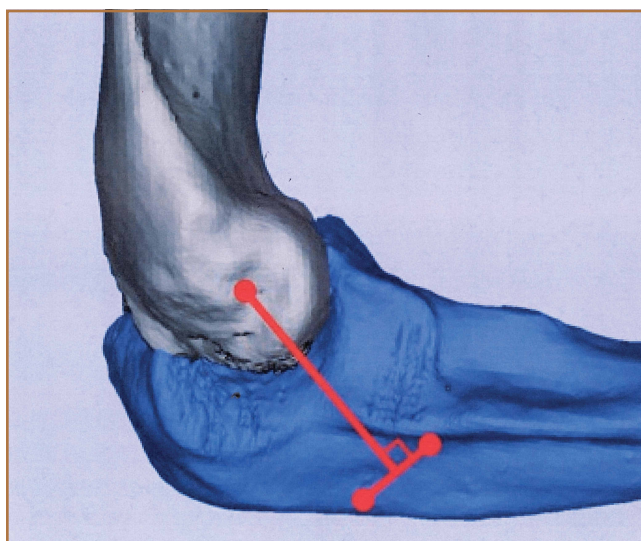


Figure 3. Creation of tunnels to form isosceles configuration of resultant graft.

present study is observational and not comparative, no power analysis was performed.

Results

Bony bridges were significantly longer, and angles more perpendicular, with increasing distance from the proximal tunnel to the supinator crest (Table 1, Figure 5, Figure 7). The bony bridge 0 mm posterior to the supinator crest yielded a mean (SE) bony bridge length of 11.0 (0.2) mm. This proximal tunnel also yielded the smallest mean (SE) perpendicular angle to the isometric point, 131.2° (1.9°). The tunnel most posterior to the supinator crest yielded the longest mean (SE) bony bridge, 13.7 (0.2) mm, and the largest mean (SE) degree of perpendicularity, 95.8° (1.4°). The differences between all tunnels’

bony bridges and isometric angles were statistically significant ($P < .00001$). The difference between the more distal limb and the more proximal limb of the graft was smallest in the more posteriorly placed proximal tunnel (Table 2, Figure 8). In fact, there was no statistical difference between the proximal and distal limbs of the graft when the proximal tunnel was placed 10 mm posterior to the supinator crest: Mean (SE) was 9.4 (0.5) mm at 0 mm ($P < .00001$) and 1.1 (0.6) mm at 10 mm ($P = .24$).

Discussion

PLRI of the elbow is best initially managed nonoperatively. However, when nonoperative management fails, the LUCL is often surgically reconstructed. Reconstruction methods vary by fixation method, graft choice, and bone tunnels.^{1,7-9,11-13} In 1991, O’Driscoll and colleagues¹ described a “yoke” technique for LUCL reconstruction. Since then, the docking technique⁷ and other techniques have been developed. All these techniques emphasize maximizing anatomical precision and isometry with careful placement of tunnels or fixa-

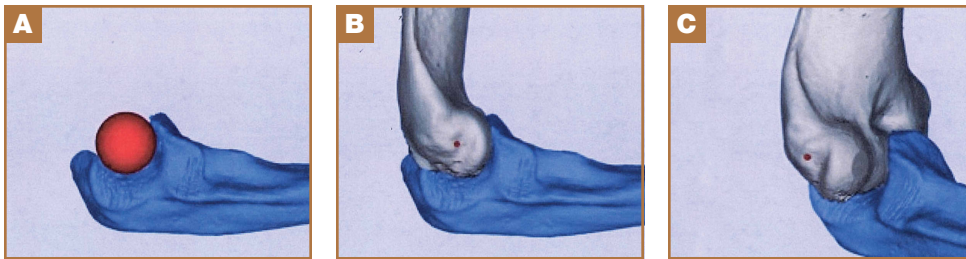

Figure 4. (A-C) Creation of humeral tunnel location at center of rotation and point of isometry.

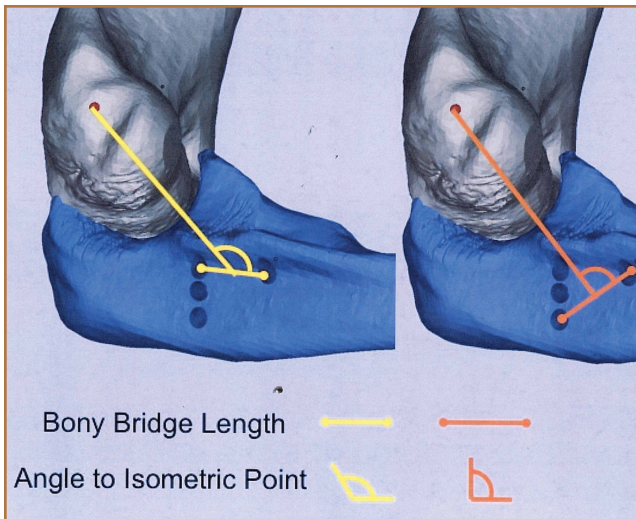


Figure 5. Simulation shows calculation of ulnar tunnel angles. More posterior ulna tunnel produces most isosceles construct.

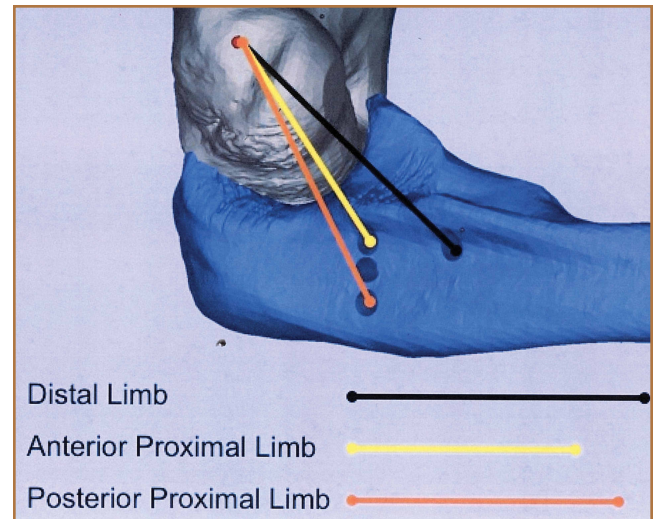


Figure 6. Simulation shows measurement of graft lengths. More posterior ulna tunnel produces most isosceles construct.

Table 1. Bony Bridge and Angle to Isometric Point Formed by 3 Different Proximal Tunnels

	Distance Posterior to Supinator Crest, mm		
	0	5	10
Mean (SE) bony bridge, mm	11.0 (0.2)	11.6 (0.2)	13.7 (0.2)
Mean (SE) angle, °	131.2 (1.9)	112.6 (1.3)	95.8 (1.4)

tion devices. The humeral fixation site, at the anterior inferior aspect of the lateral epicondyle at the point of isometry, can be accessed relatively reproducibly. By contrast, the ulnar points of fixation are more variable, because of increased bone stock and overlying soft-tissue and bony anatomy.

Among the challenges in determining the points of ulnar fixation is the bony anatomy that is often used for landmarks. In the literature, the supinator crest or the supinator tubercle is the landmark for placing the distal tunnel.^{1,7-9,11-13} This is a problem for 2 reasons. First, the supinator crest, a longitudinal structure on the lateral aspect of the ulna, originates from the radial head junction and extends tens of millimeters distally; further specification is needed to guide these ulnar tunnels. The second reason is that use of the supinator tubercle, a prominence on the supinator crest, adds specificity to the location of the ulnar tunnels. During surgery, however, the supinator tubercle may not be a reliable, independently prominent structure; instead, it may be indistinguishable from the supinator crest, on which it rests. One study determined that only about 50% of computer models of patient ulnas had a distinct prominence that could be classified as the supinator tubercle.¹⁷ The percentage presumably is lower during surgery, with limited exposure and overlying soft tissues.

In a study of patients with a prominent tubercle, mean (SE) distance from radial head junction to tubercle was 15 (2) mm.¹⁷ This finding led us to use the radial head junction as the primary bony landmark in determining the location of

the proximal tunnel and placing the distal tunnel 15 mm distally—achieving the same fixation described in the literature but using more distinct landmarks. Our study thus provided a reliable, verified approach to locating the ulnar tunnels in the proximal-distal axis.

We also explored the anterior-posterior orientation of the proximal ulnar tunnel. The 2 primary considerations surrounding the varied proximal tunnel placements were the bony bridge formed between the proximal and distal tunnels and the perpendicularity of the triangle formed by the fixation points. Maximizing the bony bridge is obviously ideal in securing and preventing fixation blowout. Achieving an isocles reconstruction has been reported in the literature on the various fixation techniques for LUCL reconstruction.¹¹ Although the biomechanical advantage of this fixation type is not fully clear, we assume the construct produces graft stands of equal length, tension, and stability. In addition, the larger footprint created by an isocles reconstructed ligament increases the stability of the radial head.

Results of the present study showed that the more posterior the proximal ulnar tunnel, the longer the bony bridge and the more isocles the reconstruction. The difference in bony bridge distance from the most anterior to the most posterior tunnel was about 2 mm, or 18%. For every 1 mm of posteriorization, the bony bridge was 0.2 mm longer. The line from the isometric point of humeral fixation bisecting the proximal and distal tunnels was also more perpendicular with the most posterior

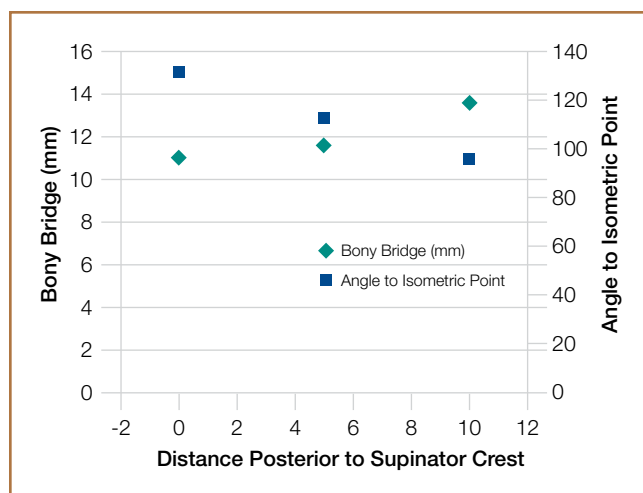


Figure 7. Changes in bony bridge and tunnel angles depend on placement of ulna tunnels.

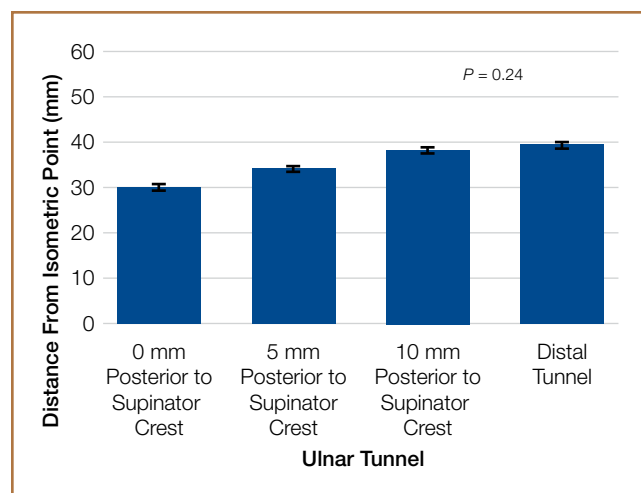


Figure 8. Changes in graft lengths depend on placement of ulna tunnels.

Table 2. Graft Lengths and Difference Between Graft Lengths Formed by 3 Different Proximal Tunnels

	Proximal Tunnel, mm Posterior			Distal Tunnel
	0	5	10	
Mean (SE) length of graft limb from isometric point, mm	30.0 (0.6)	34.1 (0.6)	38.3 (0.6)	39.4 (0.7)
Mean (SE) difference between proximal and distal graft limb, mm	9.4 (0.5)	5.2 (0.5)	1.1 (0.6)	—

tunnel, by about 40°. The resulting proximal and distal limbs of the reconstruction were equal in length, as demonstrated by the smaller difference between the limbs. We assume this isocetes reconstruction more likely applies uniform restraint on the radial head. Thus, an effort should be made to posteriorize the proximal ulnar tunnel during reconstruction.

The study was limited by the number of patient-specific elbow models used. However, given the statistical consistency of measurements, sample size was sufficient. Another limitation, inherent to the model, was that only bony anatomy was incorporated. However, the overlying muscles, tendons, and ligaments can significantly alter tunnel placement, and this study provided other means and cues using more reliable landmarks to adequately place the tunnels. As this was a simulation study, we cannot confirm whether these results would make a difference clinically. The strengths of this study include development and verification of reliable landmarks that can be used to guide ulnar tunnel locations during LUCL reconstruction; these landmarks have been used for medial ulnar collateral ligament reconstruction.¹⁵ Other strengths include precise and accurate placement of tunnels and measurement of resulting bony bridges—accomplished independently and without compromising specimen quality.

Conclusion

We recommend drilling the proximal ulnar tunnel posterior to the supinator crest at the level of the radial head junction. A reasonable goal is 10 mm posterior to the crest, though the overlying soft tissue must be considered, and care should be taken to aim the drill anteriorly, toward the ulna's intramedullary canal, to avoid posterior cortical breach. The distal ulnar tunnel should be drilled just posterior to the supinator crest, 15 mm distal to the radial head junction.

.....

Dr. Anakwenze is Orthopedic Surgeon, Olympus Orthopedics, San Diego, California. Dr. Khanna is Orthopaedic Surgery Resident, Department of Orthopaedic Surgery, University of California San Francisco Medical Center, San Francisco, California. Dr. Levine and Dr. Ahmad are Orthopaedic Surgeons, Department of Orthopaedic Surgery, Columbia Presbyterian Hospital, New York, New York.

Address correspondence to: Oke A. Anakwenze, MD, Olympus Orthopedics, 3750 Convoy St., Suite 201, San Diego, CA 92111 (email, oaa@olympusortho.com).

Am J Orthop. 2016;45(2):53-57. Copyright Frontline Medical Communications Inc. 2016. All rights reserved.

References

- O'Driscoll SW, Bell DF, Morrey BF. Posterolateral rotatory instability of the elbow. *J Bone Joint Surg Am.* 1991;73(3):440-446.
- O'Driscoll SW. Classification and evaluation of recurrent instability of the elbow. *Clin Orthop Relat Res.* 2000;370:34-43.
- Takigawa N, Ryu J, Kish VL, Kinoshita M, Abe M. Functional anatomy of the lateral collateral ligament complex of the elbow: morphology and strain. *J Hand Surg Br.* 2005;30(2):143-147.
- McAdams TR, Masters GW, Srivastava S. The effect of arthroscopic sectioning of the lateral ligament complex of the elbow on posterolateral rotatory stability. *J Shoulder Elbow Surg.* 2005;14(3):298-301.
- Dunning CE, Zarzour ZD, Patterson SD, Johnson JA, King GJ. Ligamentous stabilizers against posterolateral rotatory instability of the elbow. *J Bone Joint Surg Am.* 2001;83(12):1823-1828.
- Eyendaal D. Ligamentous reconstruction around the elbow using triceps tendon. *Acta Orthop Scand.* 2004;75(5):516-523.
- Jones KJ, Dodson CC, Osbahr DC, et al. The docking technique for lateral ulnar collateral ligament reconstruction: surgical technique and clinical outcomes. *J Shoulder Elbow Surg.* 2012;21(3):389-395.
- Lee BP, Teo LH. Surgical reconstruction for posterolateral rotatory instability of the elbow. *J Shoulder Elbow Surg.* 2003;12(5):476-479.
- Lin KY, Shen PH, Lee CH, Pan RY, Lin LC, Shen HC. Functional outcomes of surgical reconstruction for posterolateral rotatory instability of the elbow. *Injury.* 2012;43(10):1657-1661.
- Olsen BS, Sejbjerg JO. The treatment of recurrent posterolateral instability of the elbow. *J Bone Joint Surg Br.* 2003;85(3):342-346.
- Sanchez-Sotelo J, Morrey BF, O'Driscoll SW. Ligamentous repair and reconstruction for posterolateral rotatory instability of the elbow. *J Bone Joint Surg Br.* 2005;87(1):54-61.
- Savoie FH 3rd, Field LD, Gurley DJ. Arthroscopic and open radial ulnohumeral ligament reconstruction for posterolateral rotatory instability of the elbow. *Hand Clin.* 2009;25(3):323-329.
- Savoie FH 3rd, O'Brien MJ, Field LD, Gurley DJ. Arthroscopic and open radial ulnohumeral ligament reconstruction for posterolateral rotatory instability of the elbow. *Clin Sports Med.* 2010;29(4):611-618.
- Bryce CD, Pennypacker JL, Kulkarni N, et al. Validation of three-dimensional models of in situ scapulae. *J Shoulder Elbow Surg.* 2008;17(5):825-832.
- Byram IR, Khanna K, Gardner TR, Ahmad CS. Characterizing bone tunnel placement in medial ulnar collateral ligament reconstruction using patient-specific 3-dimensional computed tomography modeling. *Am J Sports Med.* 2013;41(4):894-902.
- Shiba R, Sorbie C, Siu DW, Bryant JT, Cooke TD, Wevers HW. Geometry of the humeroulnar joint. *J Orthop Res.* 1988;6(6):897-906.
- Anakwenze OA, Khanna K, Levine WN, Ahmad CS. Characterization of the supinator tubercle for lateral ulnar collateral ligament reconstruction. *Orthop J Sports Med.* 2014;2(4):2325967114530969. doi:10.1177/2325967114530969.
- Sasashige Y, Ochi M, Ikuta Y. Optimal attachment site for reconstruction of the ulnar collateral ligament. A cadaver study. *Arch Orthop Trauma Surg.* 1994;113(5):265-270.