

Strangulation of Radial Nerve Within Nondisplaced Fracture Component of Humeral Shaft Fracture

Mark R. Adams, MD, John S. Hwang, MD, Mark C. Reilly, MD, and Michael S. Sirkin, MD

Abstract

Rates of radial nerve injury, which is commonly associated with humeral shaft fractures, range from 8% to 12%. This neurapraxia typically recovers with non-operative management. In some conservatively treated cases, the radial nerve is lacerated or entrapped. Patients with a lacerated or entrapped nerve may have better outcomes with early operative management.

We report on a rare case of the radial nerve entrapped within a nondisplaced segment of a closed humeral shaft fracture and describe the clinical outcome of early operative management.

A radial nerve injury in association with a humeral shaft fracture is not an infrequent occurrence.^{1,2} The nerve injury typically is thought to be a neurapraxia caused by a contusion, as spontaneous recovery rates range from 70% to 90%.²⁻⁴ In cases in which acute nerve exploration and open reduction and internal fixation (ORIF) are not indicated, patient and clinician wait months for the nerve to recover. In some conservatively treated cases, the nerve is lacerated or entrapped. Patients with a lacerated or entrapped nerve may have better outcomes with early operative management.

We report on a rare case of the radial nerve entrapped within a nondisplaced segment of a closed humeral shaft fracture and describe the clinical outcome of early operative management. The patient provided written informed consent for print and electronic publication of this case report.

Case Report

An intoxicated, restrained 18-year-old driver in a motor vehicle collision sustained multiple injuries, including rib fracture, apical pneumothorax with pulmonary contusion, and corneal abrasion. Orthopedic injuries included right subtrochanteric femur fracture and midshaft right humeral shaft fracture (**Figure 1**).

Initial orthopedic evaluation of the right arm revealed decreased sensation in the radial nerve distribution. Motor function in the radial nerve was absent; the patient was incapable of active wrist extension or finger extension. Median and ulnar nerves were motor- and sensory-intact. Radiographs showed a displaced transverse midshaft humeral shaft fracture with a minimally displaced vertical fracture line extending from the fracture site about 3 cm into the proximal segment. The patient was placed in a coaptation splint. The femur fracture was treated with an antegrade piriformis entry intramedullary nail.

ORIF of the humerus was performed to facilitate mobilization of this polytrauma patient. He was positioned prone on a flat-top table with his right arm over a radiolucent extension. The arm was abducted at the shoulder and the elbow flexed. A posterior midline skin incision was made to reflect the triceps in a lateral-to-medial direction, facilitating dissection of

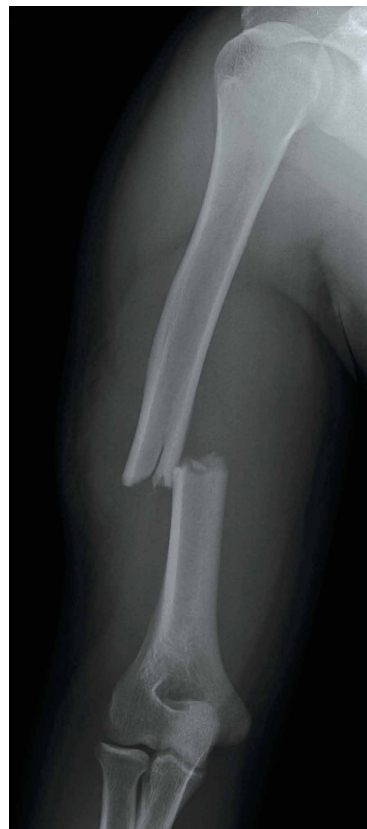

Figure 1. Anteroposterior plain radiograph of right humerus shows midshaft humerus fracture.

Authors' Disclosure Statement: The authors report no actual or potential conflict of interest in relation to this article.

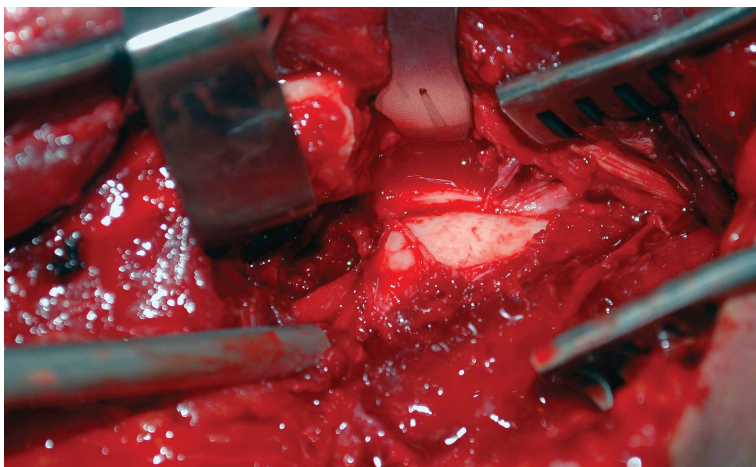


Figure 2. Intraoperative image shows radial nerve entrapped within nondisplaced fracture fragment.

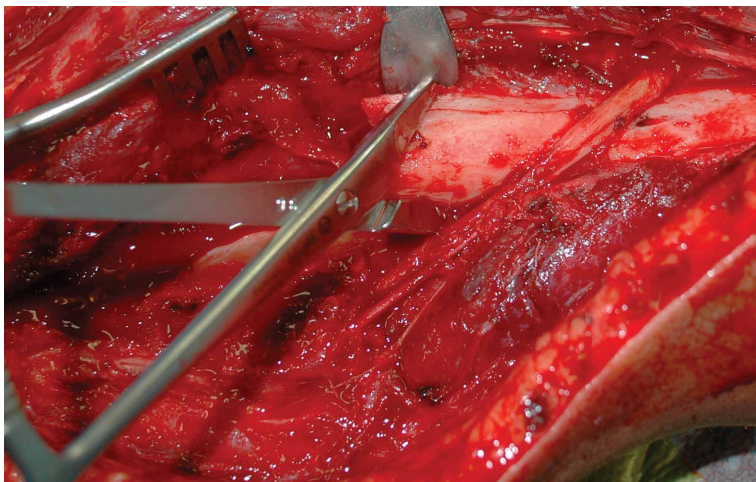


Figure 3. Intraoperative image shows previously entrapped radial nerve free from nondisplaced fracture.

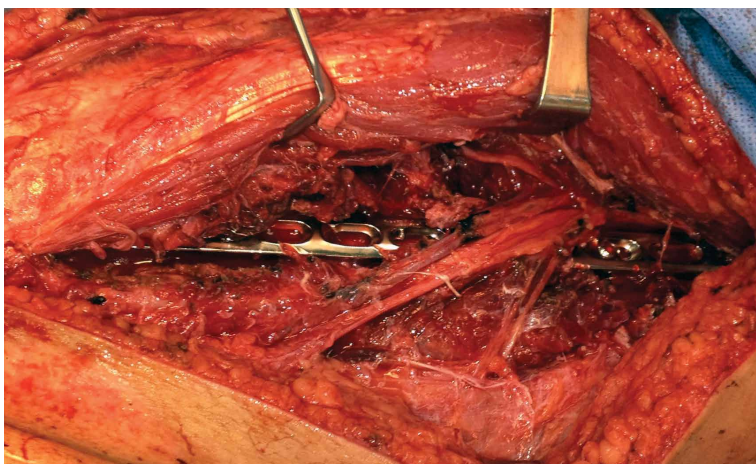


Figure 4. Intraoperative image shows open reduction and internal fixation of humerus fracture with radial nerve over plate.

the lateral brachial cutaneous nerve on the lateral aspect of the triceps, with resultant localization of the radial nerve. At that time, the radial nerve was noted to be entrapped in the fracture site

(**Figure 2**). In the proximal segment was a sagittal split, displaced about 1 mm, and it was in this interval the nerve was held. This sagittal fracture appeared incomplete as it was followed more proximally. A unicortical Kirschner wire was placed in a posterior-to-anterior direction in each fragment alongside the nerve. A lamina spreader engaged the wires and distracted the fracture site as the tines were spread apart, releasing the nerve (**Figure 3**). The nerve was in continuity but was severely contused at that location. After the sagittal split was reduced, two 2.7-mm lag screws were used in lag fashion, and the transverse midshaft component was fixed with a 10-hole, 4.5-mm narrow locking compression plate. The radial nerve lay on the posterior aspect of the plate, between holes 4 and 5 (**Figures 4, 5**). The wound was closed, and the patient was made weight-bearing as tolerated in the right upper extremity. He was sent to occupational therapy, and static and dynamic splints were made for his wrist and hand.

Two months after injury, radial nerve examination findings were unchanged: decreased sensation on dorsum of hand and no motor function. At 3 months, electrodiagnostic testing showed neurophysiologic evidence of severe right radial neuropathy proximal to the innervation of the right brachioradialis. There were electrodiagnostic signs of ongoing axonal loss and no signs of ongoing reinnervation. At 4 months, only motor strength in wrist extension was improved (2/5). At 5 months, the patient had 4-/5 wrist extension, 3/5 metacarpophalangeal (MCP) extension of fingers, and 0/5 MCP/interphalangeal extension of thumb. Sensation in the radial nerve distribution was still decreased. At 7 months, strength in wrist extension and finger MCP extension was 4+/5. The fracture was now well healed, with maintained alignment and no changes in hardware appearance.

Discussion

In most cases, closed treatment of a humeral shaft fracture with an associated radial nerve injury has a successful outcome.⁵The etiology of the neurapraxia likely is nerve contusion after the fracture. A neurapraxia is by definition a temporary injury to the myelin sheath with an intact nerve; the nerve function recovers rapidly.

Some humeral shaft fractures, however, have

been associated with radial nerve injuries more severe than contusions, resulting in axonotmesis or neurotmesis. These more severe injuries make up 10% to 30% of humeral shaft fractures, including those with a frank laceration of the nerve and those with an entrapped nerve.^{2,3} Shao and colleagues² reported a 90% recovery rate for patients who delayed extrication of the entrapped radial nerve. Although there is no consensus on timing of surgical exploration, motor and sensory function of the nerve is temporally related, which may indicate that earlier diagnosis and treatment lead to improved outcome.^{6,7} Loss of radial nerve function can have devastating effects on upper extremity function. Often, patients lose all or some extension of the wrist and fingers and abduction and extension of the thumb.

In a standard history or physical examination, there are no particular features indicating nerve entrapment. Absolute indications for humeral shaft fractures with radial palsy are limited to open fractures, vascular injuries, and unacceptable fracture alignment. Relative indications are polytrauma and secondary palsy after attempted fracture reduction.

For all other humeral shaft fractures with radial nerve palsy, observation is still the mainstay of treatment, with spontaneous recovery occurring in up to 90% of patients.^{2,8-12} Our patient did not have an absolute indication for operative treatment; surgery was nevertheless performed to address the polytrauma and to facilitate earlier mobilization.

Electromyogram (EMG) studies typically are not useful after acute injury. EMG studies are better used serially to evaluate reinnervation after the acute phase. Bodner and colleagues^{13,14} used ultrasonography to identify the radial nerve in a patient with unimproved radial nerve palsy 6 weeks after humeral shaft fracture. They found the nerve within the fracture site, whereas magnetic resonance imaging (MRI) could not follow its course.

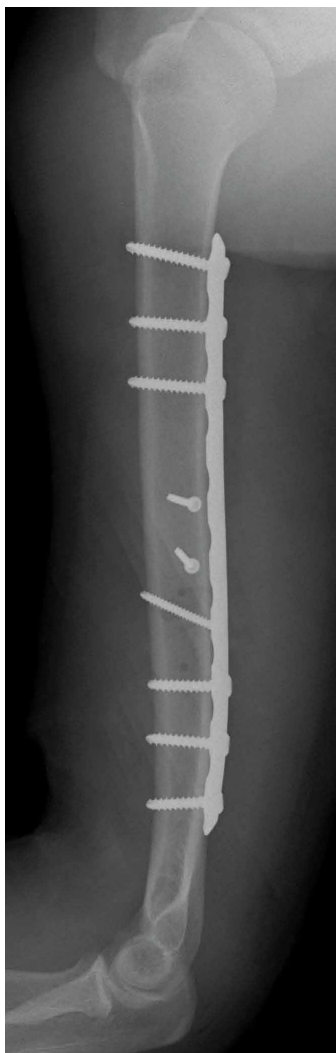


Figure 5. Lateral plain radiograph of right humerus shows plate-and-screw fixation of right humerus fracture.

Neither ultrasonography nor MRI would likely be used after acute injury. More research is needed to improve evaluation of patients with continued palsy after nonoperative treatment.

In the case of our patient's humeral shaft fracture, surgery was performed early because of polytrauma and radial nerve entrapment. If left interposed between 2 fracture fragments, the nerve would have been subjected to continued ischemia and likely would not have recovered spontaneously. Ikeda and Osamura⁷ reported on a case of radial nerve palsy that occurred after humerus shaft fracture. The nerve, entrapped between fracture fragments, was explored later, after function failed to return. As it was found within callus, the nerve was cut and then repaired end-to-end. In our patient's case, early exploration led to release of the radial nerve from the fracture site—preventing irreversible nerve damage and allowing for spontaneous recovery over subsequent months.

Surgery for polytrauma patients with a humeral shaft fracture and radial nerve palsy may also be beneficial with respect to early nerve exploration and early mobilization. Although

our patient's fracture was well aligned and as an isolated injury would not have required surgery, the polytrauma called for early surgical management, which revealed radial nerve entrapment and led to early recovery of nerve function.

Dr. Adams is Assistant Professor, Division of Trauma, Department of Orthopaedics; Dr. Hwang is an Orthopaedic Resident, Department of Orthopaedics; Dr. Reilly is Associate Professor, Division of Trauma, Department of Orthopaedics; and Dr. Sirkin is Vice Chair and Professor, New Jersey Medical School, Rutgers, the State University of New Jersey, Newark, New Jersey.

Address correspondence to: John S. Hwang, MD, Department of Orthopaedics, New Jersey Medical School, Rutgers, the State University of New Jersey, Newark, NJ 07103 (tel, 973-972-0763; email, hwangjo@rutgers.njms.edu).

Am J Orthop. 2016;45(4):E217-E220. Copyright Frontline Medical Communications Inc. 2016. All rights reserved.

References

- Ekholm R, Adami J, Tidermark J, Hansson K, Törnkvist H, Ponzer S. Fractures of the shaft of the humerus. An epidemiological study of 401 fractures. *J Bone Joint Surg Br.* 2006;88(11):1469-1473.
- Shao YC, Harwood P, Grotz MR, Limb D, Giannoudis PV. Radial nerve palsy associated with fractures of the shaft of the humerus: a systematic review. *J Bone Joint Surg Br.* 2005;87(12):1647-1652.
- Shah JJ, Bhatti NA. Radial nerve paralysis associated with fractures of the humerus. A review of 62 cases. *Clin Orthop Relat Res.* 1983;(172):171-176.
- Ring D, Chin K, Jupiter JB. Radial nerve palsy associated with high-energy humeral shaft fractures. *J Hand Surg.* 2004;29(1):144-147.
- Sarmiento A, Zagorski JB, Zych GA, Latta LL, Capps CA. Functional bracing for the treatment of fractures of the humeral diaphysis. *J Bone Joint Surg Am.* 2000;82(4):478-486.
- Hugon S, Daubresse F, Depierreux L. Radial nerve entrapment in a humeral fracture callus. *Acta Orthop Belg.* 2008;74(1):118-121.
- Ikeda K, Osamura N. The radial nerve palsy caused by embedding in the humeral shaft fracture—a case report. *Hand Surg.* 2014;19(1):91-93.
- Green DP, Hotchkiss RN, Pederson WC, Wolfe SW, eds. *Green's Operative Hand Surgery.* 2 vols. 5th ed. Philadelphia, PA: Elsevier/Churchill Livingstone; 2005.
- Kettelkamp DB, Alexander H. Clinical review of radial nerve injury. *J Trauma.* 1967;7(3):424-432.
- Pollock FH, Drake D, Bovill EG, Day L, Trafton PG. Treatment of radial neuropathy associated with fractures of the humerus. *J Bone Joint Surg Am.* 1981;63(2):239-243.
- Li Y, Ning G, Wu Q, Wu Q, Li Y, Feng S. Review of literature of radial nerve injuries associated with humeral fractures—an integrated management strategy. *PLoS One.* 2013;8(11):e78576.
- DeFranco MJ, Lawton JN. Radial nerve injuries associated with humeral fractures. *J Hand Surg.* 2006;31(4):655-663.
- Bodner G, Huber B, Schwabegger A, Lutz M, Waldenberger P. Sonographic detection of radial nerve entrapment within a humerus fracture. *J Ultrasound Med.* 1999;18(10):703-706.
- Bodner G, Buchberger W, Schocke M, et al. Radial nerve palsy associated with humeral shaft fracture: evaluation with US—initial experience. *Radiology.* 2001;219(3):811-816.