

[Edit Article](#)

Antegrade Femoral Nail Distal Interlocking Screw Causing Rupture of the Medial Patellofemoral Ligament and Patellar Instability

Publish date: July 11, 2018

Authors:

Gregory L. Cvetanovich, MD Gift Ukwuani, MD Benjamin Kuhns, MD Alexander E. Weber, MD Edward Beck, MPH
Shane J. Nho, MD, MS

Author Affiliation | **Disclosures**

Authors' Disclosure Statement: Dr. Nho reports that he is on the editorial board of *The American Journal of Orthopedics*; is a board or committee member of the American Orthopaedic Society for Sports Medicine and the Arthroscopy Association of North America; receives research support from Allosource, Arthrex, Athletico, DJ Orthopaedics, Linvatec, Miomed, Smith & Nephew, and Stryker; is a paid consultant to Össur and Stryker; and receives publishing royalties and financial or material support from Springer. The other authors report no actual or potential conflict of interest in relation to this article.

Dr. Cvetanovich, Dr. Kuhns, and Dr. Weber are Residents; Dr. Ukwuani and Mr. Beck are Research Coordinators; and Dr. Nho is an Orthopedic Surgeon, Hip Preservation Center, Division of Sports Medicine, Department of Orthopedic Surgery, Rush Medical College of Rush University, Rush University Medical Center, Chicago, Illinois.

Address correspondence to: Shane J. Nho, MD, MS, Hip Preservation Center, Division of Sports Medicine, Department of Orthopedic Surgery, Rush University Medical Center, 1611 W. Harrison Street, Suite 300, Chicago, IL 60612 (tel, 872-888-4538; fax, 708-309-5179; email, nho.research@rushortho.com).

Am J Orthop. 2018;47(7). Copyright Frontline Medical Communications Inc. 2018. All rights reserved.

Take-Home Points

- Anterograde intramedullary nailing is the gold standard for fixation of diaphyseal femur fractures.
- Damage to the MPFL can be caused by the distal interlocking screw of an anterograde intramedullary nail.
- The trajectory of the distal interlocking screw from posterolateral to anteromedial, and a prominent screw tip, likely contributed to the injury to the MPFL observed in this case.
- Surgeons treating these conditions should pursue advanced imaging if patients present with effusion and patellar instability after femoral intramedullary nail placement.
- Distal interlocking screw removal and arthroscopic MPFL reconstruction can result in successful return of function and normal activities.

Reamed intramedullary nails are the gold standard for fixation of femoral diaphyseal fractures.¹ Antegrade or retrograde nails are effective options, with the choice of technique based on factors including surgeon preference, patient factors, and concomitant injuries.² Interlocking screws are generally placed to allow control of both rotation and length.¹ Advantages of intramedullary treatment of femoral diaphyseal fractures compared with plate fixation include low rates of infection, lower nonunion rate, and faster patient mobilization and weight-bearing.³

Complications of antegrade intramedullary fixation of femoral shaft fractures include infection, nonunion, malunion, anterior cortical perforation, heterotopic ossification, abductor weakness, and soft tissue irritation from interlocking screws.²⁻⁴ Femoral intramedullary nails are not routinely removed because the hardware is rarely symptomatic and removing the nail involves additional surgical morbidity with the potential for complications.⁵ Interlocking screws are removed in select cases due to soft tissue irritation, generally after fracture union. Although hardware removal may help in select cases, removal of intramedullary nails is associated with low rates of symptom resolution.⁶⁻⁸

We present a case of iatrogenic medial patellofemoral ligament (MPFL) disruption by the distal interlocking screw leading to patellar instability, a previously unrecognized complication of antegrade femoral nailing for femoral diaphyseal fractures. The patient provided written informed consent for print and electronic publication of this case report.

Case Report

We present a case of a 23-year-old man whose status was 2 years post antegrade reamed femoral intramedullary nailing at an outside institution for a right diaphyseal femur fracture. This issue was revised for external rotational malalignment, and he presented with right anterior knee pain, recurrent patellar subluxation, and recurrent effusions. The extent of external rotational malalignment and subsequent rotational correction were not evident from the available outside institution records. These symptoms began after his femoral nail revision for malalignment, and he had no subsequent trauma. The femoral fracture healed uneventfully. The patient denied any history of knee pain, swelling, or patellar instability before his femoral nail revision for malalignment. These episodes of effusion, instability, and pain occurred several times per year, generally with activities of daily living (ADL). On one occasion, he presented to a local emergency room where knee aspiration revealed no evidence of crystals or infection. The patient was referred to the senior author (Dr. Nho) for consultation.

Physical examination revealed right knee full extension with flexion to 80°. A moderate right knee effusion was present. The patient was tender over the medial femoral epicondyle and the superomedial aspect of the patella without joint line tenderness. Lateral patellar instability was present with 2 quadrants of translation (compared with 1 on the contralateral side) and patellar apprehension. The patient's knee was ligamentously stable, and meniscal signs were absent. His lower extremity rotational profile was symmetric to the contralateral uninjured side.

Right femur and knee X-rays showed an antegrade intramedullary nail with a well-healed diaphyseal fracture and a single distal interlocking screw oriented from posterolateral to anteromedial (**Figures 1A-1G**). The screw tip was prominent on sunrise X-ray view anterior to the medial femoral epicondyle (**Figure 1C**). Magnetic resonance imaging demonstrated a large effusion and lateral patellar subluxation with a prominent intra-articular distal interlocking screw disrupting the MPFL near the femoral attachment (**Figure 2**). Patellar height, trochlear morphology, and tibial tubercle-trochlear groove distance were assessed and found to be normal.

The patient elected to have a right knee arthroscopic-assisted MPFL reconstruction and removal of the distal interlocking screw. Diagnostic arthroscopy revealed the distal interlocking screw to be intra-articular medially, prominent by 3 mm causing attritional disruption of the mid-substance MPFL (**Figure 3A**). The patella was noted to be subluxated and tracking laterally (**Figure 3B**). Both the anterior cruciate ligament and posterior cruciate ligament were intact, and menisci and articular cartilage were normal. The distal interlocking screw was removed under fluoroscopic guidance through a small lateral incision (**Figure 3C**).

Due to the nature of the longstanding attritional disruption of the MPFL in this case with associated patellar instability over a 2-year period, the decision was made to proceed with formal MPFL reconstruction as opposed to repair. A 2-cm incision was made at the medial aspect of the patella. The proximal half of the patella was decorticated. Guide pins were placed within the proximal half of the patella, ensuring at least a 1-cm bone bridge between them, and two 4.75-mm SwiveLock suture anchors (Arthrex) were inserted. A semitendinosus graft was used for MPFL reconstruction with the 2 ends of the graft secured to 2 suture anchors with a whipstitch. Lateral fluoroscopy was used to identify Schöttle's point, denoting the femoral origin of the MPFL⁹ (**Figure 3D**). A 2-cm incision was made at this location. A guide pin was then placed at Schöttle's point under fluoroscopic guidance, aimed proximally, and the knee was brought through a range of motion (ROM), to verify graft isometry. Once verified, the guide pin was over-reamed to 8 mm. The layer between the retinaculum and the capsule was carefully dissected, and the graft was passed extra-articularly in the plane between the retinaculum and the capsule, out through the medial incision, and docked into the bone tunnel. An 8-mm BioComposite interference screw (Arthrex) was then placed with the knee flexed to 30°. The knee was then passed through a ROM and an arthroscopic evaluation confirmed that the patella was no longer subluxated laterally. There was normal tracking of the patellofemoral joint on arthroscopic evaluation.

Postoperatively, the patient was maintained in a hinged knee brace for 6 weeks. He was weight-bearing as tolerated when locked in full extension beginning immediately postoperatively, and allowed to unlock the brace to start non-weight-bearing active flexion and extension with therapy on postoperative day 1. Radiographs confirmed removal of the distal interlocking screw (**Figures 4A, 4B**). Following surgery, the patient experienced resolution of his effusions, no recurrent patellar instability at 1-year postoperative, and was able to return to his ADL and recreational sporting activities (Knee Injury and Osteoarthritis Outcome Score [KOOS] ADL, 100; KOOS sporting and recreational activities, 95; quality of life, 100; Marx Activity Rating Scale, 12).

Discussion

The MPFL connects the superomedial edge of the patella to the medial femur and is injured in nearly 100% of patellar dislocations.⁶ The femoral origin lies between the adductor tubercle and the medial epicondyle.⁷ The MPFL prevents lateral subluxation of the patella and acts as the major restraint during the first 20° of knee flexion. Although radiographic parameters for identifying the MPFL femoral origin have been defined by both Schöttle and colleagues⁹ and Stephen and colleagues¹⁰, it is important to check the isometry intraoperatively through a ROM when performing MPFL reconstruction. In this case, the patient's history and physical examination showed patellar instability, which was determined to be iatrogenically related to the distal interlocking screw rupture of the MPFL. Following screw removal and MPFL reconstruction, the patient had no further symptoms of pain, effusion, or patellar instability and returned to his normal activities.

Femoral malrotation following intramedullary nailing of femoral shaft fractures is a common complication,⁴ with a 22% incidence of malrotation of at least 15° in 1 series from an academic trauma center.¹¹ There are mixed data as to whether malrotation is more common in complex fracture patterns, in cases performed during night hours, and

in cases performed by non-trauma fellowship-trained surgeons.¹¹⁻¹³ The natural history of malrotation is not well elucidated, but there is some suggestion that it alters load bearing in the distal joints of the involved leg including the patellofemoral joint. Patients also may not tolerate malrotation due to the abnormal foot progression angle, particularly with malrotation $>15^\circ$.⁴ In this case, the patient's initial femoral nail was placed in an externally rotated position, requiring revision. The result of this was an unusual trajectory of the distal interlocking screw from posterolateral to anteromedial. Combined with the prominent screw tip, the trajectory of this distal interlocking screw likely contributed to the injury to the MPFL observed in this case. This trajectory would also pose potential risk to the common peroneal nerve, which is usually situated posterior to the insertion point for distal femoral interlocking screws. The prominent distal interlock screw is a well-recognized problem with femoral intramedullary nails. This issue results from the tapering of the width of the distal femur from being larger posteriorly to being smaller anteriorly. To avoid placement of a prominent distal interlocking screw, surgeons often will obtain an intraoperative anterior-posterior radiograph with the lower extremity in 30° of internal rotation to account for the angle of the medial aspect of the distal femur.

This practice represents, to our knowledge, a previously unreported cause of patellar instability as well as an unreported complication of antegrade femoral intramedullary nailing. Surgeons treating these conditions should consider this potential complication and pursue advanced imaging if patients present with these complaints after femoral intramedullary nail placement. Knowledge of both MPFL origin and insertional anatomy and avoidance of prominent distal interlocking screws in the region of the MPFL, if possible, would likely prevent this complication.

Limitations of this study include the case report design, which makes it impossible to comment on the incidence of this complication or to make comparisons regarding treatment options. There is, of course, the possibility that the patient had a concurrent MPFL injury from the injury in which he sustained the femur fracture. Nevertheless, the clinical history, examination, imaging, and arthroscopic findings all strongly suggest that the prominent distal interlocking screw was the cause of his MPFL injury and patellar instability. Finally, the point widely defined by Schöttle and colleagues¹² was used for MPFL reconstruction in this case based on an intraoperative true lateral radiograph of the distal femur. It should be noted that recent literature has debated the accuracy of this method for determining the femoral origin, the anatomy of the MPFL in relation to the quadriceps, and type of fixation for MPFL reconstruction with some advocating soft tissue only fixation.¹⁴⁻¹⁷ For purposes of this case report, we focused on a different cause of MPFL disruption in this patient and our technique for MPFL reconstruction.

Conclusion

This case demonstrates that iatrogenic MPFL injury is a potential complication of antegrade femoral nailing and a previously unrecognized cause of patellar instability. Surgeons should be aware of this potential complication and strive to avoid the MPFL origin when placing their distal interlocking screw.

This paper will be judged for the Resident Writer's Award.

Key Info

Figures/Tables

Figures / Tables:

[nho0618_f1.jpg](#)

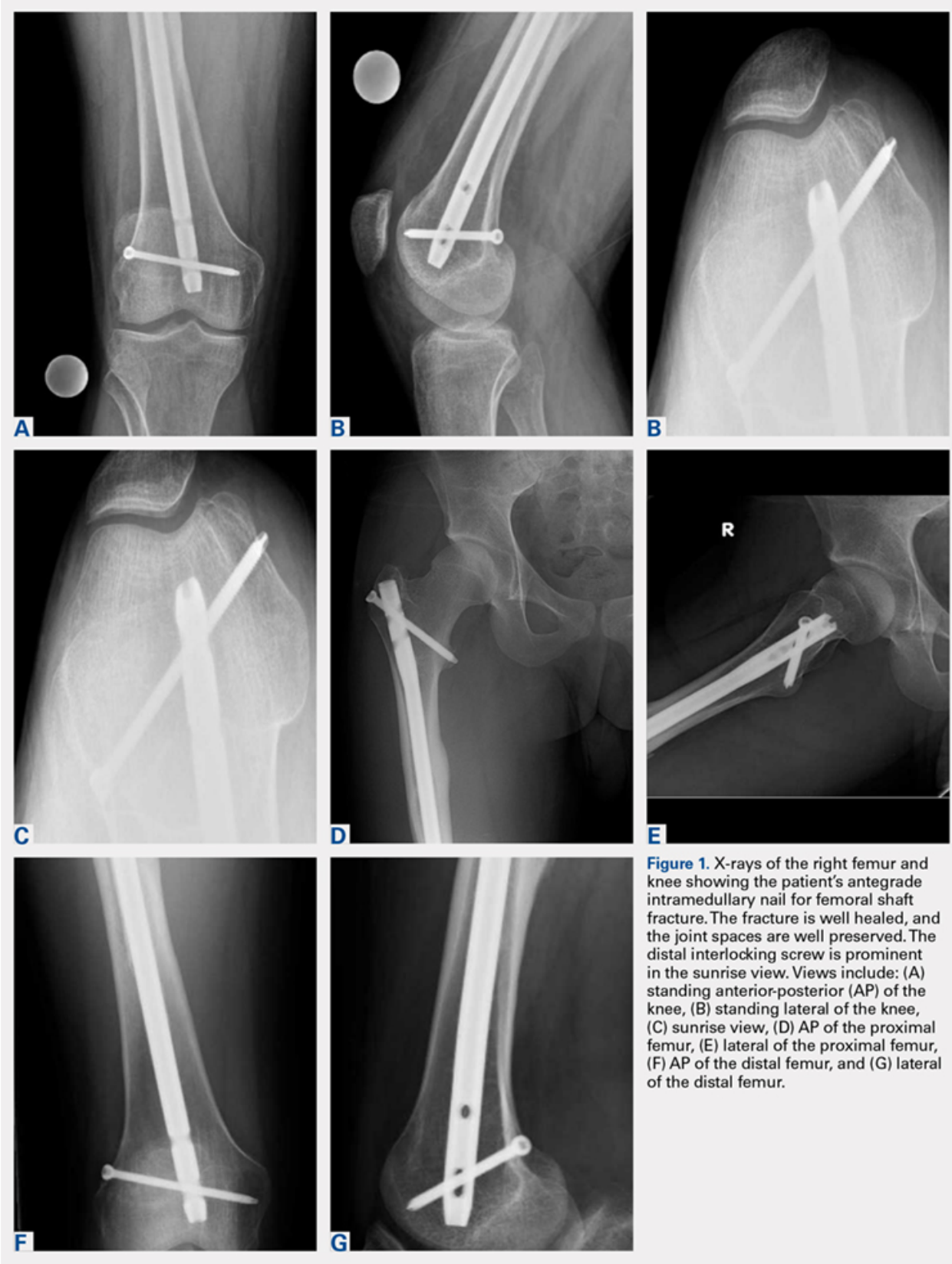

Figure 1. X-rays of the right femur and knee showing the patient's antegrade intramedullary nail for femoral shaft fracture. The fracture is well healed, and the joint spaces are well preserved. The distal interlocking screw is prominent in the sunrise view. Views include: (A) standing anterior-posterior (AP) of the knee, (B) standing lateral of the knee, (C) sunrise view, (D) AP of the proximal femur, (E) lateral of the proximal femur, (F) AP of the distal femur, and (G) lateral of the distal femur.

[nho0618_f2.jpg](#)

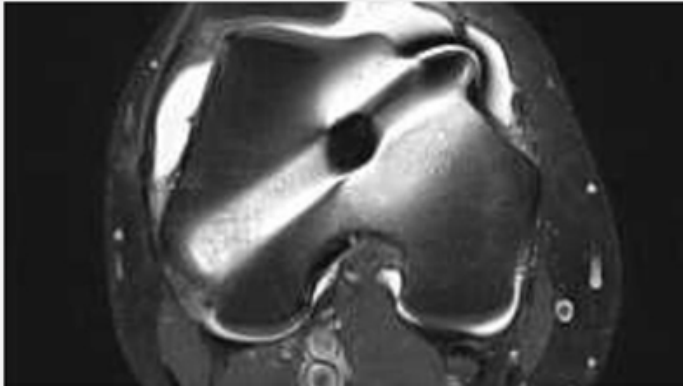


Figure 2. Axial T2 weighted magnetic resonance imaging shows moderate effusion and distal interlocking screw with prominent intra-articular extension anteromedially.

[nho0618_f3.jpg](#)

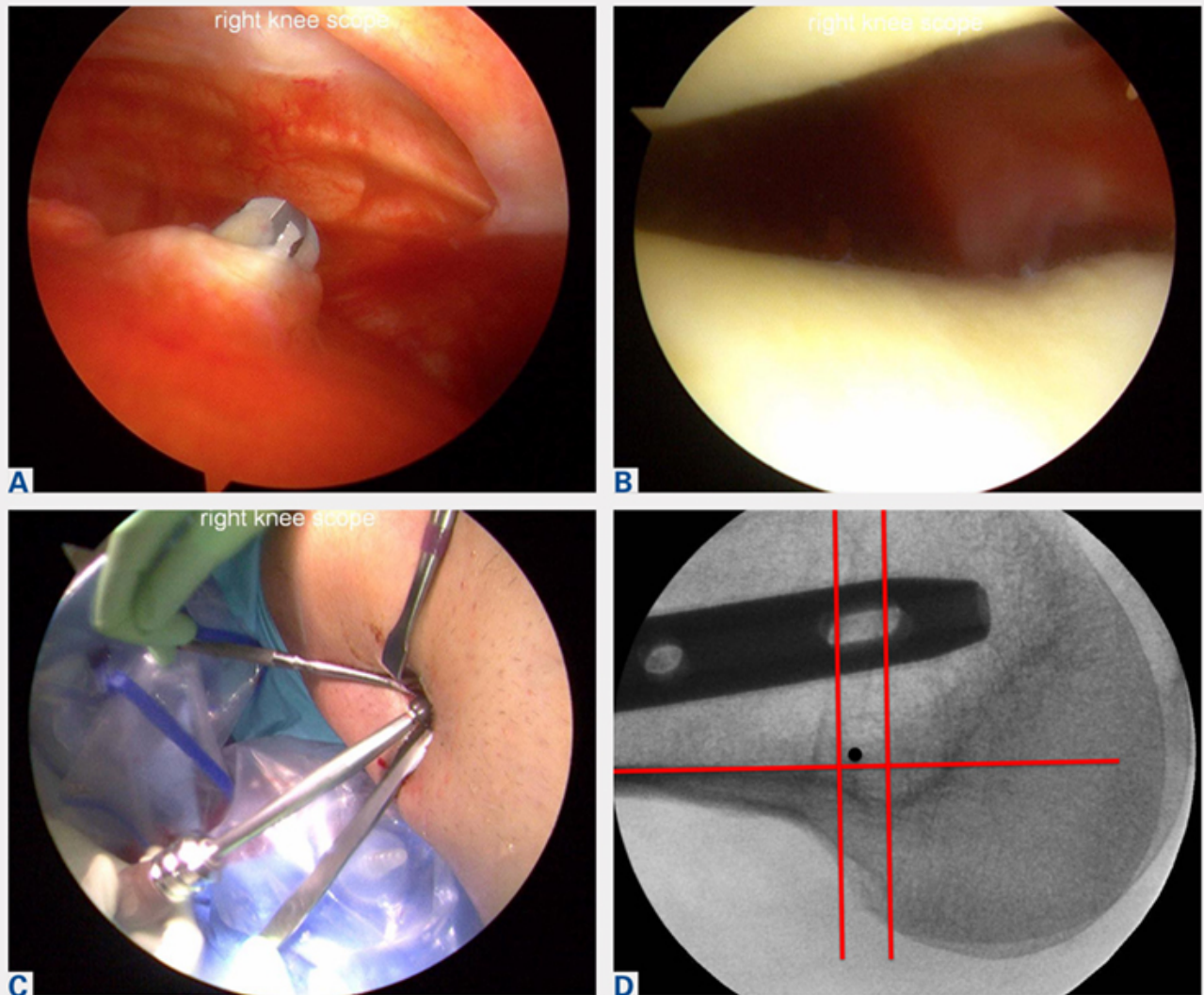


Figure 3. Arthroscopic images demonstrate (A) the distal interlocking screw tip protruding by about 3 mm intra-articularly on the medial aspect of the medial femoral condyle with surrounding synovitis. (B) The patella is tracking laterally. (C) The distal interlocking screw was removed using a small lateral incision under fluoroscopic guidance. (D) Intraoperative fluoroscopic lateral radiograph of the distal femur was used to identify Schöttle's point for determining the MPFL femoral origin, which was then confirmed for isometry on range of motion.

[nho0618_f4.jpg](#)

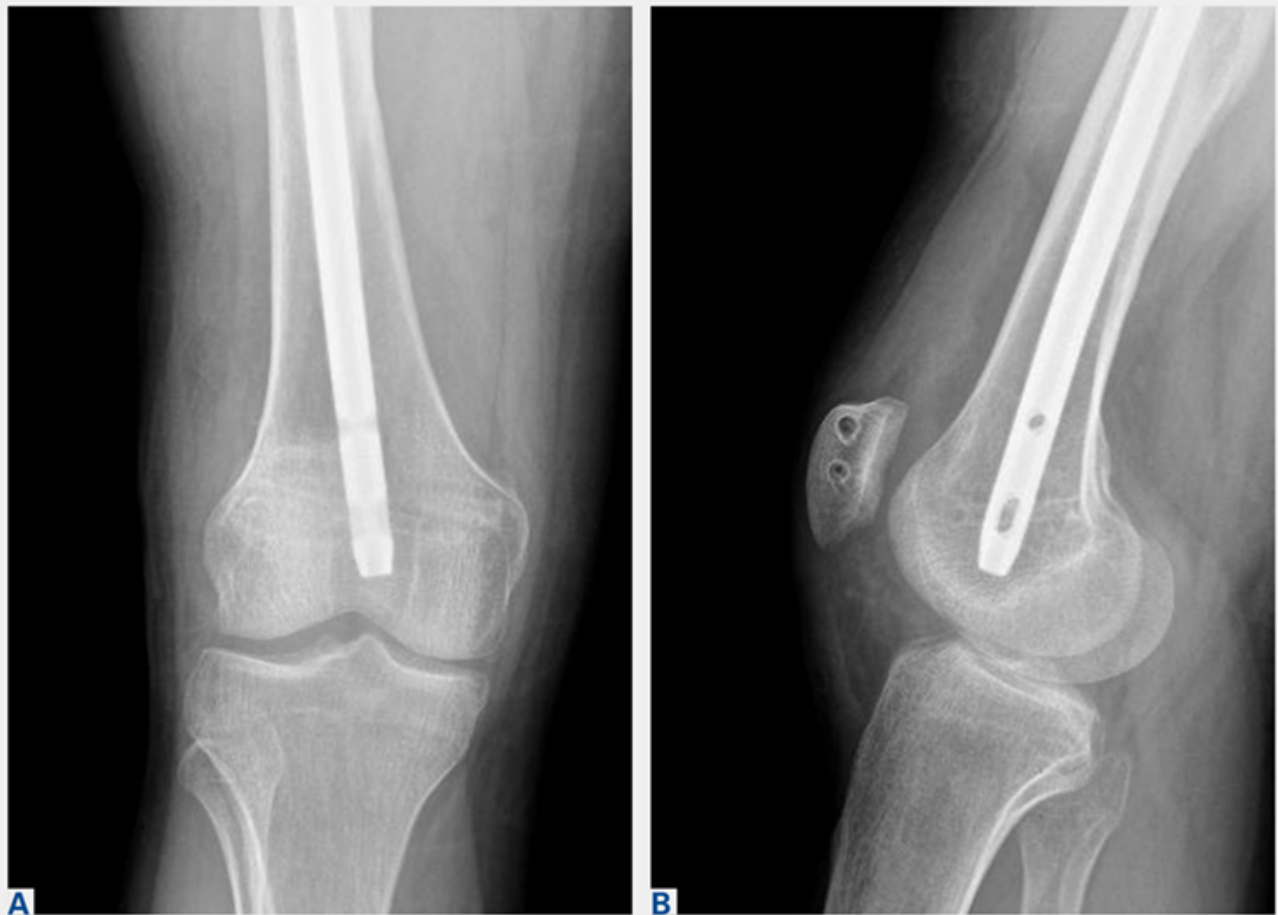

Figure 4. Postoperative standing (A) anterior-posterior and (B) lateral right knee radiographs show that the distal interlocking screw has been removed. The drill holes in the patella for medial patellofemoral ligament reconstruction can be seen on the lateral X-ray.

References

References

References

1. Brumback RJ, Virkus WW. Intramedullary nailing of the femur: reamed versus nonreamed. *J Am Acad Orthop Surg.* 2000;8(2):83-90.
2. Ricci WM, Bellabarba C, Evanoff B, Herscovici D, DiPasquale T, Sanders R. Retrograde versus antegrade nailing of femoral shaft fractures. *J Orthop Trauma* 2001;15(3):161-169.
3. Ricci WM, Gallagher B, Haidukewych GJ. Intramedullary nailing of femoral shaft fractures: current concepts. *J Am Acad Orthop Surg.* 2009;17(5):296-305.

4. Lindsey JD, Krieg JC. Femoral malrotation following intramedullary nail fixation. *J Am Acad Orthop Surg.* 2011;19(1):17-26.
5. Busam ML, Esther RJ, Obrebsky WT. Hardware removal: indications and expectations. *J Am Acad Orthop Surg.* 2006;14(2):113-120.
6. Morshed S, Humphrey M, Corrales LA, Millett M, Hoffinger SA. Retention of flexible intramedullary nails following treatment of pediatric femur fractures. *Arch Orthop Trauma Surg.* 2007;127(7):509-514.
7. Boerger TO, Patel G, Murphy JP. Is routine removal of intramedullary nails justified. *Injury.* 1999;30(2):79-81.
8. Kellan J. Fracture healing: Does hardware removal enhance patient outcomes. *Chin J Orthop Trauma (Chin).* 2010;12:374-378.
9. Schöttle PB, Schmeling A, Rosenstiel N, Weiler A. Radiographic landmarks for femoral tunnel placement in medial patellofemoral ligament reconstruction. *Am J Sports Med.* 2007;35(5):801-804. doi:10.1177/0363546506296415.
10. Stephen JM, Lumpaopong P, Deehan DJ, Kader D, Amis AA. The medial patellofemoral ligament: location of femoral attachment and length change patterns resulting from anatomic and nonanatomic attachments. *Am J Sports Med.* 2012;40(8):1871-1879. doi:10.1177/0363546512449998.
11. Hübner T, Citak M, Suero EM, et al. Femoral malrotation after unreamed intramedullary nailing: an evaluation of influencing operative factors. *J Orthop Trauma.* 2011;25(4):224-227. doi:10.1097/BOT.0b013e3181e47e3b.
12. Ayalon OB, Patel NM, Yoon RS, Donegan DJ, Koerner JD, Liporace FA. Comparing femoral version after intramedullary nailing performed by trauma-trained and non-trauma trained surgeons: is there a difference? *Injury.* 2014;45(7):1091-1094. doi:10.1016/j.injury.2014.01.024.
13. Patel NM, Yoon RS, Cantlon MB, Koerner JD, Donegan DJ, Liporace FA. Intramedullary nailing of diaphyseal femur fractures secondary to gunshot wounds: predictors of postoperative malrotation. *J Orthop Trauma.* 2014;28(12):711-714. doi:10.1097/BOT.000000000000124.
14. Ziegler CG, Fulkerson JP, Edgar C. Radiographic reference points are inaccurate with and without a true lateral radiograph: the importance of anatomy in medial patellofemoral ligament reconstruction. *Am J Sports Med.* 2016;44(1):133-142.
15. Fulkerson JP, Edgar C. Medial quadriceps tendon-femoral ligament: surgical anatomy and reconstruction technique to prevent patella instability. *Arthrosc Tech.* 2013;2(2):e125-e128. doi:10.1016/j.eats.2013.01.002.
16. Tanaka MJ, Voss A, Fulkerson JP. The anatomic midpoint of the attachment of the medial patellofemoral complex. *J Bone Joint Surg Am.* 2016;98(14):1199-1205. doi:10.2106/JBJS.15.01182.
17. Mochizuki T, Nimura A, Tateishi T, Yamaguchi K, Muneta T, Akita K. Anatomic study of the attachment of the medial patellofemoral ligament and its characteristic relationships to the vastus intermedius. *Knee Surg Sports Traumatol Arthrosc.* 2013;21(2):305-310. doi:10.1007/s00167-012-1993-7.

Multimedia

Product Guide

Product Guide

- [STRATAFIX™ Symmetric PDS™ Plus Knotless Tissue Control Device](#)
- [STRATAFIX™ Spiral Knotless Tissue Control Device](#)
- [BioComposite SwiveLock Anchor](#)
- [BioComposite SwiveLock C, with White/Black TigerTape™ Loop](#)

×

×

Citation

Gregory L. Cvetanovich, MD Gift Ukwuani, MD Benjamin Kuhns, MD Alexander E. Weber, MD Edward Beck, MPH
Shane J. Nho, MD, MS . Antegrade Femoral Nail Distal Interlocking Screw Causing Rupture of the Medial
Patellofemoral Ligament and Patellar Instability. Am J Orthop.

Publish date: July 11, 2018

Gregory L. Cvetanovich, MD
