

HAMED DAW, MD

Department of General Internal Medicine,
Cleveland Clinic.

J. HARRY ISAACSON, MD

Department of General Internal Medicine,
Cleveland Clinic.

A 52-year-old woman with skin lesions and liver function abnormalities

A SELF-TEST
of clinical
recognition

A 52-YEAR-OLD WOMAN presents to her doctor with a pruritic rash of 6 weeks' duration. Review of her medical history reveals a total abdominal hysterectomy and tobacco use. She has been taking conjugated estrogen (0.625 mg daily) for the past 6 months after complaining of hot flashes and night sweats. The only other medication she is taking is topical hydrocortisone for symptomatic relief of her rash. She denies alcohol abuse or illicit drug use.

The physical examination

On physical examination her blood pressure is 120/70 mm Hg, respiratory rate 16 per minute, and heart rate 64 beats per minute with a regular rhythm. The lungs are clear to auscultation and percussion. No cardiac murmurs or extra sounds are detected. Abdominal examination shows no organomegaly. Examination of the skin reveals enhanced facial pigmentation, increased fragility of the skin, erythema, and vesicular and ulcerative lesions involving the face, forehead, hands, and forearms (FIGURE 1).

A chemistry panel and a complete blood count show normal values. Liver function tests, however, are abnormal, with an alanine aminotransferase (ALT) level of 62 U/L (normal 0–35 U/L), an aspartate aminotransferase (AST) level of 56 U/L (normal 0–35 U/L) and a gamma-glutamyl transferase (GGT) level of 73 U/L (normal 0–30 U/L). Her serum ferritin level is 590 ng/mL (normal 18–300 ng/mL).

■ SORTING OUT THE SIGNS

1 Which is the most likely diagnosis in this patient?

- Pellagra
- Porphyria cutanea tarda
- Polymorphous light eruption
- Discoid lupus erythematosus

Skin fragility, vesicles, and erosions on sun-exposed areas in a patient taking estrogen replacement suggest porphyria cutanea tarda (PCT). This patient's history and the pattern of her rash make the other choices less likely.

Discoid lupus erythematosus also involves the face; however, it features red scaly areas showing marked follicular plugging.

Pellagra is usually associated with the triad of dermatitis, dementia, and diarrhea.

Polymorphous light eruption is an idiopathic, recurrent photosensitivity disorder, which is characterized by erythematous papules, papulovesicles, or plaques; most patients have their first attack before age 30.

What is porphyria cutanea tarda?

The porphyrias are a group of diseases that result from various defects in the metabolic pathway of heme production. PCT, the most common form of porphyria in North America, is caused by a deficiency of uroporphyrinogen decarboxylase (URO-D), the enzyme necessary to convert uroporphyrinogen to copropor-



phyrinogen in the liver (FIGURE 2). Without URO-D, uroporphyrinogen and its precursors undergo auto-oxidation outside the cells and are excreted as porphyrins, particularly uroporphyrin and 7-carboxylase porphyrin.

Full expression of URO-D deficiency requires an inducing factor such as:

- Iron overload.
- Alcohol ingestion.
- Estrogen or various other drugs such as barbiturates, phenytoin, valproic acid, or tolbutamide.
- Exposure to certain toxins, eg, hexachlorobenzene.
- Infection with hepatitis C.

■ SKIN SIGNS OF PORPHYRIA CUTANEA TARDA

2 What do the cutaneous manifestations of PCT include?

- Skin fragility, bullae, and hypertrichosis
- Dystrophic calcifications and alopecia
- Sclerodermoid changes
- Photosensitivity
- All the above

All the above manifestations are well-recognized features of PCT. The skin lesions occur on light-exposed areas and classically are in all stages of development and involution; however, the sclerodermoid changes of PCT typically spare the hands. Acute cutaneous photosensitivity reaction in PCT is rare. Ocular photosensitivity may present as bilateral keratoconjunctivitis.

■ LABORATORY ABNORMALITIES

3 Which of the following is *not* a laboratory abnormality found in PCT?

- Decreased serum iron
- Abnormal liver function tests
- Positive ANA
- Increased urinary porphyrins
- Pink fluorescence of urine when exposed to Wood's light

Sixty percent of patients with PCT have increased serum iron, and 60% have abnormal

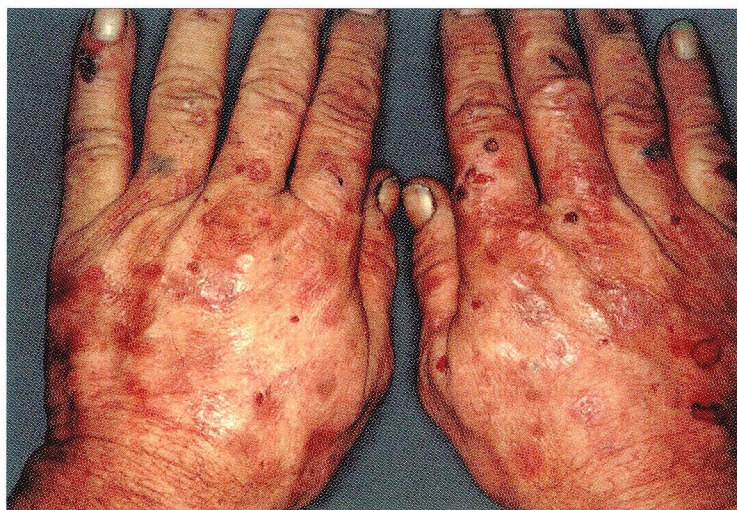

FIGURE 1. Skin lesions on hands, typical of porphyria cutanea tarda.

SOURCE: PERMISSION TO REPRINT GRANTED BY MEDCOM, INC., CYPRESS, CA

liver function tests. Positive ANA, usually in low titers, is present in 40% of patients.

The diagnosis of PCT is usually made by documenting increased urinary porphyrins, especially uroporphyrinogen. However, increased porphyrinuria is also seen in other conditions, including viral hepatitis, lymphomas, lead intoxication, acquired immunodeficiency syndrome (AIDS), and thalassemia. The urine has a red or brown color and typically displays pink fluorescence when exposed to Wood's light.

Porphobilinogen levels are typically normal. Skin biopsy may be helpful in the diagnosis, although it is not essential.

■ TREATING PORPHYRIA CUTANEA TARDA

4 What does the treatment of PCT include?

- Phlebotomy
- Chloroquine
- Sunscreens
- Erythropoietin
- All the above

In addition to withholding offending drugs, alcohol, and toxins, all of these therapies have been used.

Sixty percent of patients with PCT have increased serum iron



PATHWAY OF HEME BIOSYNTHESIS

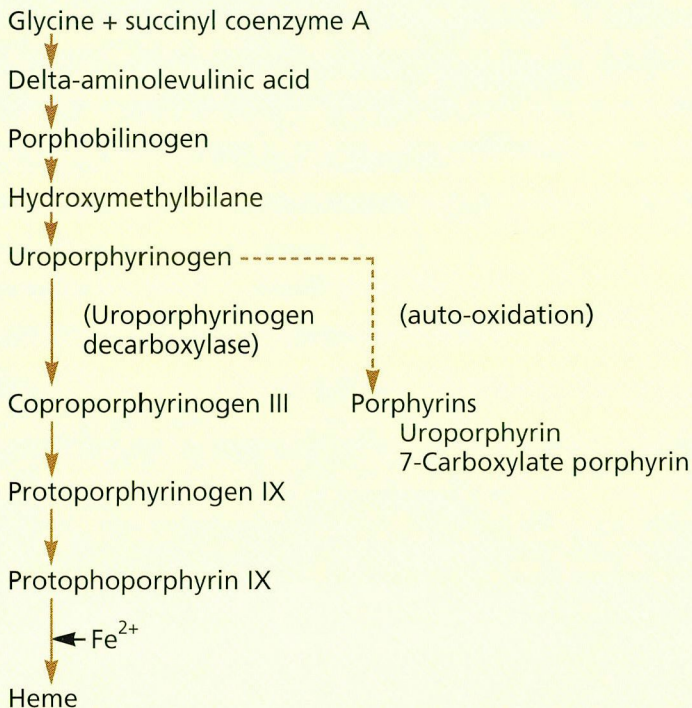


FIGURE 2 Pathway of heme biosynthesis. The normal pathway is shown on the left. In porphyria cutanea tarda, a deficiency of the enzyme uroporphyrinogen decarboxylase leads to the creation of porphyrins (depicted in the right), which are excreted in the urine.

Phlebotomy works by depleting excessive iron stores. Five to six phlebotomies (500 cc of blood weekly) are usually needed to achieve remission. With this form of therapy, blistering is the first sign to disappear, liver function tests return to normal within 1 year, and clinical remission is maintained for an average of 30 months. Biochemical targets are:

- A serum iron concentration of 50 to 60 $\mu\text{g}/\text{dL}$.
- A normal serum ferritin level.
- A hemoglobin concentration of 10 to 11 g/dL .

Chloroquine in low doses is used in patients who are not candidates for phlebotomy (eg, anemic patients). Chloroquine binds to hepatic porphyrins and forms water-soluble complexes that are excreted in the urine.

Erythropoietin may be helpful, apparently

by mobilizing stored iron into hemoglobin.

Sunscreens are useful as adjunctive therapy and should be used until phlebotomy begins to have a beneficial effect.


■ ASSOCIATED CONDITIONS

5 Which of the following conditions are associated with PCT?

- Thalassemia
- AIDS
- Hepatic tumors
- Bone marrow transplant
- All the above

Benign and malignant primary liver tumors in the absence of cirrhosis have been reported in patients with PCT. In one reported patient, all clinical evidence of PCT disappeared when the tumor, a benign hepatic adenoma, was surgically removed.

PCT is increasingly being recognized in patients with HIV infection; all reported cases were in men, with a mean age of 36 years. Most had a history of intravenous drug abuse and alcoholism, with an average CD4 count ranging from 3 to 400 per cc. Phlebotomy is generally contraindicated in patients with AIDS and PCT because it can cause anemia. The mainstay of treatment—in addition to alcohol abstinence—is chloroquine in a low dosage (25 mg twice a week) and is usually effective.

Thalassemia and bone marrow transplantation are less commonly associated with porphyria cutanea tarda. 

■ SUGGESTED READING

Anderson KE, Goeger DE, Carson RW, Lee SM, Stead RB. Erythropoietin for the treatment of porphyria cutanea tarda in a patient on long-term hemodialysis. *N Engl J Med* 1990; 322:315–317.

Blauvelt A, Harris HR, Hogan DJ, Jimenez-Acosta F, Ponce I, Pardo RJ. Porphyria cutanea tarda and human immunodeficiency virus infection. *Int J Dermatol* 1992; 31:474–479.

Grossman ME, Poh-Fitzpatrick MB. Porphyria cutanea tarda: diagnosis and management. *Med Clin North Am* 1980; 64: 807–827.

Ippen H. Treatment of porphyria cutanea tarda by phlebotomy. *Semin Hematol* 1977; 14:253–259.

Topi GC, Amantea A, Griso D. Recovery from porphyria cutanea tarda with no specific therapy other than avoidance of hepatic toxins. *Br J Dermatol* 1984; 111:75–82.

Tsega E, Besrat A, Damtew B, Seyoum E, Landells JW. Chloroquine in the treatment of porphyria cutanea tarda. *Trans R Soc Trop Med Hyg* 1982; 75:401–404.