

TERESA L. CARMAN, MD

Department of Internal Medicine, Cleveland Clinic
Florida, Fort Lauderdale

BERNARDO B. FERNANDEZ, JR., MD, FACP

Department of Vascular Medicine, Cleveland Clinic
Florida, Fort Lauderdale

Issues and controversies in venous thromboembolism

■ ABSTRACT

This paper gives specific recommendations on a number of issues in venous thromboembolism: how to evaluate idiopathic deep vein thrombosis (DVT); how to treat calf vein thrombosis and upper-extremity DVT; how to use low-molecular-weight heparin, vena cava filters, catheter-directed thrombolytic therapy, and compression stockings; how long to continue anticoagulation therapy; and how to manage recurrent DVT.

■ KEY POINTS

In younger patients, hypercoagulable disorders are found in 48% of cases of idiopathic venous thrombosis.

Recent evidence indicates that calf vein thrombosis is more dangerous than previously thought and merits more aggressive management.

Low-molecular-weight heparin has a role in both treating and preventing DVT.

Thrombolytic therapy has been documented to reduce the postthrombotic complications of upper-extremity DVT.

Patients with recurrent disease may need prolonged anticoagulation therapy.

VENOUS THROMBOEMBOLISM, which includes deep vein thrombosis and pulmonary embolism, is a common disorder frequently encountered in the practice of medicine.

A number of excellent reviews discuss different aspects of the disorder, including etiology, diagnosis, and management.¹⁻⁴ Our goal is to discuss some issues not commonly addressed in these reviews and to provide recommendations regarding specific issues in thromboembolism:

- How should idiopathic DVT be evaluated?
- Does isolated calf vein thrombosis require anticoagulation?
- What are key treatment issues in upper-extremity DVT?
- How should low-molecular-weight heparin be used?
- What is the role of thrombolytic therapy as initial treatment of DVT?
- When should inferior vena cava filters be used?
- Are compression stockings under-used?
- How long should the patient receive anticoagulation?
- What is the best diagnostic strategy for recurrent DVT?

■ HOW SHOULD IDIOPATHIC DVT BE EVALUATED?

As described by Virchow in 1845, venous thromboembolism is best understood as an interaction between three variables: hypercoagulability, venous stasis, and vascular damage (FIGURE 1). Most patients presenting with DVT have an identifiable cause. But in the minori-

Factors that predispose patients to deep venous thrombosis: interactions between the elements of Virchow's triad

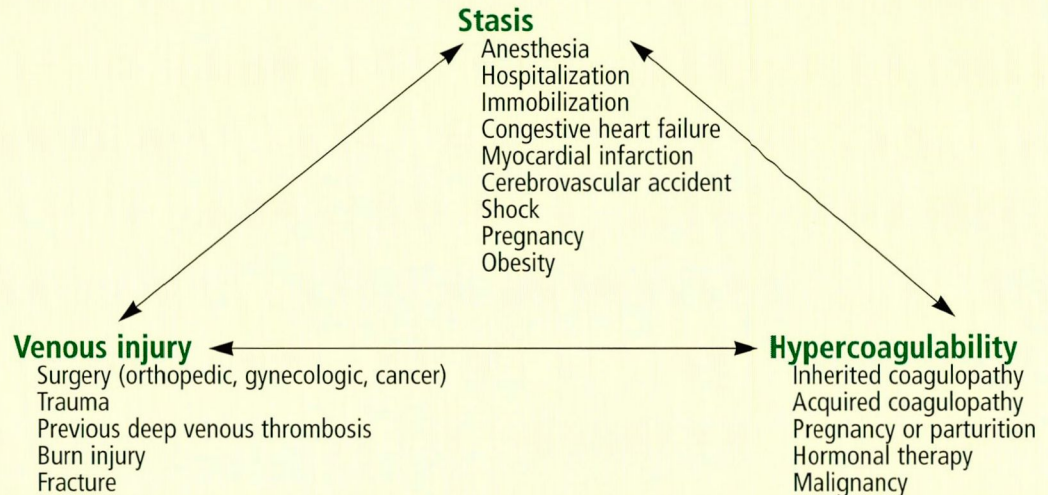


FIGURE 1

In screening for malignancy in idiopathic DVT, start with simple tests

ty of patients in whom no such factor is obvious, how far should the physician go in looking for an underlying condition such as a malignancy or a hypercoagulable disorder?

Searching for malignant disease

Malignant disease causes some percentage of cases of DVT, but we do not know the exact number. Prandoni et al⁵ prospectively followed 250 patients after screening them for malignancy after an episode of idiopathic DVT. At 2 years, a malignant disease had been diagnosed in 7.6%—and in 17.1% of patients with recurrent idiopathic DVT. Prins et al⁶ reviewed 13 cohort studies and found that the incidence of occult malignancy in idiopathic DVT ranged from 0% to 38%, although many of these studies probably overestimated this association because they did not exclude patients with symptoms compatible with malignancy at the time of enrollment.

Few studies have addressed ways to identify patients with DVT caused by occult malignant disease,⁷⁻⁹ and there is no consensus on an appropriate or cost-effective screening method.^{9,10} However, the standard history, physical examination, laboratory tests, and chest radiograph may be enough. Cornuz et al⁸ examined data from 136 hospitalized patients

with idiopathic DVT. Malignant diseases were diagnosed in 16 (12%) of the 136 patients during their hospital stay, and all 16 had one or more abnormal findings in their history, physical, laboratory tests, or chest radiograph. The probability of detecting a malignancy increased as the number of abnormal findings increased.

Further testing with flexible sigmoidoscopy, mammography, cervical cytology screening, or chest radiography should be done as directed by abnormalities on the initial evaluation and in consensus with recommended screening guidelines (TABLE 1).¹¹

Searching for a coagulopathy

In younger patients, inherited or acquired hypercoagulable disorders account for up to 48% of cases of idiopathic DVT, making them the most common cause (TABLE 2).¹² Most hypercoagulable states become manifest under the influence of a prothrombotic stimulus such as surgery, trauma, pregnancy, or oral contraceptive use. In the general population, the most prevalent hypercoagulable disorder is activated protein C resistance, usually from a defect in the gene for factor V.

Ridker et al¹³ found that, up to age 50, men with the factor V Leiden mutation had a



very low incidence of DVT and pulmonary embolism, no different than in persons without the mutation. However, after age 50, the incidence increased with age. Persons older than age 70 had 7.83 events per 1,000 person-years, compared with 1.86 in those younger than 50 years.

When to search for a hypercoagulable state is similar to the issue of when to search for a malignant disease in acute idiopathic venous thrombosis. Ginsberg³ identified the following situations in which a workup is indicated:

- Any idiopathic DVT associated with a family history of DVT
- DVT in a patient younger than age 50
- DVT in an unusual site, ie, other than an extremity
- Massive venous thrombosis
- Recurrent episodes of thrombosis.

To this list we would add recurrent fetal loss.

Evaluating idiopathic DVT: Recommendations

- Evaluations for hypercoagulable disorders must be individualized.
- In patients over age 50, a limited search for malignancy or factor V Leiden mutation may be indicated.
- In general, younger patients are more likely to have a disorder of thrombophilia.

■ DOES ISOLATED CALF VEIN THROMBOSIS REQUIRE ANTICOAGULATION?

In the past, physicians assumed that isolated calf vein thrombosis posed a limited clinical risk and, therefore, often undertreated it or did not treat it at all. Today, several lines of evidence indicate that calf vein thrombosis is more dangerous than previously thought and merits more aggressive management.

Isolated calf vein thrombosis is a relatively common presentation of DVT. Moreover, signs and symptoms are neither sensitive nor specific for the clinical diagnosis of DVT, in the calf or otherwise. In a study of asymptomatic postoperative patients,¹⁴ the prevalence was 12%. In another study of patients with signs and symptoms suggestive of acute DVT, the prevalence was 5%.¹⁵ Therefore, consider-

TABLE 1

Screening for cancer in idiopathic deep venous thrombosis

Complete medical history

- Past medical and surgical history
- Family history
- Complete review of systems

Physical examination

Laboratory tests

- Complete blood count
- Basic chemistry
- Urinalysis
- Stool occult blood
- Prostate-specific antigen

Consider

- Chest radiography
- Mammography
- Flexible sigmoidoscopy or colonoscopy
- Cervical cytology

TABLE 2

Inherited and acquired thrombophilias (hypercoagulable states)

- Factor V Leiden mutation
- Activated protein C resistance
- Protein C deficiency
- Protein S deficiency
- Antithrombin III deficiency
- Anticardiolipin antibody
- Lupus anticoagulant
- Heparin cofactor II deficiency
- Plasminogen deficiency

Calf vein thrombosis merits more aggressive treatment

ation must be given to making the diagnosis in appropriate patient populations.

Calf vein thromboses propagate to proximal segments in 13% to 32% of cases,^{14,16-19} and those that propagate pose a greater risk of pulmonary embolism than do those that do not. No study has been able to identify risk factors or clinical signs predictive of propagation.^{17,18,20}

Calf vein thrombosis was the source of 15% to 25% of fatal pulmonary emboli in autopsy studies,²¹⁻²³ and the source of 5% to

TABLE 3

Etiology of upper-extremity deep venous thrombosis

Primary

Paget-Schroetter syndrome
(effort thrombosis)
Idiopathic

Secondary

Venous catheters
Pacemaker wires
Extrinsic compression or obstruction
Malignancy
Traumatic injury
Thrombophilic states

35% of pulmonary emboli that caused respiratory symptoms in two other studies.^{17,24} In yet another study,²⁵ calf vein thrombosis was associated with a 33% incidence of “silent” pulmonary embolism.

Isolated calf-vein thrombosis: Recommendations

- Calf vein thrombosis should be treated with anticoagulant drugs to prevent propagation and possible embolization.
- If anticoagulation is contraindicated, we recommend obtaining duplex ultrasound scans weekly for 2 to 3 weeks to monitor for proximal propagation.
- If the thrombus propagates to a proximal segment and anticoagulation is not possible, then an inferior vena cava filter should be inserted.

■ WHAT ARE KEY TREATMENT ISSUES IN UPPER-EXTREMITY DVT?

DVT in the upper extremities seems to be increasing in incidence. The increase may be real and due to greater use of indwelling vascular catheters. On the other hand, physicians today may simply be more aware of this condition.

The presenting signs and symptoms of upper-extremity DVT are like those of lower-extremity DVT—pain, swelling, limb discoloration, decreased function, dilated collateral veins, and occasionally a hard, palpable, cord-like vein. As in lower-extremity DVT, venog-

raphy is the gold standard for diagnosis. However, venous duplex and compression ultrasonography are noninvasive and very sensitive and specific.

Upper-extremity DVT is either primary (ie, has no identifiable cause) or secondary to another condition (TABLE 3).

Primary upper-extremity DVT, also known as Paget-Schroetter syndrome or effort thrombosis, is most common in young male athletes or laborers who must repeatedly abduct and extend their arms. It most commonly occurs in the dominant arm. It is often related to obstruction of the thoracic outlet and an underlying venous stricture. The obstruction may be due to compression from the first rib or an anomalous cervical rib, congenital fibrous bands, or compression from the anterior scalene muscle.

Secondary upper-extremity DVT is most commonly due to intravenous devices such as indwelling catheters or pacemaker wires. However, it may occur with venous trauma, extrinsic compression from a tumor, or a hypercoagulable state.

Complications of upper-extremity DVT

The complications of upper-extremity DVT are similar to those of lower extremity DVT—pulmonary embolism, postthrombotic syndrome, and venous gangrene (rare).

Pulmonary embolism occurred in 9.4% of patients with upper-extremity DVT in one study,²⁶ and in 36% in another study.²⁷ Clearly, the risk is significant, and deaths have been reported. Hingorani et al²⁸ found that after 6 months of follow-up, patients with upper-extremity DVT had a much higher rate of pulmonary embolism than did patients with lower-extremity DVT (17% vs 8%). Moreover, pulmonary embolism due to upper-extremity DVT conferred a higher rate of death than did those due to lower-extremity DVT (48% vs 13%).

In another study, Hingorani et al²⁹ found that hospitalized patients with upper-extremity DVT had very high 1-month and 3-month mortality rates. The overall incidence of pulmonary embolism was 7%, but the rate of postthrombotic complications was very low (2% to 4%).

Venography or venous duplex ultrasound is key to diagnosing recurrent DVT



Postthrombotic syndrome also varied widely in incidence in reported studies, from 1.5% to 34%.^{26,27,29} The incidence may be higher in persons with effort-induced disease, in whom long-term sequelae are more likely to manifest. The incidence may also be lower in patients with upper-extremity DVT caused by a vascular catheter, because they generally do not have underlying venous strictures and chronic damage to the vein.

Treatment issues in upper-extremity DVT

The mainstays of treatment for upper-extremity DVT have traditionally been to elevate the extremity, place the patient on bed rest, apply warm compresses, and give heparin. Today, thrombolytic therapy and vena cava filters also have a role, as they do in lower-extremity DVT (see discussion below).

Thrombolytic therapy has been documented to reduce the postthrombotic complications of upper-extremity DVT. AbuRahma et al³⁰ reported that 3 of 4 patients who received thrombolytic therapy experienced complete resolution, compared with 1 of 6 patients who received a standard regimen of heparin and warfarin.

In a series of 50 patients, Machleder³¹ evaluated thrombolytic therapy, anticoagulation, surgical intervention, and balloon angioplasty. After a mean of 3.1 years, 88% of patients had resumed their usual occupations and activities, and 80% were symptom-free or had minimal residual symptoms. Results of thrombolytic therapy with urokinase were significantly better than with streptokinase, heparin, warfarin, or no therapy. Unfortunately, this study had no control group, and not all patients received the same therapies, making any comparison difficult. The investigator recommended treatment aimed at relieving the thrombotic condition, then focusing on the underlying mechanical abnormality responsible for the obstruction.

Superior vena cava filters. Few studies have examined the use of SVC filters. Ascer et al³² described six patients who successfully underwent SVC filter placement with no complications. However, complications can occur with SVC filters, as with IVC filters

(see discussion below). For example, the filter can migrate into nearby cardiac structures, though this is rare. The filter can also occlude, in which case the patient usually has symptoms of acute or chronic SVC syndrome: facial and upper-extremity edema, hoarseness, and dilated collateral veins. SVC filter placement does not preclude venography or transesophageal echocardiography or right-heart catheterization for hemodynamic monitoring.

The indications for SVC filter placement are similar to those for inferior vena cava (IVC) filter placement:

- If the patient cannot tolerate even a small pulmonary embolus
- If anticoagulation is contraindicated
- If anticoagulation therapy fails to prevent embolization
- If the patient suffers a major bleeding episode while undergoing anticoagulation therapy.

Managing upper-extremity DVT: Recommendations

- All patients with upper-extremity DVT, regardless of the etiology, should receive anticoagulation therapy if they have no contraindication to it.
- If anticoagulation is contraindicated, consider SVC filter placement to prevent pulmonary embolism.
- Primary upper-extremity DVT requires catheter-directed thrombolysis (if no contraindications exist), followed by anticoagulation for 1 to 3 months, resection of the first rib to relieve thoracic outlet obstruction, and, possibly, percutaneous balloon angioplasty if a residual venous stricture is present.

Secondary upper-extremity DVT requires treatment based on the underlying disorder, with the following considerations:

- If an indwelling catheter is present and still needed, begin with thrombolysis via the existing catheter, followed by anticoagulation for as long as the catheter remains in place.
- If the indwelling catheter is no longer necessary, remove it and give anticoagulation therapy for 3 months.

Acute Paget-Schroetter syndrome requires thrombolysis

■ HOW SHOULD LOW-MOLECULAR-WEIGHT HEPARIN BE USED?

Formulations of low-molecular-weight heparin are relatively new in the United States. Currently, they are most commonly used for preventing venous thromboembolism, but there is increasing evidence that they are safe and effective for treating DVT as well.

Low-molecular-weight heparin has several advantages in DVT treatment. Most formulations can be given once or twice daily by subcutaneous injection. Doses are fixed and based on the patient's weight; therefore, the partial thromboplastin time and heparin levels do not need to be monitored during therapy. In addition, patients can learn to give themselves the injections at home, thereby shortening the hospital stay or avoiding it entirely.

Low-molecular-weight heparin as initial treatment of acute DVT

In a 1995 meta-analysis, Lensing et al³³ calculated that patients with acute DVT who received low-molecular-weight heparin as initial treatment had 53% fewer thromboembolic complications, 68% fewer major hemorrhagic complications, and 47% fewer deaths than did patients who received standard heparin. Not all of the differences achieved statistical significance in every study, but each study showed similar trends.

Low-molecular-weight heparin in outpatient treatment

More recently, four studies³⁴⁻³⁷ evaluated the use of low-molecular-weight heparin in outpatients and in patients with pulmonary embolism. None of the four studies demonstrated a statistically significant difference in the rates of recurrence or major bleeding episodes. However, the two studies of outpatient treatment^{34,35} showed a trend towards fewer days in the hospital for patients receiving low-molecular-weight heparin. The potential cost-saving is substantial in patients with DVT who are not candidates for thrombolysis. US Food and Drug Administration approval for low-molecular-weight heparin therapy for DVT is pending.

Outpatient therapy with low-molecular-weight heparin: Recommendations

- Consider outpatient therapy in patients with a low clot burden who do not meet the criteria for thrombolytic therapy, patients without evidence of pulmonary embolism, patients without risk factors for bleeding complications of anticoagulation, and compliant patients most likely to safely self-administer low-molecular-weight heparin injections.
- Begin therapy with enoxaparin 1 mg/kg injected subcutaneously every 12 hours.
- Start warfarin by mouth on the first day of therapy.
- Overlap low-molecular-weight heparin and warfarin for 4 to 5 days. Then, when the international normalized ratio is in the therapeutic range, discontinue low-molecular-weight heparin and continue the warfarin for the duration of therapy.

■ WHAT IS THE ROLE OF THROMBOLYTIC THERAPY AS INITIAL TREATMENT OF DVT?

Heparin prevents clot formation but does not dissolve the existing thrombus. For this reason, physicians are turning to another option for initial treatment of DVT: thrombolytic drugs. However, thrombolytic therapy may be indicated only in very limited instances, and there are considerable risks associated with its use.

When considering the use of thrombolytic therapy, several factors must be taken into account. First, thrombolytic therapy produces a systemic fibrinolytic state and a significant potential for bleeding complications. Therefore, many patients will not be candidates for this therapy. TABLE 4 lists absolute and relative contraindications to thrombolytic therapy. Second, Bjarnason et al³⁸ demonstrated that 66% to 100% of thrombi less than 28 days old could be successfully lysed, compared with only 33% of thrombi present for more than 4 weeks. Therefore, the duration of symptoms and chronicity of the thrombus must be considered.

Thrombolytic therapy is best done via a catheter-directed approach as opposed to a peripheral infusion. To achieve this, a multi-

Low-molecular-weight heparin is as safe and effective as regular heparin



ple side-port catheter is placed with the assistance of a cardiologist or interventional radiologist, in the interventional angiography suite. Thus, the lytic agent, most commonly urokinase, is infused directly into the clot, resulting in higher local levels of the thrombolytic agent and, in theory, more rapid resolution of the thrombus with fewer bleeding complications than with peripheral infusion. In addition, with venous access in place, follow-up venography is easy. The thrombolytic infusion is continued until dissolution of the thrombus is obtained. If, on repeat venography, there is no change in the thrombus after 48 hours of therapy, it is unlikely that further lytic therapy will be successful.

Short-term results

Semba and Dake³⁹ treated 21 patients in this manner and obtained technical and clinical success in 18 (72%) of 25 treated limbs without any major bleeding complications or clinically evident pulmonary embolism.

Bjarnason et al³⁹ reported an overall success rate of 79% (86% success in iliac veins and 63% success in femoral veins) over a 5-year period. Successful therapy was defined as complete thrombolysis with restoration of normal flow and less than 30% residual luminal narrowing, or as partial thrombolysis in which the remaining segments of narrowing or occlusion were amenable to restoration of normal flow by angioplasty, stent placement, or surgical bypass. In this series, 6 patients suffered major complications (eg, bleeding requiring a transfusion, pulmonary embolus), and 13 patients experienced minor complications (bleeding not requiring transfusion, stent dislodgement, or IVC filter dislodgement).

Long-term results:

Preventing postthrombotic syndrome

The goals of thrombolysis in DVT are to preserve venous valve function, alleviate the venous thrombotic obstruction, and reduce venous hypertension. These goals are aimed at reducing the acute symptoms of DVT and preventing the postthrombotic syndrome.

The postthrombotic syndrome includes

TABLE 4

Contraindications to thrombolysis

Absolute

- Active internal bleeding
- Known bleeding disorder
- Intracranial disease (cancer, aneurysm, or arterial-venous malformation)
- Recent stroke (within 2 months)
- Intracranial or intraspinal surgery
- Previous allergic reaction to thrombolytics

Relative

- Recent major surgery (within 1 month)
- Recent major trauma
- Prolonged cardiopulmonary resuscitation
- Recent gastrointestinal or urologic bleeding
- Pregnancy or postpartum state
- Uncontrolled hypertension
- Age > 75 years
- Bacterial endocarditis
- Diabetic hemorrhagic retinopathy

chronic edema, persistent and debilitating pain, venous hypertension, venous ulceration, and venous claudication, sometimes manifesting as brawny edema, hyperpigmentation, medial malleolar ulceration, varicose vein formation, cellulitis, and stasis dermatitis. It occurs as a consequence of persistent venous obstruction or reflux due to valvular insufficiency. Recent studies^{40,41} estimate its incidence at 29% to 41% several years after the initial thrombotic event. The syndrome imposes considerable costs from the treatment of complications such as venous ulceration and cellulitis,⁴² and from the morbidity of the disease as it affects daily activities, employment, and lifestyle.⁴³

In one study, Arnesen et al⁴⁴ reevaluated 35 patients previously randomized to receive heparin or peripherally infused thrombolytic agents. He found that 76.5% of the patients who received thrombolytic therapy had clinically normal extremities, compared with only 33.3% of those treated with heparin. In addition, fewer persons had moderate changes of venous insufficiency (23.5% vs 50%) or serious symptoms such as ulceration (0% vs 16.7%).

Thrombolysis may be less effective for chronic DVT

Thrombolytic therapy: Recommendations

If no contraindications exist, consider catheter-directed thrombolytic therapy in patients with:

- Iliofemoral venous thrombosis
- Symptomatic DVT despite anticoagulation
- Phlegmasia cerulea dolens
- Phlegmasia alba dolens
- Axillary-subclavian vein thrombosis.

■ WHEN SHOULD INFERIOR VENA CAVA FILTERS BE USED?

Despite the widespread use of IVC filters, few studies have evaluated their safety and efficacy. In 1992, Becker et al⁴⁵ reviewed the published literature on IVC filters—24 case series. The most common reason for filter placement, cited in 59% of cases, was a contraindication to anticoagulation or a complication from anticoagulation. Other reasons included failure of anticoagulation or prophylaxis against pulmonary embolism in patients with underlying cardiac or pulmonary disease in whom pulmonary embolism would be poorly tolerated.

A recent study by Decousus et al⁴⁶ investigated the ability of IVC filters to prevent pulmonary embolism in anticoagulated patients considered to be at high risk for pulmonary embolism. At 12 weeks they found a statistically significant reduction in the number of symptomatic and asymptomatic pulmonary embolisms. However, the difference was no longer significant at 2 years. Of note: significantly more patients with filters experienced recurrent DVT than did patients without filters: 20.8% vs 11.6%. This experience led the authors to recommend continued anticoagulation in patients without contraindications, even after filter placement.

IVC filters can cause many complications: technical difficulties during placement, insertion-site DVT, filter migration, erosion of the filter into the IVC wall, IVC obstruction, and lower extremity venous insufficiency.⁴⁵ With this in mind, IVC filters should be used judiciously and only in patients with clear indications.

IVC filters: Recommendations

- IVC filters should be reserved for patients in whom anticoagulation is contraindicated, complicated, or previously ineffective, or patients with significant cardiopulmonary disease in whom a small pulmonary embolus may not be tolerated.
- After filter placement, continued anticoagulation is prudent, when possible.

■ ARE COMPRESSION STOCKINGS UNDERUSED?

Compression stockings prevent or minimize postthrombotic sequelae in patients with DVT. Yet they are underused.

Recently, Brandjes et al⁴⁷ followed 194 DVT patients for a median 76 months. Compared with controls, patients using custom-fitted graduated compression stockings had 50% fewer postthrombotic complications.

Given the potential morbidity from postthrombotic complications, this simple, noninvasive intervention should be further studied and universally applied.

Compression stockings: Recommendations

- Prescribe compression stockings, to be worn continuously beginning 2 weeks after the onset of thrombosis.
- Advise patients to wear the stockings for at least 1 year following the thrombotic event.

■ HOW LONG SHOULD THE PATIENT RECEIVE ANTICOAGULATION?

Currently, the standard therapy for thromboembolic disease consists of intravenous heparin followed by warfarin. But whether to treat, how to treat, and how long to treat can be debated in many of the situations addressed above, and in all instances the risk of hemorrhage must be weighed against the possible benefit of treatment.

When is shorter or longer anticoagulation appropriate?

There is no consensus on optimal duration of anticoagulation after a DVT episode.

Treat a first episode of DVT for 3 to 6 months



DVT is often associated with an acute stimulus of limited duration, such as surgery, immobility, or trauma. In these cases, some experts suggest that therapy should continue until the stimulus resolves, but not longer. In addition, some researchers have documented the risk of DVT recurrence or proximal propagation to be greatest early in treatment.^{16,20} Therefore, short-term therapy is usually acceptable in patients with time-limited risk factors or isolated calf vein thrombosis. In an uncomplicated DVT, 3 to 6 months of anticoagulation is generally indicated.

Two recent studies^{48,49} compared therapy lasting 4 or 6 weeks vs therapy lasting 3 or 6 months after a first episode of DVT. In both studies, DVT recurred significantly less often with longer therapy. Of interest, in an ad hoc subgroup analysis of one of the studies,⁴⁸ fewer treatment failures and fewer recurrences occurred in postoperative patients than among medical patients; postoperative patients fared equally well with shorter or longer treatment, but medical patients fared better with longer treatment. In a subgroup analysis of the other study,⁴⁹ patients with permanent risk factors had a 24% recurrence rate with 6 weeks of therapy vs a 12% recurrence rate when treated for 6 months.

While somewhat out of context with these studies, a risk-factor analysis may be warranted in individual patients, to determine their risk of recurrent or ongoing venous thrombosis. Patients with malignant disease or a hypercoagulable state may need long-term therapy—at least a year, and possibly lifelong. Patients with recurrent DVT may also need prolonged or indefinite therapy. A definitive study to clarify this issue is needed.

Minimizing the risk of hemorrhage. Recently, Schulman et al⁵⁰ found that patients who received warfarin indefinitely after a recurrent episode of DVT had a significantly lower incidence of further recurrent events than did similar patients who received warfarin for only 6 months: 2.6% vs 20.7%. However, the group treated indefinitely had a higher incidence of major hemorrhage: 8.6% vs 2.7%. While this trend did not reach statistical significance, it should alert the clinician to the possibility of this complication.

Several factors increase the risk of hemorrhage during anticoagulation therapy^{51,52}: serious comorbid illness, progressive liver dysfunction, initial anticoagulation with heparin, and a prolonged prothrombin time or partial thromboplastin time.

How long to treat: Recommendations

- For a first episode of primary DVT (including calf vein thrombosis), give warfarin for 3 to 6 months, depending on the risk factors present.
- A second episode of DVT should be treated for a minimum of 1 year.
- Patients with three or more episodes should be treated indefinitely.
- DVT in a patient with ongoing risk factors (ie, uncontrolled malignancy or a hypercoagulable state) should be treated indefinitely.
- In all cases, the risks of anticoagulation must be weighed against the benefits obtained.

■ WHAT IS THE BEST DIAGNOSTIC STRATEGY FOR RECURRENT DVT?

DVT often recurs. Two recent studies^{20,40} found a cumulative incidence of recurrence of up to 30% at 8 years after the initial event. Recurrent episodes were more common in patients with ongoing risk factors such as malignancy or a hypercoagulable state, and less common in patients with a temporary risk factor such as surgery or immobilization.⁴⁰

Limitations of current diagnostic techniques

Unfortunately, recurrent DVT is difficult to diagnose. Of the available techniques, each has its risks, benefits, and pitfalls.⁵³

Symptoms and physical findings are as unreliable in a recurrent episode as they are in a first episode.

Duplex ultrasonography is the test most often used in diagnosing recurrent DVT, as it is for primary DVT. The sensitivity depends somewhat on the experience of the examiner. Criteria for the diagnosis of recurrent DVT are:

- A thrombus in a segment of vein that was previously clear, or

Lack of physical signs does not reliably exclude DVT

- Enlargement of a thrombus by more than 2 mm,⁵⁴ or
- A change in the echogenicity of the existing thrombus.¹⁸

Venography can establish the diagnosis by showing a new, acute venous filling defect.

Impedance plethysmography and I-125 fibrinogen scanning are rarely used.

Recurrent DVT:

Recommendations

- Because symptoms are unreliable, recurrences need to be documented by venous duplex ultrasonography or venography.
- Patients with recurrent disease may need prolonged or indefinite anticoagulation therapy.

REFERENCES

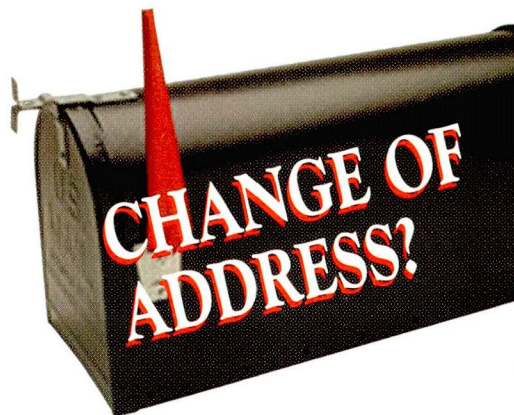1. Anderson FA Jr, Wheeler HB. Venous thromboembolism risk factors and prophylaxis. *Clin Chest Med* 1995; 16(2):235–251.
2. Baker WF Jr, Bick RL. Deep vein thrombosis diagnosis and management. *Med Clin North Am* 1994; 78(3):685–711.
3. Ginsberg JS. Management of venous thromboembolism. *N Engl J Med* 1996; 335:1816–1828.
4. Weinmann EE, Salzman EW. Deep vein thrombosis. *N Engl J Med* 1994; 331:1630–1641.
5. Prandoni P, Lensing AWA, Buller HR, et al. Deep-vein thrombosis and the incidence of subsequent symptomatic cancer. *N Engl J Med* 1992; 327:1128–1133.
6. Prins MH, Lensing AWA, Hirsh J. Idiopathic deep venous thrombosis. Is a search for malignant disease justified? *Arch Intern Med* 1994; 154:1310–1312.
7. Monreal M, Lafoz E, Casals A, et al. Occult cancer in patients with deep venous thrombosis. A systematic approach. *Cancer* 1991; 67:541–545.
8. Cornuz J, Pearson SD, Creager MA, et al. Importance of findings on the initial evaluation for cancer in patients with symptomatic idiopathic deep venous thrombosis. *Ann Intern Med* 1996; 125:785–793.
9. Prins MH, Hettiarachchi RJK, Lensing AWA, et al. Newly diagnosed malignancy in patients with venous thromboembolism. Search or wait and see. *Thromb Haemost* 1997; 78:121–125.
10. Shapiro S. Goals of screening. *Cancer* 1992; 70:1252–1258.
11. Sox HC Jr. Preventive health services in adults. *N Engl J Med* 1994; 330:1589–1595.
12. Schattner A, Kasher I, Berrebi A. Causes and outcome of deep-vein thrombosis in otherwise healthy patients under 50 years. *QJ Med* 1997; 90:283–287.
13. Ridker PM, Glynn RJ, Miletich JP, et al. Age-specific incidence rates of venous thromboembolism among heterozygous carriers of Factor V Leiden mutation. *Ann Intern Med* 1997; 126:528–531.
14. Solis MM, Ranval TJ, Nix ML, et al. Is anticoagulation indicated for asymptomatic postoperative calf vein thrombosis? *J Vasc Surg* 1992; 16:414–419.
15. Markel A, Manzo RA, Bergelin RO, et al. Pattern and distribution of thrombi in acute venous thrombosis. *Arch Surg* 1992; 127:305–309.

16. Krupski WC, Bass A, Dilley RB, et al. Propagation of deep venous thrombosis identified by duplex ultrasonography. *J Vasc Surg* 1990; 12:467–475.
17. Lohr JM, Kerr TM, Lutter KS, et al. Lower extremity calf thrombosis: To treat or not to treat? *J Vasc Surg* 1991; 14:618–623.
18. Lohr JM, Lames KV, Deshmukh RM, et al. Calf vein thrombi are not a benign finding. *Am J Surg* 1995; 170:86–90.
19. van Ramshorst B, van Bemmelen PS, Hoeneveld H, et al. Thrombus regression in deep venous thrombosis. Quantification of spontaneous thrombolysis with duplex scanning. *Circulation* 1992; 86:414–419.
20. Meissner MH, Caps MT, Bergelin RO, et al. Propagation, rethrombosis, and new thrombus formation after acute deep venous thrombosis. *J Vasc Surg* 1995; 22(5):558–567.
21. Sevitt S, Gallagher N. Venous thrombosis and pulmonary embolism. A clinico-pathological study in injured and burned patients. *Br J Surg* 1961; 48:475–489.
22. Giachino A. Relationship between deep-vein thrombosis in the calf and fatal pulmonary embolism. *Can J Surg* 1988; 31:129–130.
23. Havig O. Deep vein thrombosis and pulmonary embolism: An autopsy study with multiple regression analysis of possible risk factors. *Acta Chir Scand Suppl* 1997; 478:1–120.
24. Passman MA, Moreta GL, Taylor LM Jr. Pulmonary embolism is associated with the combination of isolated calf vein thrombosis and respiratory symptoms. *J Vasc Surg* 1997; 25:39–45.
25. Moreno-Cabral R, Kistner RL, Nordyke RA. Importance of calf vein thrombophlebitis. *Surgery* 1976; 80:735–742.
26. Becker DM, Philbrick JT, Walker FB IV. Axillary and subclavian venous thrombosis. Prognosis and treatment. *Arch Intern Med* 1991; 151:1934–1943.
27. Prandoni P, Polistena P, Bernardi E, et al. Upper-extremity deep vein thrombosis. Risk factors, diagnosis, and complications. *Arch Intern Med* 1997; 157:57–62.
28. Hingorani A, Ascher E, Hanson J, et al. Upper extremity versus lower extremity deep venous thrombosis. *Am J Surg* 1997; 174:214–217.
29. Hingorani A, Ascher E, Lorenson E, et al. Upper extremity deep venous thrombosis and its impact on morbidity and mortality rates in a hospital-based population. *J Vasc Surg* 1997; 26:853–860.
30. AbuRahma AF, Sadler D, Stuart P, et al. Conventional versus thrombolytic therapy in spontaneous (effort) axillary-subclavian vein thrombosis. *Am J Surg* 1991; 161:459–465.
31. Machleder HI. Evaluation of a new treatment strategy for Paget-Schroetter syndrome: Spontaneous thrombosis of the axillary-subclavian vein. *J Vasc Surg* 1993; 17:305–317.
32. Ascer E, Gennaro M, Lorensen E, et al. Superior vena caval Greenfield filters: Indications, techniques, and results. *J Vasc Surg* 1996; 23:498–503.
33. Lensing AW, Prins MH, Davidson BL, et al. Treatment of deep venous thrombosis with low-molecular-weight heparins. A meta-analysis. *Arch Intern Med* 1995; 155:601–607.
34. Levine M, Gent M, Hirsh J, et al. A comparison of low-molecular-weight heparin administered primarily at home with unfractionated heparin administered in the hospital for proximal deep-vein thrombosis. *N Engl J Med* 1996; 334:677–681.
35. Koopman MMW, Prandoni P, Piovello F, et al. Treatment of venous thrombosis with intravenous unfractionated heparin administered in the hospital as compared with subcutaneous low molecular-weight heparin administered at home. *N Engl J Med* 1996; 334:682–687.
36. The Columbus Investigators. Low-molecular-weight heparin in the treatment of patients with venous thromboembolism. *N Engl J Med* 1997; 337:657–662.



37. Simonneau G, Sors H, Charbonnier B, et al. A comparison of low-molecular-weight heparin with unfractionated heparin for acute pulmonary embolism. *N Engl J Med* 1997; 337:663-669.
38. Bjarnason H, Kruse JR, Asinger DA, et al. Iliofemoral deep venous thrombosis: Safety and efficacy outcome during 5 years of catheter-directed thrombolytic therapy. *J Vasc Interv Radiol* 1997; 8:405-418.
39. Semba CP, Dake MD. Iliofemoral deep venous thrombosis: Aggressive therapy with catheter-directed thrombolysis. *Radiology* 1994; 191:487-494.
40. Prandoni P, Lensing AWA, Cogo A, et al. The long-term clinical course of acute deep venous thrombosis. *Ann Intern Med* 1996; 125:1-7.
41. Johnson BF, Manzo RA, Bergelin RO, et al. Relationship between changes in the deep venous system and the development of the postthrombotic syndrome after an acute episode of lower limb deep vein thrombosis: A one- to six-year follow-up. *J Vasc Surg* 1995; 21:307-313.
42. Bergqvist D, Jendteg S, Johansen L, et al. Cost of long-term complications of deep venous thrombosis of the lower extremities: An analysis of a defined patient population in Sweden. *Ann Intern Med* 1997; 126:454-457.
43. Beyth RJ, Cohen AM, Landefeld S. Long-term outcomes of deep-vein thrombosis. *Arch Intern Med* 1995; 155:1031-1037.
44. Arnesen H, Hoiseth A, Ly B. Streptokinase or heparin in the treatment of deep vein thrombosis. *Acta Med Scand* 1982; 211:65-68.
45. Becker DM, Philbrick JT, Selby JB. Inferior vena cava filters. Indications, safety, effectiveness. *Arch Intern Med* 1992; 152:1985-1994.
46. Decousus H, Leizorovicz A, Parent F, et al. A clinical trial of vena caval filters in the prevention of pulmonary embolism in patients with proximal deep-vein thrombosis. *N Engl J Med* 1998; 338:409-415.
47. Brandjes DPM, Buller HR, Heijboer H, et al. Randomised trial of effect of compression stockings in patients with symptomatic proximal-vein thrombosis. *Lancet* 1997; 349:759-762.
48. Research Committee of the British Thoracic Society. Optimum duration of anticoagulation for deep-vein thrombosis and pulmonary embolism. *Lancet* 1992; 340:873-876.
49. Schulman S, Rhedin A, Lindmarker P, et al. A comparison of six weeks with six months of oral anticoagulant therapy after a first episode of venous thromboembolism. *N Engl J Med* 1995; 332:1661-1665.
50. Schulman S, Granovist S, Holmstrom M, et al. The duration of oral anticoagulant therapy after a second episode of venous thromboembolism. *N Engl J Med* 1997; 336:393-398.
51. Landefeld CS, Cook EF, Flatley M, et al. Identification and preliminary validation of predictors of major bleeding in hospitalized patients starting anticoagulant therapy. *Am J Med* 1987; 82:703-713.
52. Landefeld CS, McGuire III BS, Rosenblatt BS. A bleeding risk index for estimating the probability of major bleeding in hospitalized patients starting anticoagulant therapy. *Am J Med* 1990; 89:569-578.
53. Koopman MMW, Buller HR, ten Cate JW. Diagnosis of recurrent deep vein thrombosis. *Haemostasis* 1995; 25:49-57.
54. Prandoni P, Cogo A, Bernardi E, et al. A simple ultrasound approach for detection of recurrent proximal-vein thrombus. *Circulation* 1993; 88[part 1]:1730-1735.

ADDRESS: Bernardo B. Fernandez, Jr., MD, Department of Vascular Medicine, Cleveland Clinic Florida, 3000 West Cypress Creek Road, Ft. Lauderdale, FL 33309-1743.



The *Cleveland Clinic Journal of Medicine* uses the AMA's database of physician names and addresses. (All physicians are included in the AMA database, not just members of the AMA.) Only the AMA can update this data, and will accept a change-of-address notice only from you.

Be sure your primary specialty and type of practice also are up-to-date on AMA records. This information is important in determining who receives the *Cleveland Clinic Journal of Medicine*.

If you have ever notified the AMA that you did not want to receive mail, you will not receive the *Cleveland Clinic Journal of Medicine*. You can reverse that directive by notifying the AMA. Please note that a change of address with the AMA will redirect all medically related mailings to the new location.

FOR FASTER SERVICE

- PHONE 312-464-5192
- FAX 312-464-5827
- E-MAIL nicole_neal@www.ama-assn.org

or send a recent mailing label along with new information to:

AMA
DEPARTMENT OF DATA SERVICES
515 North State Street
Chicago, IL 60610

NEW INFORMATION

NAME _____

STREET ADDRESS _____

CITY _____

STATE _____ ZIP _____

Please allow 6 to 8 weeks for change to take effect