

**XIAN WEN JIN, MD, PhD**

Department of General Internal  
Medicine, Cleveland Clinic

**JOSEPH CASH, MD\***

Chairman, Department of General  
Internal Medicine, Cleveland Clinic  
\*Deceased

**ALEXANDER W. KENNEDY, MD**

Cancer Center and Department of Gynecology  
and Obstetrics, Cleveland Clinic

# Human papillomavirus typing and the reduction of cervical cancer risk

## ■ ABSTRACT

Minor cervical cytologic abnormalities are common, but knowing which low-grade lesions will progress to cervical cancer—and therefore deserve biopsy and excision—is difficult. Since some human papillomavirus (HPV) types are strongly associated with cervical cancer, HPV typing may be a means of determining which patients with minor abnormalities require biopsy and treatment and which need only follow-up smears. This paper reviews the association between cervical cancer and HPV infection, the pathogenesis of HPV infection, the utility of HPV typing in triaging patients with a diagnosis of atypical squamous cells of undetermined significance, and the prospects for the development of an HPV vaccine.

## ■ KEY POINTS

Invasive squamous cell carcinoma of the cervix usually develops from precancerous cervical lesions and is strongly associated with HPV infection.

HPV types 16 and 18 are associated with a substantially higher risk of cervical cancer. HPV types that carry a moderate risk include types 31, 33, 35, 39, 45, 51, and 52. HPV types 6 and 11 are associated with lower risk.

HPV typing can be used in the management of women with minor Pap smear abnormalities: eg, women with atypical squamous cells of undetermined significance who test positive for high-oncogenic-risk HPV types are referred for colposcopic biopsy and excision.

A vaccine that could prevent HPV infection could also prevent its malignant sequelae.

**M**INOR ABNORMALITIES on the Papanicolaou smear are quite common, yet questions remain about the best management of these patients. Knowing which minor lesions are likely to progress to cancer in situ or invasive cervical cancer would greatly facilitate management decisions for select patients.

Because experimental and clinical studies closely link certain types of human papillomavirus (HPV) with the development of cervical cancer, experts believe that testing cytologic specimens for HPV types with high oncogenic potential can be used to guide the clinical management of many patients with minor abnormalities, and can help to reduce the incidence and consequences of cervical cancer.

This article briefly summarizes the following issues:

- The association between cervical cancer and HPV
- The molecular pathogenesis of HPV infection
- Pluses and minuses of HPV typing to screen women with minor Pap smear abnormalities
- Prospects for an HPV vaccine.

## ■ PAP SCREENING AND THE REDUCTION OF CERVICAL CANCER RISK

Cervical cancer is the second-leading cause of death from cancer in women worldwide, with approximately 500,000 deaths annually.<sup>1</sup> In 1995, 15,800 new cases of invasive cervical cancer and 4,800 deaths attributable to cervical cancer were reported in the United States.<sup>2</sup>

Although its incidence in the general population is relatively low, it is a major pub-

lic health problem due to the enormous resources expended for preventing, diagnosing, and managing cervical neoplasia.

Wherever screening programs are scarce and the prevalence of risk factors is high, the frequency of cervical cancer increases. This is especially true in underdeveloped countries: the incidence is high in Africa, Central and South America, and Southeast Asia. But this situation is also seen in developed countries. For example, the incidence among African American women is almost three times that of white Americans.

### **Evidence of lesion progression to invasive cancer**

Typically, invasive cervical cancer develops from precancerous squamous intraepithelial lesions of the cervix. Low-grade squamous intraepithelial lesions usually do not progress to more severe lesions, whereas high-grade squamous intraepithelial lesions (formerly called cervical intraepithelial neoplasia, or CIN, CIN II, and CIN III) are substantially more likely to progress to carcinoma in situ and, eventually, to invasive cervical cancer.

The average age of patients with invasive cervical cancer is 51.4 years. This is 15 to 25 years past the average age of patients with high-grade squamous intraepithelial lesions and 8 years past the average age of patients with microinvasive cervical cancer,<sup>1</sup> an observation that supports the hypothesis that high-grade squamous intraepithelial lesions progress to microinvasive lesions and finally to invasive cancer.

In addition to this evidence, the entire spectrum from precancerous change to invasive cancer can often be seen in the same surgical specimen. (Interestingly, a minority of squamous cell carcinomas apparently do not develop by this mechanism, yet may evolve rapidly without a documented precancerous phase.<sup>1</sup>)

### **Efficacy of detecting precancerous cervical lesions**

Over the past several decades, cytologic screening using Pap smears has improved the detection of precancerous cervical lesions. Its use in the United States is directly correlated with a decrease in invasive cervical cancer, as well as a decrease in mortality from cervical

cancer.<sup>1</sup> At the same time however, the need for colposcopy and cervical biopsy for women with equivocal Pap smear findings also increased financial costs of cervical cancer screening programs and overwhelmed gynecology colposcopy services.

### **HPV: THE MOST SIGNIFICANT RISK FACTOR FOR CERVICAL CANCER**

HPV is a group of small DNA viruses that induce epidermal and mucosal papillomas—genital warts—in humans. The association of HPV with cervical cancer is strongly supported by epidemiologic, histologic, immunologic, and molecular biological studies.

### **Linking sexually transmitted disease to cervical cancer**

Numerous early epidemiologic studies implicate sexually transmitted HPV infection in the etiology of cervical cancer and its precursor lesions.<sup>3</sup> A large case-control study of HPV and cervical intraepithelial neoplasia conducted by the National Cancer Institute<sup>4</sup> evaluated whether sexual behavior and other risk factors for squamous intraepithelial neoplasia influence risk primarily via HPV infection. Investigators compared 500 women with cervical intraepithelial neoplasia and 500 control subjects and found that 76% of cases of cervical intraepithelial neoplasia could be attributed to HPV infection.<sup>4</sup> The case subjects demonstrated the typical epidemiologic profile of cervical intraepithelial neoplasia: more sex partners, earlier age at first sexual intercourse, and lower socioeconomic status than control subjects.

### **Additional evidence**

Histologically, squamous intraepithelial lesions display characteristic pathologic features of HPV infection, such as epithelial hyperplasia (acanthosis) and degenerative cytoplasmic vacuolization (koilocytosis) in terminally differentiated keratinocytes with atypical nuclei.<sup>5</sup>

Electron-microscopic studies also demonstrate HPV particles in these lesions.<sup>6</sup> HPV infection was identified in surgical pathology specimens by positive immunoperoxidase staining with antiserum that specifically

**Epidemiologic and histologic studies link HPV with cervical cancer**



## How human papillomavirus may cause cervical cancer

**H**PVs PLAY A CENTRAL ROLE in the pathogenesis of cervical cancer. To date, more than 70 types of HPV have been identified. Certain HPV types (eg, 16 and 18) are associated with a substantially higher risk of cervical cancer than other HPV types (eg, 6 and 11).<sup>3</sup> HPVs that carry a moderate risk of cervical cancer include types 31, 33, 35, 39, 45, 51, and 52.<sup>11</sup>

### A MODEL OF MOLECULAR PATHOGENESIS OF HPV ONCOGENICITY

Advances in molecular biology over the past 10 years have provided insight into the molecular pathogenesis of HPV-related cervical neoplasia. Infection of human epithelial cells by high-risk HPV types produces *in vitro* immortalization. This provides direct experimental evidence of HPV oncogenicity. Furthermore, *in vitro* transformation studies show that two HPV viral gene products, E6 and E7, are necessary for immortalization.<sup>12</sup> However, E6 and E7 produced by the low-risk HPV types 6 and 11 are either inactive or only weakly transforming in a similar transformation assay.<sup>11</sup> This phenomenon may explain why low-risk HPV-related cervical lesions rarely progress to invasive cancer.

The oncogenicity of HPV E6 and E7 proteins was further demonstrated in transgenic mice: when E6 and E7 of high-risk HPV types 16 and 18 were introduced into mouse embryos, the mice developed progressive squa-

mous epithelial neoplasia.<sup>13,14</sup>

Functional studies of HPV proteins provide insight into the mechanism of oncogenicity. High-risk HPV E6 proteins were found to form complexes with cellular tumor suppressor protein p53, causing its rapid degradation.<sup>15</sup> The decreased level of p53 proteins diminishes the gene's ability to suppress tumor growth and leads to unchecked cell growth. The low-risk HPV E6 proteins do not bind p53 at detectable levels and have no effect on p53 stability *in vitro*.<sup>16</sup>

The high-risk HPV E7 protein binds to another cellular tumor suppressor, retinoblastoma gene product pRB.<sup>17</sup> The binding of E7 to pRB disrupts the complex between the cellular transcription factor E2F-1 and pRB. This results in the release of E2F-1, allowing it to stimulate cellular DNA synthesis and uncontrolled cell growth. The E7 protein from low-risk HPV types 6 and 11 binds pRB with decreased affinity.

The fact that high-risk HPV E6 can inactivate tumor suppressor p53 and E7 can inactivate pRB provides important insight into HPV oncogenesis at the molecular level. It appears to be a very attractive model for the molecular pathogenesis of HPV-related cervical carcinoma. Furthermore, the inability of low-risk HPV E6 and E7 proteins to inactivate or bind to tumor suppressors may in part explain why cervical lesions associated with HPV-6 and HPV-11 rarely progress to invasive cancer.<sup>11</sup>

detected HPV structural antigens.<sup>7</sup> By using this antiserum, it was demonstrated that approximately 50% of patients with condylo-ma and low-grade cervical dysplasia have HPV-specific antigens.

Multicenter studies from 22 countries have shown that in over 90% of invasive cervical cancer specimens, HPV DNA can be detected by molecular techniques.<sup>8</sup> HPV DNA was isolated from metastatic cervical cancer tissues, as well as from *in vitro* tumor cell lines established from cervical cancers.<sup>9,10</sup>

This compelling evidence demonstrates

that HPV is the most significant risk factor for cervical cancer. As a result of these studies, researchers have now developed a hypothetical model for the molecular pathogenesis of HPV-related cervical cancer (see above).

### ■ THE BETHESDA SYSTEM FOR CLASSIFYING CERVICAL NEOPLASIA

The current classification system for cervical cytology, the Bethesda system (TABLE 1), developed and periodically revised by the National Cancer Institute,<sup>18</sup> combines some former

detected HPV structural antigens.<sup>7</sup> By using this antiserum, it was demonstrated that approximately 50% of patients with condylo-ma and low-grade cervical dysplasia have HPV-specific antigens.

Multicenter studies from 22 countries have shown that in over 90% of invasive cervical cancer specimens, HPV DNA can be detected by molecular techniques.<sup>8</sup> HPV DNA was isolated from metastatic cervical cancer tissues, as well as from *in vitro* tumor cell lines established from cervical cancers.<sup>9,10</sup>

This compelling evidence demonstrates

TABLE 1

### Comparison of different classification systems for cervical dysplasia

TYPE OF DYSPLASIA	CIN (CERVICAL INTRAEPITHELIAL NEOPLASIA) SYSTEM	BETHESDA SYSTEM
Squamous atypia	Atypical cells	Atypical squamous cells of undetermined significance (ASCUS)
Mild dysplasia	CIN I	Low-grade squamous intraepithelial lesions (LGSIL)
Moderate dysplasia	CIN II	High-grade squamous intraepithelial lesions (HGSIL)
Severe dysplasia	CIN III	HGSIL
Carcinoma in situ	CIN III	HGSIL
Carcinoma	Carcinoma	Carcinoma

SOURCE: ADAPTED FROM AMERICAN SOCIETY FOR COLPOSCOPY AND CERVICAL PATHOLOGY PRACTICE GUIDELINE, 1996.

classifications and creates a borderline category, ie, atypical squamous cells of undetermined significance (ASCUS).

The Bethesda system classifies squamous cell abnormalities into four categories:

- ASCUS
- Low-grade squamous intraepithelial lesion
- High-grade squamous intraepithelial lesion
- Cancer.

Low-grade lesions now include mild cervical intraepithelial neoplasia and other HPV-associated lesions previously reported as "condylomatous" or "koilocytotic atypia." High-grade lesions encompass moderate and severe cervical intraepithelial dysplasia and carcinoma in situ. ASCUS is defined as cellular abnormalities that are more marked than those attributable to reactive changes but that quantitatively or qualitatively fall short of a definitive diagnosis of a squamous intraepithelial lesion.

The criteria for the diagnosis of ASCUS include nuclear enlargement two and a half to three times that of a normal intermediate squamous cell nucleus, with a slight increase in the nuclear-cytoplasmic ratio. Mild hyperchromasia may be present, but chromatin remains evenly distributed without granularity.

The category of ASCUS has created a

major clinical dilemma, with 2 to 3 million women given a diagnosis that generates uncertainty each year. This results in increased utilization of costly and limited colposcopy services.

#### ■ IS HPV TYPING USEFUL IN THE TRIAGE OF WOMEN WITH MINOR PAP SMEAR ABNORMALITIES?

The best screening method for patients with ASCUS and low-grade lesions remains controversial, but clinicians may choose to follow established interim guidelines.<sup>19</sup>

#### Current management of ASCUS

Generally, the rate of ASCUS in a screened population should be no more than two to three times the rate of squamous intraepithelial lesions. Depending on the population screened, this may be up to 10% of patients screened in a sexually transmitted disease clinic. At the Cleveland Clinic, the ASCUS rate is 4%. According to one estimate, of 50 million Pap tests performed annually in the United States, approximately 2.5 million show these minor abnormalities.<sup>19</sup> The associated cost of colposcopic evaluation of these lesions approaches \$6 billion annually.

Current management options<sup>19</sup> for patients with ASCUS, depending on the

**HPV is the most significant risk factor for cervical cancer**



## The role of HPV testing in the clinical management of atypical squamous cells of undetermined significance (ASCUS)

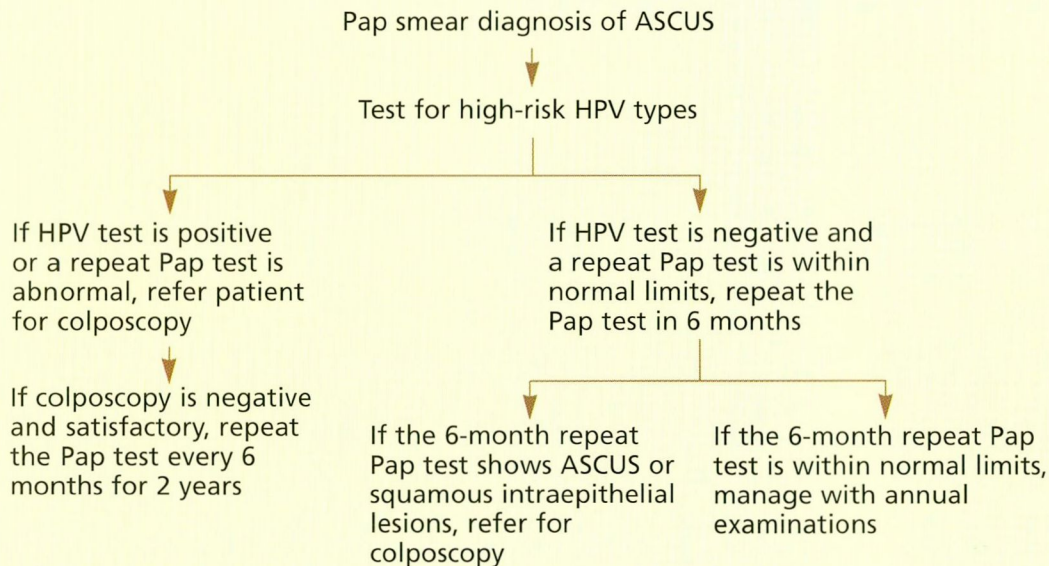


FIGURE 1

qualifications on the laboratory report, include the following different options:

- Follow-up Pap testing without colposcopy
- Colposcopy, endocervical curettage, and directed biopsy
- Ancillary screening techniques such as HPV typing and cervicography to help identify low-risk and high-risk patients.<sup>19</sup>

### Current management of low-grade squamous intraepithelial lesions

Most cytology specimens classified as low-grade squamous intraepithelial lesions represent benign processes that do not require treatment. However, some of these patients either have or will develop precancerous lesions, and the management options are generally the same as for ASCUS and must be selected on the basis of the merits of the individual case.<sup>19</sup>

However, the potential of low-grade squamous intraepithelial lesions to persist or progress to high-grade lesions depends mainly on the association with specific types of HPV. Low-grade lesions are usually associated with low-risk HPV types (6, 11, 42, 43, and 44) and

are less likely to develop into invasive cancer. On the other hand, lesions associated with moderate-risk and high-risk HPV types (16, 18, 31, 33, 35, 39, 45, 51, and 52) are more likely to progress to cancer. Thus, HPV typing represents an additional option for triaging patients with Pap smears indicative of ASCUS and low-grade squamous intraepithelial lesions.<sup>19</sup>

### ■ A BRIEF DESCRIPTION OF CURRENT HPV TESTING METHODS

The principle of HPV testing relies on the detection of viral DNA in cervical cytology specimens. Currently, a “hybrid capture” method is used for HPV testing. This method uses an RNA probe that binds to HPV DNA, creating a hybrid that can be captured by immobilized antibodies.<sup>20</sup>

Several studies have shown that hybrid capture systems have excellent sensitivity and specificity.<sup>20,21</sup> In contrast, DNA amplification methods such as polymerase chain reaction are prone to inhibitory substances that interfere with amplification and are associated with high false-negative rates. With

**Management of ASCUS includes Pap tests, colposcopic biopsy and treatment, and HPV typing**

the hybrid capture system, false-positive results are usually not of concern, but specimen adequacy is critical to avoid false-negative results.

#### Importance of obtaining a good specimen

Inadequate cervical sampling affects the accuracy of HPV typing. Thorough sampling of the cervical transformation zone is essential. Proper sampling of the endocervix, particularly in postmenopausal women, is important to improve cytologic screening results. Endocervical nylon brushes—not cotton or Dacron swabs—should always be employed for obtaining cervical Pap smears.

After obtaining the sample, the brush or spatula should be fixed immediately to avoid air drying of the artifact. If fluid-based cytologic examination is to be used, the specimens should be immersed immediately in transport medium at room temperature to preserve cells for monolayer Pap smear preparation and subsequent HPV testing.

#### HPV typing at the Cleveland Clinic

HPV typing is currently used as a triage option in the Cleveland Clinic Department of Gynecology according to the algorithm in **FIGURE 1**. According to the current protocol, only women with ASCUS who test positive for high-oncogenic-risk HPV DNA are referred for colposcopy. In women negative for high-risk or moderate-risk HPV types, colposcopy is deferred and Pap smears are repeated every 6 months as long as they indicate ASCUS.

In addition to HPV typing, several other management options are available for women with a Pap smear report of ASCUS or low-grade squamous intraepithelial lesions according to the current guidelines from The National Cancer Institute.<sup>19</sup> Patients with HPV-negative persistent ASCUS in repeat Pap smears should be referred for colposcopic evaluation after treatment of inflammation, infection, or atrophy. For women with a diagnosis of ASCUS associated with sexually transmitted diseases such as *Chlamydia*, gonorrheal cervicitis, *Candida*, or *Trichomonas* vaginitis, Pap testing should be repeated after specific therapy is completed. In postmenopausal women who are not on hormone replacement therapy and have a diagnosis of

ASCUS, atrophic cells with a high nuclear-cytoplasmic ratio may suggest a neoplastic process. A course of topical estrogen treatment with Premarin cream (0.625 mg/g, 1 g at bedtime for 14 days) often helps in the differential diagnosis. Pap testing should be repeated 14 days after the completion of the treatment. If the repeat Pap smear is still equivocal after estrogen treatment, patients should be referred for colposcopy.

For patients with ASCUS and a previously abnormal Pap test, or those not likely to be compliant with follow-up, consider colposcopy. For patients with low-grade squamous intraepithelial lesions, screening colposcopy is recommended initially, and then the patients are followed with repeat Pap smears. If a subsequent smear reveals a lesion more advanced than low-grade squamous intraepithelial lesions, repeat colposcopy with directed biopsy is recommended.

#### ■ COULD AN HPV VACCINE PREVENT CERVICAL CANCER?

Studies of potential HPV vaccines have shown promising results. In animal models, data suggest that prophylactic vaccination with papillomavirus can result in protective immunity. Calves immunized with bovine papillomavirus wart extract are protected against bovine papillomavirus infection. Increasing titers of neutralizing antibodies against conformational epitopes on the viral surface were detected in calf serum.<sup>22</sup> This finding suggests that any recombinant HPV vaccine, to be effective, would have to preserve the tertiary protein structure of the viral conformational epitopes.

Of interest, recombinantly expressed HPV L1 major capsid protein has been shown to self-assemble into viruslike particles and to be highly immunogenic.<sup>23</sup> Immunization with recombinantly expressed canine oral papillomavirus major capsid protein L1 completely prevents the development of viral mucosal papillomas in dogs.<sup>24</sup>


These data strongly suggest the potential of HPV L1 protein-based recombinant subunit vaccine for prevention of HPV infection and its malignant sequelae. Researchers estimate that vaccine against HPV 16 alone could save

**To obtain a good specimen, sample the cervical transformation zone thoroughly**



the lives of 225,000 women per year worldwide.<sup>24</sup> However, no HPV vaccines are currently available due to several difficulties. First, there is no *in vitro* source of intact HPV. Second, HPV is highly species-specific, and it is impossible to use animals to evaluate HPV vaccine efficacy in humans. Third, many HPV types that infect the genital tract pose a particular challenge in the development of recombinant vaccines. Since the epitopes expressed by recombinant viruslike particles are type-specific and mimic native viral epi-

topes, it is expected that a multivalent vaccine containing viruslike particles from many HPV types will be required to provide protection from infection.

Additional animal models and clinical trials are needed to determine the host immune response and the ability of HPV major capsid protein to induce protective antibodies in humans. The development of an effective HPV vaccine could protect humans from HPV infection and HPV-related cervical cancer in the future. 

## REFERENCES

1. Wright TC, Ferenczy A, Kurman RJ. Carcinoma and other tumors of the cervix. In: Kurman RJ, editor. Pathology of the female genital tract. 4th ed. New York: Springer-Verlag; 1994:279-326.
2. Cannistra SA, Niloff JM. Cancer of the uterine cervix. *N Engl J Med*. 1995; 334:1030-1038.
3. zur Hausen H. Human papillomaviruses and their possible role in squamous carcinoma. *Curr Top Microbiol Immunol* 1977; 78:1-30.
4. Schiffman MH, Bauer HM, Hoover RN, et al. Epidemiologic evidence showing that human papillomavirus infection causes most cervical intraepithelial neoplasia. *J Natl Cancer Inst* 1993; 85:958-964.
5. Ferenczy A, Jenson AB. Tissue effects and host response. The key to the rational triage of cervical neoplasia. *Obst Gynecol Clin North Am* 1996; 23(4):759-782.
6. Meisels A, Roy M, Fortier M, et al. Human papillomavirus infection of the cervix: the atypical condyloma. *Acta Cytol* 1981; 25:7-16.
7. Jenson AB, Rosenthal JR, Olsen C, Pass F, Lancaster WD, Shah K. Immunological relatedness of papillomaviruses from different species. *J Natl Cancer Inst* 1980; 64:495-500.
8. Bosch FX, Manos MM, Munoz N, et al, and the IBSCC Study Group. Prevalence of HPV DNA in cervical cancer in 22 countries. *J Natl Cancer Inst* 1995; 87:796-802.
9. Lancaster WD, Castellano C, Santos C, Kurman RJ, Jensen AB. Human papillomavirus deoxyribonucleic acid in cervical carcinoma from primary and metastatic sites. *Am J Obstet Gynecol* 1986; 154:115-119.
10. Boshast M, Gissman L, Ikenberg H. A new type of papillomavirus DNA, its presence in genital cancer biopsies and in cell lines derived from cervical cancer. *EMBO J* 1984; 3:1151-1157.
11. Scheffner M, Romanczuk H, Munger K, Huibregtse JM, Miettinen JA, Howley PM. Functions of human papillomavirus proteins. *Curr Topics Microbiol Immunol* 1994; 186:83-99.
12. zur Hausen H, de Villiers EM. Human papillomaviruses. *Ann Rev Microbiol* 1994; 48:427-447.
13. Arbeit JM, Munger K, Howley PM, Hanahan D. Progressive squamous epithelial neoplasia in K14-human papillomavirus type 16 transgenic mice. *J Virol* 1994; 68:4358-4368.
14. Greenhalgh DA, Wang XJ, Rothnagel JA, et al. Transgenic mice expressing targeted HPV-18 E6 and E7 oncogenes in the epidermis develop verrucous lesions and spontaneous, rasHa-activated papillomas. *Cell Growth Differ* 1994; 5:667-675.
15. Werness BA, Levine AJ, Howley PM. Association of human papillomavirus type 16 and 18 E6 proteins with p53. *Science* 1990; 248:76-79.
16. Scheffner M, Werness BA, Huibregtse JM, Levine AJ, Howley PM. The E6 oncoprotein encoded by human papillomavirus type 16 and 18 promotes the degradation of p53. *Cell* 1990; 63:1129-1136.
17. Munger K, Werness BA, Dyson N, Phelps WC, Haslow E, Howley PM. Complex formation of human papillomavirus E7 proteins with the retinoblastoma tumor suppressor gene product. *EMBO J* 1989; 8:4099-4105.
18. Kurman RJ, Solomon D, editors. The Bethesda system for reporting cervical/vaginal cytologic diagnoses: definitions, criteria, and explanatory notes for terminology and specimen adequacy. New York: Springer-Verlag, 1994.
19. Kurman RJ, Henson DE, Herbst AL, Noeller KL, Schiffman MH. Interim guidelines for management of abnormal cervical cytology. The 1992 National Cancer Institute Workshop. *JAMA* 1994; 271:1866-1969.
20. Lorincz AT. Molecular methods for the detection of human papillomavirus infection. *Obst Gynecol Clin North Am* 1996; 23(3):707-730.
21. Cox JT, Lorincz AT, Schiffman MH, Sherman ME, Cullen A, Kurman RJ. Human papillomavirus testing by hybrid capture appears to be useful in triaging women with a cytologic diagnosis of atypical squamous cells of undetermined significance. *Am J Obstet Gynecol* 1995; 172:946-954.
22. Jarnett WF, O'Neil BW, Gaukroger JM, Laird HM, Smith KT, Campo MS. Studies on vaccination against papillomaviruses: A comparison of purified virus, tumor extract and transformed cells in prophylactic vaccination. *Vet Rec* 1990; 126:449-452.
23. Kirubauer R, Booy F, Cheng NF, Lowry DR, Schiller JT. Papillomavirus L1 major capsid protein self-assembles into viruslike particles that are highly immunogenic. *Proc Natl Acad Sci USA* 1992; 89:12180-12184.
24. Suzich JA, Ghim SJ, Palmer-Hill FJ, et al. Systemic immunization with papillomavirus L1 protein completely prevents the development of viral mucosal papillomas. *Proc Natl Acad Sci USA*. 1991; 92:1153-1157.

**ADDRESS:** Xian Wen Jin, MD, PhD, Department of General Internal Medicine, S70, The Cleveland Clinic Foundation, 9500 Euclid Avenue, Cleveland, OH 44195, e-mail [jinx@ccf.org](mailto:jinx@ccf.org).

**Women with ASCUS and a high-risk HPV type should undergo colposcopy**