



## Generalized rash follows ankle ulceration

After being treated for venous insufficiency and malleolus ulceration, this patient woke up covered in itchy, painful plaques. What was the connection between the 2?

A 31-YEAR-OLD INCARCERATED MAN sought care for one crusted ulcer and one adjacent open ulcer with granulation tissue on his left malleolus. The ulcers were caused by chronic venous insufficiency—the result of previous trauma to the ankle. Concerned that the ulcers would become infected, the physician prescribed one double-strength tablet twice a day of trimethoprim-sulfamethoxazole (TMP-SMX). The patient took 2 doses of the antibiotic and one dose of naproxen.

When the patient awoke the next morning, he had a generalized skin eruption on his chin, trunk, buttocks, glans penis, and extremities (FIGURE). The rash began as red edematous plaques that became itchy and painful with dark, violaceous dusky centers surrounded by redness. The patient was treated with topical hydrocortisone 2.5% twice a day and oral diphenhydramine 25 mg followed by 50 mg, but the rash didn't improve.

The patient was transported to the local emergency department where physicians noted that the patient had about 30 to 40 well-demarcated papules and plaques of various sizes that were haphazardly located over the patient's chin, chest, back, upper and lower extremities, and genitalia. There was one lesion on the chest with central vesiculation. There were no lesions on the mucous membranes of his eyes, ears, nose, mouth, or anus.

The patient, whose vital signs were within normal limits, was empirically treated with one dose of methylprednisolone (125 mg intravenous [IV]) and started on IV piperacil-

lin-tazobactam and vancomycin. Lab work revealed no elevation in his white blood cell count, creatinine, liver function enzymes, or C-reactive protein.

The patient subsequently revealed that he'd had a similar experience a year earlier after being treated with TMP-SMX for cellulitis. He noted that during the previous episode, the lesions were located on the exact same areas of his glans penis and chin.

- WHAT IS YOUR DIAGNOSIS?
- HOW WOULD YOU TREAT THIS PATIENT?

### FIGURE

Itchy plaques with edematous, dark centers, surrounding redness

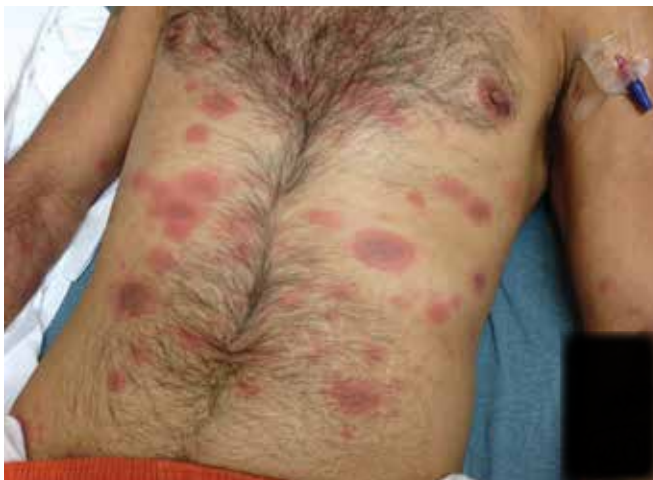

IMAGE COURTESY OF UNIVERSITY OF TEXAS HEALTH SCIENCE CENTER AT SAN ANTONIO

Jackie Bucher, MD; Sahand Rahnama-Moghadam, MD; Sandra Osswald, MD  
University of Texas Health Science Center at San Antonio

[bucher@uthscsa.edu](mailto:bucher@uthscsa.edu)

### DEPARTMENT EDITOR

Richard P. Usatine, MD  
University of Texas Health Science Center at San Antonio

The authors reported no potential conflict of interest relevant to this article.

**Diagnosis:**  
**Disseminated fixed-drug eruption**

The diagnosis was based on the morphologic characteristics of the eruption and the patient's history of similar lesions that appeared in the exact same initial locations (chin and glans penis) following previous treatment with TMP-SMX.

A fixed-drug eruption is an adverse cutaneous reaction to a drug that is defined by a dusky red or violaceous macule, which evolves into a patch, and eventually, an edematous plaque. Fixed-drug eruptions are typically solitary, but may be generalized (as was the case with our patient).

■ **The pathophysiology of the disease** involves resident intra-epidermal CD8+ T-cells resembling effector memory T-cells. These T-cells are increased in number at the dermoepidermal junction of normal appearing skin; their aberrant activation leads to an inflammatory response, stimulating tissue destruction and formation of the classic fixed-drug lesion.<sup>1</sup>

The diagnosis is usually made based on a history of similar lesions recurring at the same location in response to a specific drug<sup>2</sup> and the classic physical exam findings of well-demarcated, edematous, and violaceous plaques. To confirm a fixed-drug eruption in the case of clinical equipoise, a skin biopsy may be performed.

Classic histologic findings of a fixed-drug eruption include:

- band-like lichenoid lymphocytic infiltrates with vacuolar changes at the dermoepidermal junction,
- mixed cellular infiltrates, including eosinophils, throughout the dermis and occasional superficial and deep mixed cellular perivascular infiltrates, and
- abundant melanophages suggesting pigment incontinence.

There are several reports of similar TMP-SMX-induced generalized fixed-drug eruptions in the literature.<sup>3</sup> One study of 64 cases of fixed-drug eruption found that TMP-SMX was the most common offender, causing 75% of fixed-drug eruption cases; naproxen sodium came in second with 12.5%.<sup>3</sup> Other common culprits include the antipyretic metamizole

and other pyrazolone derivatives such as tetracycline, metronidazole, ciprofloxacin, and phenytoin sodium.<sup>4</sup> There is evidence supporting a correlation between the offending drug and the subsequent site of reaction; TMP-SMX is associated with mucosal junction and genital involvement.<sup>4,5</sup> This finding may aid physicians in the investigation of provoking agents.

**Distinguish fixed-drug eruptions from serious bullous diseases**

Fixed-drug eruptions occasionally exhibit bullae and erosions and must be differentiated from more serious generalized bullous diseases, including Stevens-Johnson syndrome (SJS) and toxic epidermal necrolysis (TEN). The differential diagnosis also includes erythema multiforme, early bullous drug eruption, and bullous arthropod assault, which may leave similar hyperpigmented patches. Fixed-drug eruptions can be distinguished by the lack of simultaneous involvement of 2 mucosal surfaces, lack of generalized desquamation, and normal vital signs and lab values, including white blood cell count and erythrocyte sedimentation rate/C-reactive protein.

■ **A subset of fixed-drug eruption**, generalized bullous fixed-drug eruption (which has been defined as blistering on >10% of the body's surface area at 3 different anatomic sites), may be particularly hard to distinguish from SJS and TEN. Generalized bullous fixed-drug eruption generally has a shorter latency period than SJS or TEN (usually <3 days compared to 7-10 days) and has less mucosal involvement.<sup>6</sup>

**Symptomatic therapy includes antihistamines, glucocorticoid ointment**

Management of a disseminated fixed-drug eruption requires a thorough history to identify the causative agent (including over-the-counter drugs, herbals, topicals, and eye drops). Most patients are asymptomatic, but some (like our patient) are symptomatic and experience generalized pruritus, cutaneous burning, and/or pain. Symptomatic therapy includes oral antihistamines and potent topical glucocorticoid ointment for non-eroded lesions. Additionally, if not medically contraindicated, oral steroids may be used for generalized or extremely painful mucosal lesions at

**INSTANT POLL**

Are you currently performing dermoscopy on your patients?

Yes

No

jfonline.com

a dose of 0.5 mg/kg daily for 3 to 5 days. Be advised, however, that these therapies are based on case report level data.<sup>2</sup>

Local wound care of eroded lesions includes keeping the site moist with a bland emollient and bandaging. The inciting agent must be added to the patient's allergy list and avoided in the future. In equivocal cases, it is prudent to admit the patient for observation to ensure that the eruption is not a nascent SJS or TEN eruption.

■ **Our patient** was admitted to the observation unit overnight to monitor for the appearance of systemic symptoms and to assess the evolution of the rash for further mucosal involvement that could have indicated SJS. Upon reassessment the next day, his older lesions had evolved into vesiculated and necrotic areas as per the natural history of severe fixed-drug eruption.

He was prescribed prednisone 40 mg/d for 3 days to help with local inflammation,

pain, and itching. TMP-SMX was added to his allergy list and he was given local wound care instructions. He was told to return if he developed any systemic symptoms. **JFP**

#### CORRESPONDENCE

Jackie Bucher, MD, 7733 Louis Pasteur Drive Apt. 209, San Antonio, TX 78229; bucher@uthscsa.edu.

#### References

1. Shiohara T. Fixed drug eruption: pathogenesis and diagnostic tests. *Curr Opin Allergy Clin Immunol*. 2009;9:316-321.
2. Wolff K, Johnson RA. Dermatology and internal medicine: fixed drug eruption. In: Wolff K, Johnson RA, Saavedra AP, eds. *Fitzpatrick's Color Atlas and Synopsis of Clinical Dermatology*. 6th ed. New York: McGraw-Hill; 2009:566-568.
3. Ozkaya-Bayazit E, Bayazit H, Ozarmagan G. Drug related clinical pattern in fixed drug eruption. *Eur J Dermatol*. 2000;10:288-291.
4. Sharma VK, Dhar S, Gill AN. Drug related involvement of specific sites in fixed eruptions: a statistical evaluation. *J Dermatol*. 1996;23:530-534.
5. Thankappan TP, Zachariah J. Drug-specific clinical pattern in fixed drug eruptions. *Int J Dermatol*. 1991;30:867-870.
6. Cho YT, Lin JW, Chen YC, et al. Generalized bullous fixed drug eruption is distinct from Stevens-Johnson syndrome/toxic epidermal necrolysis by immunohistopathological features. *J Am Acad Dermatol*. 2014;70:539-548.

NOW ONLINE AT WWW.JFPONLINE.COM

A supplement to The Journal of Family Practice

# Major Depressive Disorder in the Primary Care Setting

## STRATEGIES TO ACHIEVE REMISSION AND RECOVERY


### Faculty

BRADLEY N. GAYNES, MD, MPH  
W. CLAY JACKSON, MD, DipTh  
KASHEMI D. RORIE, PhD

### Discussion includes:

- Diagnosis of depression in the primary care setting
- Treatment of depression
- Measurement-based care for major depressive disorder

1.25 CME CREDITS AVAILABLE



This supplement is jointly provided by the North Carolina Academy of Family Physicians (NCAFP) and Spire Learning and is supported by an educational grant from Takeda Pharmaceuticals International, Inc, US Region and Lundbeck.