



CURTIS M. RIMMERMAN, MD

Head, Section of Clinical Cardiology, Department  
of Cardiovascular Medicine, The Cleveland Clinic

# The Clinical Picture

## A 62-year-old man with an abnormal electrocardiogram

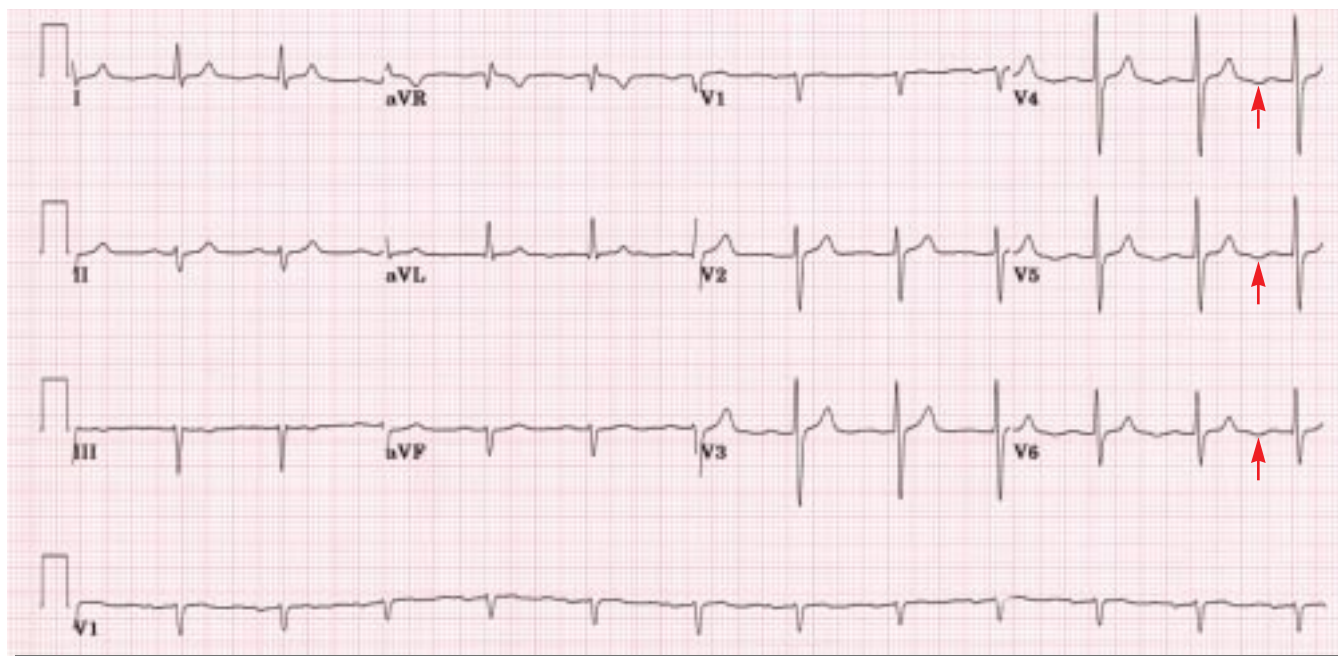


FIGURE 1. The patient's current electrocardiogram.

**Q:** A 62-YEAR-OLD MAN presented for evaluation of central chest discomfort that began several months earlier. The discomfort felt similar to a fullness or squeezing sensation, occurred only during brisk walking or ascending stairs, and was promptly relieved with rest. A strong family history of premature coronary artery disease had prompted a diagnostic left heart catheterization 4 years ago, which demonstrated an approximately 50% stenosis of the mid-left anterior descending coronary artery. He had been started on metoprolol, atorvastatin, and aspirin. No coronary intervention had been performed, and there was no follow-up examination.

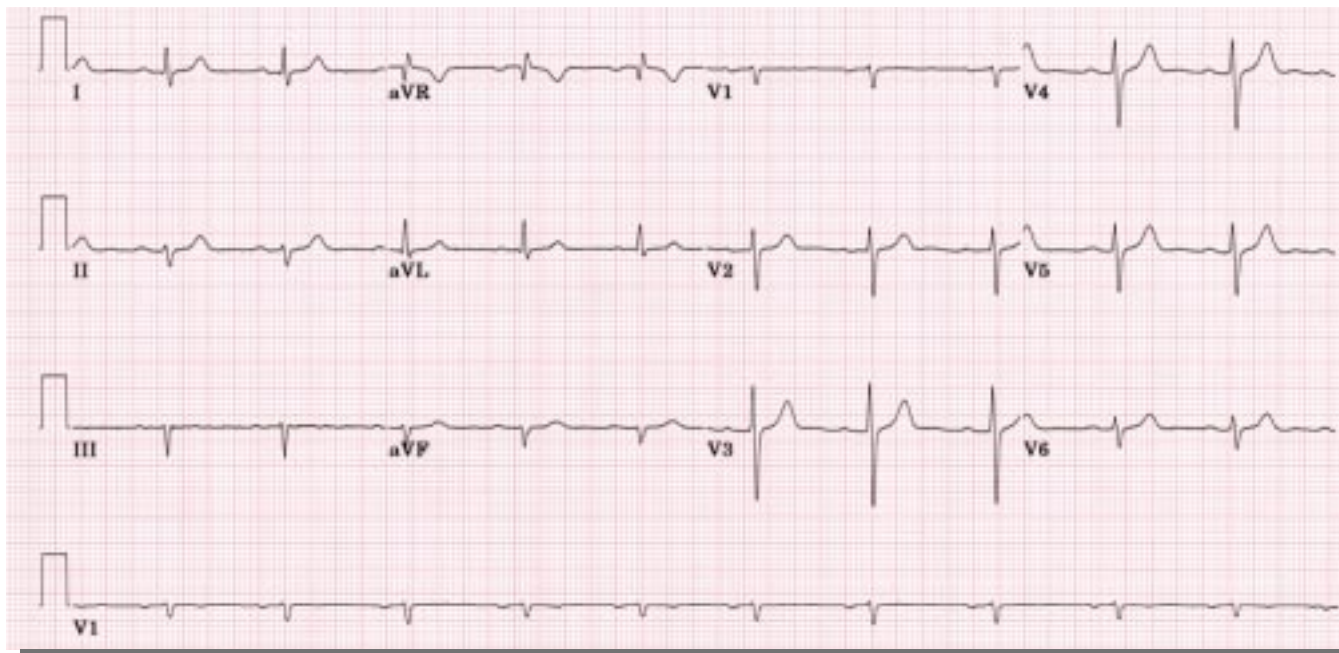
An electrocardiogram (ECG) at his present visit (FIGURE 1) demonstrates all of the following except which one?

- Features consistent with an ostium secundum atrial septal defect

- Normal sinus rhythm
- First-degree atrioventricular block
- Prominent negative U waves

**A:** The ECG demonstrates all of the findings except an ostium secundum atrial septal defect.

An ostium secundum atrial septal defect is a true deficiency of the atrial septum in the region of the fossa ovalis. A left-to-right shunt at the atrial level results in right heart volume overload. This volume overload typically manifests electrocardiographically as an incomplete right bundle branch block pattern, most often seen in lead V<sub>1</sub>. Additionally, the QRS complex frontal plane axis may demonstrate rightward deviation. Neither of these findings is present on this electrocardiogram (FIGURE 1).



**FIGURE 2.** The patient's electrocardiogram from 4 years previously.

Normal sinus rhythm is present: the frontal plane P wave axis is normal, and the PP interval is regular at a rate of 73 per minute. The PR interval of 220 msec indicates first-degree atrioventricular block. Most importantly, this electrocardiogram demonstrates prominent negative U waves, best seen in leads V<sub>4</sub> through V<sub>6</sub> (FIGURE 1, arrows).

The patient's ECG from 4 years ago (FIGURE 2) was similar, except for the notable absence of negative U waves.

**Q:** THE INTERVAL DEVELOPMENT of negative U waves in this patient supports which of the following diagnoses?

- Left ventricular hypertrophy
- Hypokalemia
- Myocardial ischemia
- Coronary vasospasm

**A:** In this patient, the best answer is myocardial ischemia.

On the basis of his presenting symptoms and coupled with the electrocardiographic finding of prominent negative U waves, a diagnostic heart catheterization was performed, demonstrating a 90% stenosis of the mid-left anterior descending coronary artery. The patient underwent angioplasty and stenting, and his

symptoms completely resolved. Six months later the negative U waves had resolved completely.

#### ■ THE SIGNIFICANCE OF NEGATIVE U WAVES

Negative U waves are a well-known, important, and often overlooked electrocardiographic finding. While the exact mechanism is unclear, myocardial ischemia is a known cause. They are considered a reliable marker of coronary artery disease. They are often transient, developing during exercise stress. They also occur in left ventricular hypertrophy, more commonly in volume overload states such as aortic insufficiency.

Although it may be difficult to determine their exact cause, negative U waves should always be considered abnormal and merit further investigation (noninvasive cardiac imaging) in an otherwise asymptomatic patient. In our patient, they prompted his immediate referral for left heart catheterization in lieu of noninvasive stress testing.

#### ■ SUGGESTED READING

Kishida H, Cole JS, Surawicz B. Negative U wave: a highly specific but poorly understood sign of heart disease. *Am J Cardiol* 1982; 49:2030–2036.

McHenry PL, Fisch C. Clinical applications of the treadmill exercise test. *Mod Concepts Cardiovasc Dis* 1977; 46:21–25.

Rimmerman C, Jain A. Interactive electrocardiogram CD-ROM with workbook. Philadelphia: Lippincott Williams & Wilkins, 2001.

ADDRESS: Curtis M. Rimmerman, MD, Department of Cardiology, F15, The Cleveland Clinic Foundation, 9500 Euclid Avenue, Cleveland, OH 44195; e-mail rimmerc@ccf.org.