

GERALDINE M. MCCARTHY, MD

Department of Medicine, University College and Mater Misericordiae Hospital; and Department of Clinical Pharmacology, Royal College of Surgeons in Ireland, Dublin

CONOR J. MCCARTHY, MD

Department of Medicine, University College and Mater Misericordiae Hospital, Dublin

DERMOT KENNY MD

Department of Clinical Pharmacology, Royal College of Surgeons in Ireland, Dublin

JOHN CROWE, MD, PhD

Department of Medicine, University College and Mater Misericordiae Hospital, Dublin

STEPHEN EUSTACE, MB

Department of Radiology, University College and Mater Misericordiae Hospital, Dublin

Hereditary hemochromatosis: A common, often unrecognized, genetic disease

■ ABSTRACT

Hereditary hemochromatosis in people of northern European descent is more common than many physicians realize. It causes excessive gastrointestinal absorption of iron, leading to potentially fatal iron deposition in multiple organs. Early diagnosis and phlebotomy to reduce iron stores can prevent complications and provide normal life expectancy. Genetic testing of relatives of patients with hemochromatosis is warranted in some circumstances.

■ KEY POINTS

Phlebotomy also benefits most patients who already have iron overload.

Many patients will need additional evaluation and treatment for complications of iron overload such as cardiac dysfunction, liver disease, diabetes mellitus, and arthritis.

Genetic tests for identifying mutations in the *HFE* gene can be used for diagnosis, family testing, and population screening.

HEREDITARY HEMOCHROMATOSIS is underdiagnosed, although it is one of the most common genetic diseases affecting people of northern European descent. Clinicians lack sufficient awareness of the disease's prevalence, its long latency period, and its nonspecific symptoms.

See related editorial, page 239

In this disease, iron is continuously absorbed from the gastrointestinal tract and deposited in the liver, pancreas, heart, gonads, pituitary gland, and other organs.

Hemochromatosis can cause cirrhosis, hepatoma, cardiomyopathy, and other organ damage that may be fatal. Because hereditary hemochromatosis is associated with diabetes and with dark skin pigmentation in otherwise fair-skinned patients, it was classically described as “bronze diabetes.”

Early diagnosis followed by early and regular therapeutic phlebotomy can prevent iron overload and provide patients with a normal life expectancy. Even when initiated later in the course of the disease, therapeutic phlebotomy reduces the likelihood of chronic disease and improves many symptoms of the disorder.¹

Hereditary hemochromatosis affects as many as 8 per 1,000 persons of northern European descent. At least 50% of men and 25% of women with the disease are likely to develop life-threatening complications.

■ GENETIC BASIS FOR HEMOCHROMATOSIS

According to recent discoveries, a gene



PATIENT INFORMATION

What is hemochromatosis? page 238



called *HFE* is associated with most cases of hemochromatosis.² The gene produces a protein in the deep crypts of the duodenum, the location where gastrointestinal iron absorption is at its highest.³ Healthy people have large quantities of this *HFE* protein, which modulates iron transport through the enterocyte, but people who have a point mutation called *C282Y* produce it in much smaller quantities and develop hemochromatosis.³

A smaller proportion of patients with hemochromatosis have a different mutation, called *H63D*. It is not clear how the *H63D* mutation causes hemochromatosis.⁴ A third group of patients have non-*HFE*-associated hemochromatosis; the genetic basis of this type of hemochromatosis is being studied.

People who are heterozygous for the *C282Y* mutation rarely develop overt clinical disease. However, their likelihood of developing iron overload liver damage rises if they have other risk factors such as hepatitis, alcoholism, or porphyria cutanea tarda.

Patients who are heterozygous for both *C282Y* and *H63D* may develop iron overload, but it is usually not as severe as iron overload in a *C282Y*-homozygous patient.

■ ENVIRONMENTAL AND DIETARY FACTORS AFFECT DISEASE RISK

Although hemochromatosis is a genetic disease, its development is affected by dietary and environmental factors.

Patients who take iron supplements or vitamin C (which increases iron absorption) may experience symptoms earlier. Serious complications are particularly likely in people who consume high-iron diets, such as diets high in red meat.

Other environmental factors can delay the onset of disease by decreasing hepatic iron stores: blood donation, physiologic blood loss through menstruation and pregnancy, and pathologic blood loss (for example, through inflammatory bowel disease).

Contrary to popular belief, premenopausal women can still develop symptomatic and even life-threatening hemochromatosis.

Pigmentation of hereditary hemochromatosis

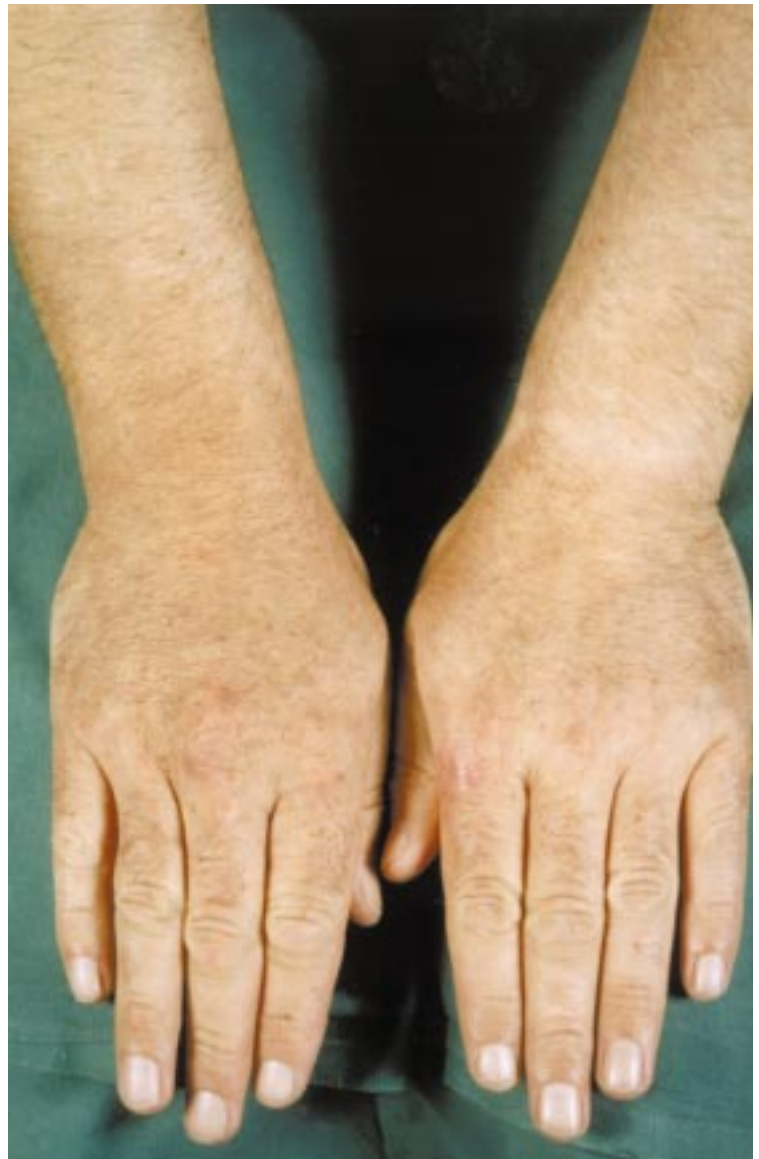

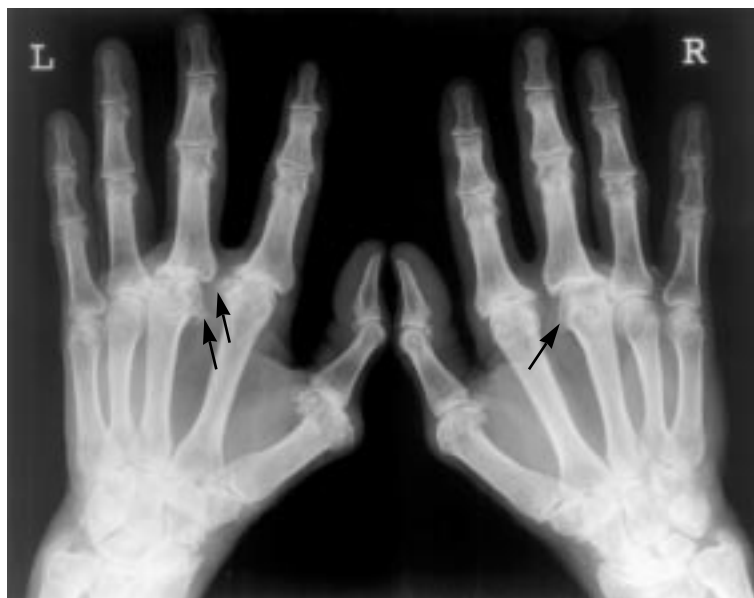FIGURE 1. Skin pigmentation on the hands and forearms of a patient with hereditary hemochromatosis.

■ NATURAL HISTORY AND CLINICAL FEATURES OF HEMOCHROMATOSIS

The disease often produces no symptoms until middle age. Untreated, it progresses from iron overabsorption to iron overload to organ damage.

Complications may include arthritis, cardiomyopathy, and endocrine disorders, including diabetes and hypogonadism.

Hemochromatosis arthritis



Osteoarthritis

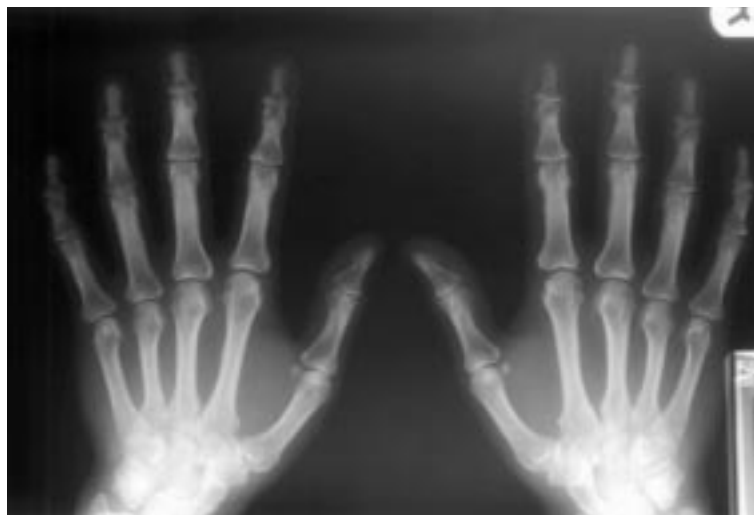

FIGURE 2. Top, this patient with hemochromatosis arthritis has symmetric arthropathy of second and third metacarpophalangeal joints with loss of cartilage and the formation of marginal beaked osteophytes (arrows). Bottom, in contrast, in this patient with osteoarthritis, mild osteoarthritis is visible in the distal interphalangeal joints of all fingers, especially the right second and third. There is minimal involvement of the right proximal interphalangeal joints.

Early biochemical signs

The first manifestation of the disease is an elevation in serum transferrin saturation,⁵ which reflects the transport of excess iron from the intestine. Serum transferrin levels become

elevated before iron loading becomes significant, and they increase in direct linear relation to total-body iron stores.

Occasionally, elevated concentrations of liver enzymes are a presenting sign.

Early clinical symptoms

Patients usually begin to experience symptoms between ages 30 and 50. Symptoms are 5 to 10 times more common in men than in women.

Fatigue and arthralgia are the most common presenting symptoms. Patients may also present with skin pigmentation, impotence, hepatomegaly, diabetes mellitus, thyroid disease, arthritis, heart failure, or arrhythmia. Occasionally, cirrhosis develops without other clinical symptoms.

At diagnosis, more than 90% of patients with symptoms have skin pigmentation (FIGURE 1). The characteristic slate-grey color is caused by melanin or by both melanin and iron in the dermis. The pigmentation is diffuse and generalized, but frequently it is deeper on the face, neck, backs of hands, scars, lower legs, and genital regions. The pigmentation occurs on the oral mucosa in 10% of cases.

Later complications

Liver disease. When the hepatic iron concentration reaches a threshold of 400 $\mu\text{mol/g}$ dry weight, cirrhosis is common, and the risk for hepatocellular carcinoma and death are markedly increased. The iron threshold is lower in patients with other risk factors for liver diseases, such as heavy drinking or chronic hepatitis.

Diabetes. Iron-overload damage to the pancreas causes diabetes mellitus in about 65% of patients with hemochromatosis. Diabetes is more likely to develop in those with a family history of diabetes. The sequelae of diabetes associated with hemochromatosis are the same as those of ordinary diabetes mellitus.

Arthritis and chondrocalcinosis. From 25% to 50% of patients with hemochromatosis may develop arthritis. The arthritis may precede the diagnosis of hemochromatosis by many years, or it may present long after treatment.^{6,7} The arthritis can affect most joints but most commonly causes stiffness and pain



Algorithm for screening for and diagnosing hemochromatosis

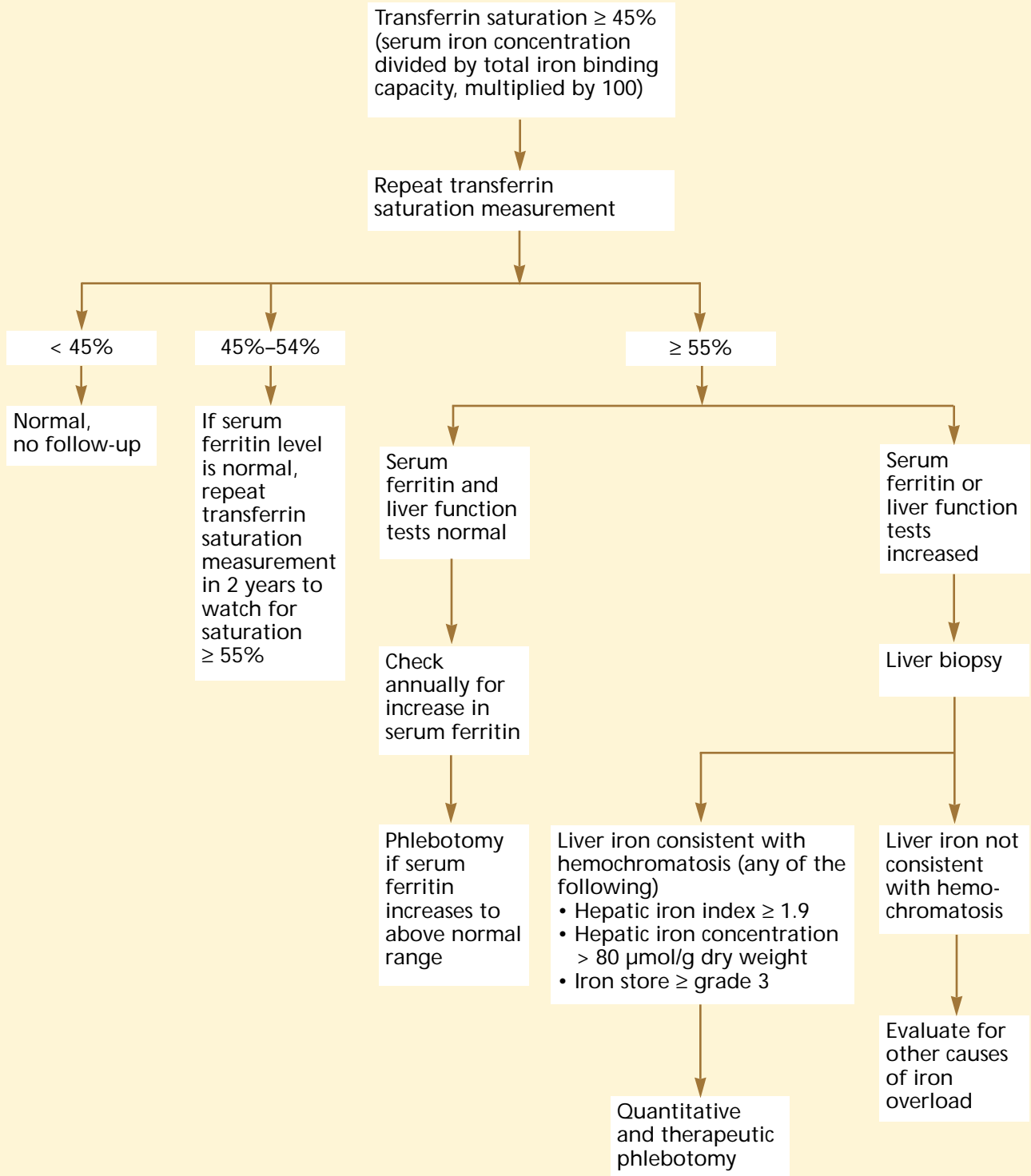


FIGURE 3

of the hand joints, particularly the index and middle metacarpophalangeal joints. Radiographs typically show changes consistent with a symmetric arthritis of the second and third metacarpophalangeal joints with loss of cartilage and the formation of marginal beaked osteophytes (FIGURE 2). Hemochromatosis arthritis in the knee characteristically involves the medial cartilage space or the patellofemoral joint.⁸

Most cases of hemochromatosis-associated arthritis are related to chondrocalcinosis identifiable on radiographs. Calcium pyrophosphate dihydrate (CPPD) crystals have been reported in the cartilage of patients with hemochromatosis even in the absence of changes on radiographs.⁹ Patients with deposits of these crystals may experience acute pseudogout. The symptoms may be associated with chondrocalcinosis at the wrist, knees, or both. The CPPD crystals in synovial fluid can be identified by polarized light microscopy.

Hemochromatosis arthritis may be mistaken for rheumatoid arthritis, particularly when patients present with a symmetric inflammatory polyarthritis.

The pathogenesis of this arthropathy is not fully understood. It is possible that iron deposits in the synovial tissue trigger the formation of free radicals or that they inhibit the pyrophosphatase enzyme, thereby leading to CPPD crystal deposition.

Hemochromatosis is also associated with an increased incidence of osteoporosis.¹⁰

Cardiac symptoms. About 15% of patients with hemochromatosis have cardiac symptoms as presenting symptoms, and about 30% of untreated patients develop cardiac symptoms.¹¹ The cardiac manifestations of hemochromatosis vary with the extent of the iron deposits.

Although other infiltrative cardiomyopathies such as amyloid cardiomyopathy produce deposits *around* the myocytes, hemochromatosis produces iron deposition *within* myocytes. The deposits develop in critical regions of the heart, including the left ventricle, the atrioventricular node, and the conduction system. Electrocardiograms may show low voltage and nonspecific ST-T changes.

When cardiac hemochromatosis is severe enough to produce clinical manifestations, it

usually results in dilated cardiomyopathy, but it may instead produce restrictive cardiomyopathy. Symptomatic cardiac involvement is usually manifested by congestive heart failure. Patients may present with either supraventricular or ventricular arrhythmias. Myocardial biopsy may be useful to confirm the diagnosis when the primary clinical manifestations are of cardiac origin.¹²

Iron-induced cardiac disease progressively worsens in untreated patients, but appropriate treatment can restore systolic function. Echocardiography may be useful in monitoring systolic function.

Recent data suggest a link between iron and cardiovascular disease. The vulnerability of myocardium to ischemic injury appears to be affected by stored iron level, rather than exclusively by the degree of coronary atherosclerosis.¹³

■ DIAGNOSIS OF HEMOCHROMATOSIS

Transferrin saturation and other biochemical tests

The most useful screening and diagnostic test for hemochromatosis is the fasting transferrin saturation (serum iron concentration divided by total iron binding capacity, multiplied by 100) (FIGURE 3). Hemochromatosis is strongly suggested by a persistently elevated fasting transferrin saturation in the absence of other causes of iron overload (such as beta thalassemia, sideroblastic anemia, or iatrogenic overload). A fasting transferrin saturation of 55% or above suggests hemochromatosis. Patients whose transferrin saturation falls between 45% and 54% and who have no other evident causes such as inflammatory liver disease should be tested again in 2 years.¹⁴

The serum ferritin level should be measured in conjunction with fasting transferrin saturation. A normal serum ferritin level in a patient with elevated fasting transferrin saturation (at 45%–54%) may indicate nonexpressed hemochromatosis, and the patient should have tests repeated after 2 years to identify any changes.

The serum ferritin level should also be used to identify iron overload; when iron overload is detected, treatment should be

30% of untreated patients develop cardiac symptoms

started. Patients whose transferrin saturation on a repeated test is 55% or more may be considered to have primary hemochromatosis-induced iron overload when serum ferritin level is elevated ($> 200 \mu\text{g/L}$ in premenopausal women and $> 300 \mu\text{g/L}$ in men or postmenopausal women) or when they show evidence of liver disease, such as elevated liver enzyme concentrations or hepatomegaly. However, ferritin is an acute phase reactant, and serum levels may rise in inflammatory conditions, in malignancy, or with acute liver injury without iron overload. Serum ferritin is also useful as a measure of iron reaccumulation in the treated patient.

The serum iron concentration is an unreliable test and should not be used alone. Marked diurnal variation is normal; concentrations are highest in the morning and elevated after meals. If used, the serum iron concentration should be measured in conjunction with the total iron binding capacity.

Serum levels of alanine aminotransferase (ALT) and aspartate aminotransferase (AST) are often, but not always, abnormal in patients with overt hemochromatosis. Conversely, these enzymes are not specific for the liver and may be elevated in association with other diseases of the heart, skeletal muscle, or kidney. Reduced serum albumin or prolonged prothrombin time may also suggest liver damage.

Liver biopsy

Liver biopsy, formerly the gold standard for the diagnosis of hemochromatosis, is no longer necessary for all patients. It is still indicated for those who present with the physical signs of liver disease, abnormal liver function tests (ALT or AST), or serum ferritin levels higher than $1,000 \mu\text{g/L}$.

Liver biopsy samples can be used to estimate tissue iron quantities, measure hepatic iron concentration, and identify cirrhosis. When cirrhosis is documented, the patient should be monitored for the development of primary hepatocellular carcinoma.

DNA-based diagnostic tests

Tests to identify mutations in the *HFE* gene may provide precise means for diagnosis, family testing, and even population screening.

Currently, genetic testing can identify the C282Y mutation responsible for most cases of hemochromatosis. It can be used to confirm a diagnosis made on the basis of biochemical tests and is particularly helpful in patients whose disease was detected through screening, who are less likely to have cirrhosis or the other indications for liver biopsy (abnormal liver function tests or elevated serum ferritin). Genetic testing may also be helpful to make a diagnosis in patients who have some positive and some negative test results (for example, an elevated transferrin saturation, a normal serum ferritin level, normal liver enzyme concentrations, and no hepatomegaly). Patients found to be homozygous for the C282Y mutation can be tested annually for serum ferritin increases.

It must be emphasized, however, that not all patients with hemochromatosis carry the C282Y mutation. No genetic test is available for the other identified mutation, H63D, or for the cause of non-*HFE*-associated hemochromatosis. Thus, genetic testing is not 100% sensitive for hereditary hemochromatosis.

Diagnostic imaging

Computed tomography can identify increased density of the liver caused by iron deposition. Magnetic resonance imaging (MRI) is a non-invasive alternative to biopsy for quantifying iron overload.¹⁵ Quantification by MRI can be used to track the iron content during depletion treatment by phlebotomy.

■ MANAGEMENT OF HEMOCHROMATOSIS

Therapeutic phlebotomy, described in 1952, was the first successful treatment for hemochromatosis-induced iron overload and is still the preferred treatment (TABLE 1).¹⁶ Removing 1 unit of blood (450 to 500 mL) results in the loss of 200 to 250 mg of iron. Most patients who have developed iron overload before diagnosis benefit from phlebotomy. Therapeutic phlebotomy should be performed by experienced staff under physician supervision, usually in a physician's office.

Patients should be advised to drink plenty of liquids and to avoid vigorous physical activ-

Liver biopsy is no longer necessary for all patients

**TABLE 1****Expected results of phlebotomy in patients with hemochromatosis at different stages**

FOR PATIENTS WHO HAVE:	PHLEBOTOMY IS EXPECTED TO:
No complications	Prevent complications and provide normal life expectancy
Weakness, fatigue, lethargy	Resolve or markedly improve symptoms
Elevated hepatic enzymes	Resolve or markedly improve symptoms
Hepatic cirrhosis	Produce no change
Increased risk for primary liver cancer	Produce no change
Right upper quadrant pain	Resolve or markedly improve symptoms
Arthropathy	Possibly improve symptoms, but rarely change joint deformity.
Calcium pyrophosphate dihydrate (CPPD) deposits	Produce no change
Cardiomyopathy	Sometimes resolve condition
Hyperpigmentation	Usually resolve symptoms
Diabetes mellitus	Occasionally (usually temporarily) improve the condition
Hyperthyroidism or hypothyroidism	Rarely resolve symptoms
Hypogonadotropic hypogonadism	Rarely resolve symptoms
Hyperferritinemia	Resolve condition
Excess absorption and storage of nonferrous metals	Produce little or no change

ity for 24 hours after treatment to minimize the effects of hypovolemia. The hemoglobin concentration or hematocrit and volume of blood removed should be documented with each session.

To deplete iron stores, 1 unit of blood is removed each week. Iron depletion is complete when the patient develops mild hypoferritinemia, indicated by a serum ferritin level of 10 to 20 µg/L, a hemoglobin concentration of less than 110 g/L, or a hematocrit of less than 0.33 for more than 3 weeks (in patients without chronic anemia). After the potentially pathogenic iron stores are depleted, the hemoglobin concentration and hematocrit should be allowed to return to the normal range and to remain there. Care should be taken to stop the phlebotomy treatments before iron-deficiency anemia develops.

Phlebotomy should be repeated throughout the patient's life to keep the serum ferritin level at 50 µg/L or less. On average, this requires the annual removal of 3 or 4 units of blood in men and 1 or 2 units of blood in women.

The serum ferritin level is accurate when used to monitor body iron stores. After phlebotomy, serum iron and transferrin saturation values soon return to pretreatment levels, which do not indicate iron overload.¹⁷

Blood banks do not accept blood drawn from patients with hemochromatosis during therapeutic phlebotomy.

Detecting liver cancer

Appropriate testing for liver cancer is crucial for patients with hemochromatosis, because primary liver cancer is found in 10% to 30% of patients who die of hemochromatosis-related causes. The risk of liver cancer is increased approximately 200-fold in patients with cirrhosis, particularly if they are over 55 years old, seropositive for hepatitis B surface antigen, or heavy drinkers.

Any patient with cirrhosis who develops hepatic pain, increasing liver size, unexplained fever, or weight loss should be evaluated for primary liver cancer. Occult cancers may be detected by ultrasound, computed tomography, or MRI. Serum concentrations of

Testing for liver cancer is crucial

alpha-fetoprotein are elevated in one third of patients with primary liver cancer.

Managing complications of iron overload

Many patients need additional evaluation and treatment for complications of iron overload, including cardiac dysfunction, liver disease, diabetes mellitus, and arthritis. In general, the management of these disorders in patients with hemochromatosis is the same as the management of the disorders in other patients.

Arthropathy. Hemochromatosis arthropathy can usually be managed with analgesic medication and nonsteroidal anti-inflammatory drugs. If the arthropathy develops into degenerative joint disease, joint replacement surgery may be required, most commonly in the hip or knee. Anecdotal reports suggest that phlebotomy may occasionally (but rarely) produce an improvement in arthritis. For attacks of pseudogout, joint aspiration and corticosteroid injection or colchicine therapy may be helpful.

Physicians need to be alert for patients who also have other hereditary or acquired joint disorders, such as rheumatoid arthritis or osteoarthritis, which can continue to cause progressive discomfort in patients with hemochromatosis after therapeutic phlebotomy is complete. These disorders should be evaluated and managed independently.

Diabetes. Hemochromatosis patients with diabetes should receive standard diabetes care. However, clinicians should be aware that hemochromatosis patients with diabetes have a higher likelihood of developing insulin resistance.

Sexual and reproductive side effects. In men, hypogonadism may impair libido and produce changes in secondary sex characteristics. The effects are partially relieved by parenteral testosterone or gonadotropin therapy.

Severe iron overload in women of reproductive age is frequently associated with hypogonadotrophic hypogonadism. After iron depletion, therapy with gonadotropin and other hormones can permit normal menstruation and successful pregnancies. In older women, estrogen and progesterone replacement therapy should be considered.

Other endocrine effects. Thyroid dysfunction, caused by pituitary involvement, is managed the same way thyroid dysfunction in other patients is managed.¹⁷ Diagnostic imaging of the pituitary has not been shown to be of value in evaluating this complication.

Cardiac effects. Patients with cardiomyopathy should receive aggressive treatment with conventional medical therapy to control congestive heart failure and minimize serious arrhythmias, at least until vigorous therapeutic phlebotomy relieves the cardiac siderosis. Although phlebotomy may produce some improvement in cardiac function, long-term medical therapy is commonly required. Cardiac dysfunction that develops in otherwise healthy middle-aged or elderly people is occasionally caused by hemochromatosis, but coronary atherosclerosis or other forms of heart disease are more common causes.

Dietary recommendations

Limit iron-rich foods. Foods that contain large concentrations of bioavailable iron, such as red meats and iron-fortified cereals, should be consumed in moderation (see patient information page, "What is hemochromatosis?" page 238). Iron supplements should be avoided completely.¹⁷ However, major alterations in diet are unnecessary, except for patients who cannot tolerate therapeutic phlebotomy, such as those with severe thalassemia.

Limit alcohol intake. Alcoholic beverages should be avoided by patients with evidence of hepatic injury, and other patients with hemochromatosis should drink only in moderation. Alcoholic beverages can sometimes increase iron absorption. Red wine is also relatively high in iron, although its tannins inhibit iron absorption. Drinking 30 g or more of alcohol daily potentiates hepatic injury from iron overload and, in patients with cirrhosis, increases the relative risk for primary liver cancer.

Limit vitamin C. Because vitamin C increases the intestinal absorption of inorganic iron, it seems prudent to advise patients to limit any vitamin C supplements to 500 mg/day. In rare cases, consuming large quantities of vitamin C has been associated with fatal cardiac arrhythmias in patients

See patient
information,
page 238




with iron overload, presumably as a result of oxidative injury caused by mobilization of stored iron.

Limit other minerals. Patients with hemochromatosis should generally avoid dietary supplements containing cobalt, manganese, zinc, cadmium, and certain other non-ferrous metals, because the disease is associated with increased absorption of these minerals as well. Although excess inorganic cobalt is rapidly excreted, manganese and zinc are deposited in the liver and other tissues. Thus, mineral supplements should be used only if a specific nutritional deficiency has been identified.

Hemochromatosis is also associated with increased absorption of lead, which is toxic in

small amounts and is retained for prolonged periods.

■ GENETIC COUNSELING

First-degree relatives of patients with hemochromatosis should be offered genetic screening at age 25 or older. Biochemical screening is not recommended in this situation because it often fails to identify homozygous patients, especially female ones. When a patient is identified as homozygous, his or her spouse should also be screened. If the spouse tests negative for the C282Y and H63D mutations, then the children will be heterozygous and need not be tested. 

■ REFERENCES

1. Powell L, George D, McDonnell S, Kowdley KV. Diagnosis of hemochromatosis. *Ann Intern Med* 1998; 129:925-931.
2. Feder J, Gnirke A, Thomas W, et al. A novel MHC class I-like gene is mutated in patients with hereditary hemochromatosis. *Nat Genet* 1996; 134:399-408.
3. Byrnes V, Ryan E, O'Keane C, Crowe J. Immunohisto-chemistry of the hfe protein in patients with hereditary hemochromatosis, iron deficiency anemia, and normal controls. *Blood Cells Mol Dis* 2000; 26:2-8.
4. Burke W, Thomson E, Khoury M, McDonnell S, Press N, Adams PEA. Hereditary hemochromatosis: gene discovery and its implications for population-based screening. *JAMA* 1998; 280:172-178.
5. McLaren G, Muir W, Kellermeyer R. Iron overload disorders: natural history, pathogenesis, diagnosis and therapy. *Crit Rev Clin Lab Sci* 1983; 19:205-266.
6. Schumacher H. Hemochromatosis and arthritis. *Arthritis Rheum* 1964; 7:41-50.
7. Dymock IW, Hamilton EB, Laws JW, Williams R. Arthropathy of haemochromatosis. Clinical and radiological analysis of 63 patients with iron overload. *Ann Rheum Dis* 1970; 29:469-476.
8. Eustace S, Baker N, Lan H, Dorfman D. Hemochromatosis arthropathy. *Radiol Clin North Am* 1996; 34:441-445.
9. Mathews J, Williams H. Arthritis in hereditary hemochromatosis. *Arthritis Rheum* 1987; 30:1137-1141.
10. Axford J. Rheumatic manifestations of hemochromatosis. *Baillieres Clin Rheumatol* 1991; 5:351-365.
11. Cecchetti G, Binda A, Piperno A, Nador F, Fargion S, Fiorelli G. Cardiac alterations in 36 consecutive patients with idiopathic haemochromatosis: polygraphic and echocardiographic evaluation. *Eur Heart J* 1991; 12:224-230.
12. Mason J, O'Connell J. Clinical merit of endomyocardial biopsy. *Circulation* 1989; 79:971-979.
13. Sullivan J. Iron and the genetics of cardiovascular disease. *Circulation* 1999; 100:1260-1263.
14. McLaren C, McLachlan G, Halliday J, et al. Distribution of transferrin saturation in an Australian population: relevance to the early diagnosis of hemochromatosis. *Gastroenterology* 1998; 114:543-549.
15. Kreeftenberg H, Mooyaart E, Huizenga J, Sluiter W. Quantification of liver iron concentration with magnetic resonance imaging by combining T1-, T2-weighted spin echo sequences and a gradient echo sequence. *Neth J Med* 2000; 56:133-137.
16. Davis W, Arrowsmith W. The effect of repeated phlebotomies in hemochromatosis: report of three cases. *J Lab Clin Med* 1952; 39:526-532.
17. Barton J, McDonnell S, Adams P, et al. Management of hemochromatosis. *Ann Intern Med* 1998; 129:932-939.

.....
ADDRESS: Geraldine M. McCarthy, MD, Department of Clinical Pharmacology, Royal College of Surgeons in Ireland, 123, St. Stephen's Green, Dublin 2, Ireland; e-mail gmccarthy@rcsi.ie