

**DANIEL J. MAZANEC, MD**

Director, Spine Center, Department of Rheumatic and Immunologic Disease, The Cleveland Clinic

VINOD K. PODICHETTY, MD

Coordinator - Research Studies, Spine Center, Department of Rheumatic and Immunologic Disease, The Cleveland Clinic

AUGUSTO HSIA, MD

Spine Center, Department of Rheumatic and Immunologic Disease, The Cleveland Clinic

Lumbar canal stenosis: Start with nonsurgical therapy

ABSTRACT

Although surgery is widely viewed as the definitive therapy for lumbar spinal stenosis, no randomized trials have compared surgical vs medical treatment. One study found that 60% of surgically treated patients improved, compared with 30% of those treated nonsurgically. We believe an initial nonsurgical approach is advisable for most patients.

KEY POINTS

The diagnosis of spinal stenosis is based primarily on the clinical history of neurogenic claudication, also known as pseudoclaudication.

Spinal imaging should be performed to confirm the clinical diagnosis when required.

Neurogenic claudication should be distinguished from true vascular claudication on the basis of history, physical findings, and vascular studies if necessary.

The natural history of lumbar canal stenosis is frequently benign, and many patients respond to nonsurgical treatment.

Surgery should be reserved for when medical treatment fails and leg symptoms are severe and functionally disabling.

WE HAVE TO LIVE with some uncertainty in diagnosing and treating lumbar canal stenosis, even though it is one of the most common spinal disorders in people older than 65 years, and frequently causes significant functional impairment.¹ For example:

- Though nearly all people in this age group have radiographic evidence of degenerative disc and joint disease, the incidence of clinically symptomatic lumbar canal stenosis is unknown.
- The diagnosis is largely clinical. Although imaging studies can confirm the diagnosis, they often show abnormalities in people with no symptoms.
- Treatment is mostly empiric. Although lumbar canal stenosis is the most common reason for spinal surgery in this aging population,² and accounts for inpatient expenses approaching \$1 billion per year,³ no comparison of surgical vs nonsurgical treatment has ever been done.

Even though most studies show that surgery provides the most benefit over the long term, a substantial number of people improve with nonsurgical therapy, such as physical therapy, analgesics, and NSAIDs. We recommend an initial nonsurgical treatment approach for most patients.

DEFINITION AND CLASSIFICATION

Lumbar canal stenosis is a narrowing or stricture of the spinal canal, with potential for nerve impingement, which may occur in the central canal, in the lateral recess, or at the neuroforamen.^{4,5}

The cause of spinal canal narrowing may be multifactorial. Degenerative changes are typically involved, including facet joint hyper-

This paper discusses therapies that are not approved by the US Food and Drug Administration for the use under discussion.

TABLE 1

Classification of spinal stenosis

Congenital stenosis

- Idiopathic
- Achondroplastic

Acquired stenosis

- Degenerative
- Combined congenital and degenerative
- Spondylolisthetic/spondylitic
- Estrogenic
- Post-traumatic
- Miscellaneous
 - Paget disease
 - Fluorosis
 - Tumors
 - Infection

trophy, ligamentum flavum thickening, and disc bulging and protrusion, alone or in combination. Degenerative spondylolisthesis, a distinct clinical feature characterized by forward displacement of a vertebra due to disc and facet degeneration, is another frequent factor, further compromising the diameter of the spinal canal.⁶

The classification of spinal stenosis proposed by Arnoldi, Brodsky, and Cauchoix⁶ in 1976 remains useful. In this scheme, based on the presumed etiology, spinal stenosis is classified as either congenital or acquired (TABLE 1).

Alternatively, spinal stenosis can be classified on the basis of the location of the anatomic narrowing, ie, central canal stenosis or lateral recess stenosis (FIGURE 1).

CLINICAL PRESENTATION

Recognition of spinal stenosis depends primarily on the description of the leg symptoms. Physical examination occasionally demonstrates neurologic deficits or exacerbation of symptoms with spinal positioning. However, many patients with spinal stenosis have no abnormal findings on examination.

Spinal imaging confirms the clinical impression. Because many people who have no symptoms are found to have radiographic abnormalities, clinical correlation is critical.

History

Spinal stenosis typically affects persons over 50 years of age.⁷ It is uncommon in younger people unless they are anatomically predisposed by a congenitally narrowed canal, previous spine trauma or surgery, spondylolisthesis, or even scoliosis.

The classic symptom of central canal stenosis is pseudoclaudication, also known as neurogenic claudication.^{1,3,4,7,8} Patients typically complain of pain, paresthesia, weakness, or heaviness in the buttocks radiating into the lower extremities with walking or prolonged standing, relieved with flexion or sitting. Though many patients have significant lumbar pain due to degenerative joint and disc changes, most have more lower extremity discomfort rather than spinal pain.

The most important aspect of neurogenic claudication is the relationship of symptoms to posture. Symptoms occur with spinal extension and are relieved in flexion. Patients usually have no symptoms or have minimal discomfort when seated or supine. They can walk longer distances with less pain in a forward flexed position, such as when using a grocery cart while shopping (the “grocery cart sign”). They may be able to exercise using a stationary bicycle in the seated flexed position for a much longer time (the bicycle test of Van Gelderen) than when walking in the erect position on a treadmill.

In a review of 68 patients with myelographically proven, surgically confirmed spinal stenosis,⁸ the most common symptoms were pseudoclaudication and standing discomfort (94%), followed by numbness (63%) and weakness (43%). Symptoms were bilateral in 68%. Discomfort was felt both above and below the knee in 78%, in the buttocks or thigh only in 15%, and below the knee in 7%.

Historic features correlating most strongly with a confirmed diagnosis of spinal stenosis (likelihood ratio ≥ 2) include age greater than 65 years, severe lower extremity pain, and absence of pain when seated.⁹

Physical examination

The physical examination in patients with lumbar canal stenosis is frequently normal or demonstrates only nonspecific findings.

Many older people have reduced spinal

People with spinal stenosis often assume a forward-flexed (“simian”) stance



Lumbar canal stenosis

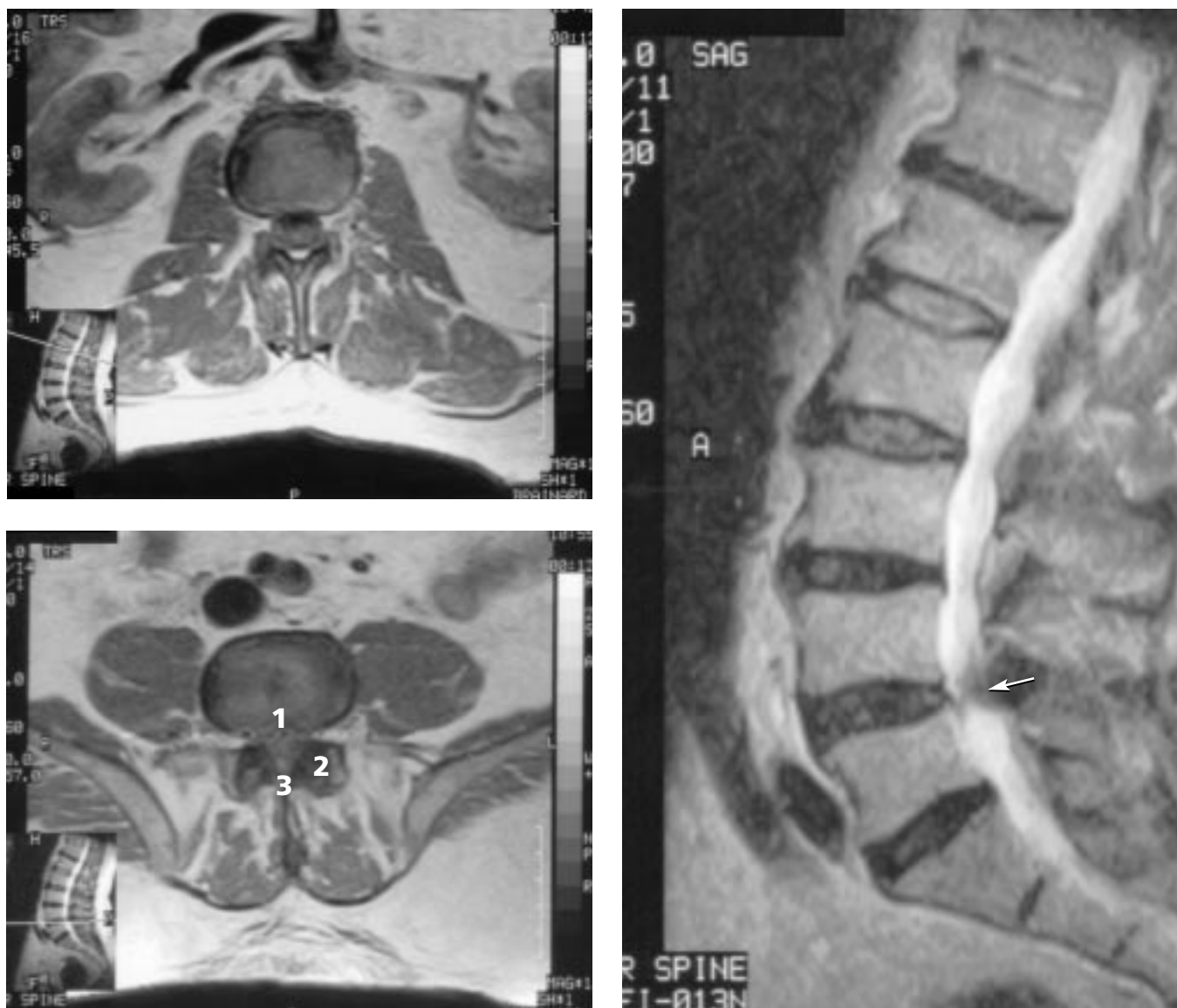

FIGURE 1. Magnetic resonance imaging (MRI) scans in a 75-year-old man. **Top left**, minimal degenerative changes at the L1-L2 level. **Bottom left**, severe lumbar canal stenosis at the L4-L5 level due to (1) disc degeneration, (2) facet hypertrophy, and (3) ligamentum flavum hypertrophy. **Right**, lateral view. Note the stenosis at L4-L5 (arrow).

mobility, with or without spinal canal stenosis. Extension is usually more limited than flexion.^{10,11}

Patients with stenosis often have lumbar, paraspinal, or gluteal tenderness, probably related to underlying degenerative changes, muscle spasms, and poor posture. Some assume a characteristic “simian stance,” with their hips and knees slightly flexed and the

trunk stooped forward.⁷ This semiflexed posture allows patients to stand or walk for longer distances.

Hamstring tightness is often present and may produce a false-positive straight leg-raise test.

The neurologic examination typically is normal or reveals only subtle abnormalities such as mild weakness, sensory changes, and

TABLE 2

Findings in neurogenic claudication and vascular claudication

FINDING	NEUROGENIC CLAUDICATION	VASCULAR CLAUDICATION
Symptoms with walking	Yes	Yes
Symptoms with standing	Yes	No
Variable walking distance before symptoms	Yes	No
Relief with flexion	Yes	No
Relief with sitting	Yes	Yes
Peripheral pulses diminished	No	Yes

reflex abnormalities. This is particularly true if the patient has rested in the seated position before the physical examination begins. These subtle findings may be unmasked if the patient is examined after walking until developing leg and buttock symptoms similar to the presenting complaint.⁴

Ankle reflexes are diminished in 43% to 65% of patients, while knee reflexes are abnormal in 18% to 42%.^{9,11} The straight leg-raising test and other nerve root tension signs are usually negative unless there is concomitant disc herniation.

A careful motor examination should be done. Leg weakness is generally mild and overwhelmingly in the distribution of the L4, L5, or S1 nerve roots. Objective evidence of subtle weakness can usually be demonstrated in about 50% of persons with spinal stenosis.² Weakness of the muscles innervated by the L5 nerve root is the most common finding,⁴ and weakness of great toe extensors (extensor hallucis longus) and hip abductors should be sought, the latter by the Trendelenburg test.⁴

The Trendelenburg test is performed by having the patient stand on one leg: if the gluteus medius is not functional or is denervated, the pelvis drops on the side opposite the damaged muscle. This is shown clinically by an abnormal, waddling gait called the "Trendelenburg gait," caused by trying to compensate for a drooping pelvis.

The gait should be carefully observed.

Difficulty in walking on the toes suggests S1 root involvement. Difficulty with heel walking suggests L4 or L5 nerve dysfunction.

Sensory abnormalities may be present in 46% to 51% of preoperative spinal stenosis patients.^{2,10}

Katz et al⁹ found a positive lumbar extension test to be strongly predictive of imaging-confirmed spinal stenosis. This test is performed by asking the standing patient to hyperextend the lumbar spine for 30 to 60 seconds. A positive test is defined by reproduction of the buttock or leg pain.

CENTRAL CANAL STENOSIS VS LATERAL STENOSIS

Symptoms of pseudoclaudication are associated primarily with central lumbar stenosis. In contrast, patients with purely lateral recess stenosis:

- Usually do not develop symptoms of neurogenic claudication¹¹
- Typically have radicular symptoms in a specific dermatomal pattern
- Often have pain at rest, at night, and with the Valsalva maneuver
- Tend to be younger (mean age 41 years) than patients with central canal stenosis (mean age 65 years).¹¹

DIFFERENTIAL DIAGNOSIS

In older patients with back or leg pain, diagnostic possibilities differ from those in younger patients; nonmechanical causes of back pain such as malignancy, infection, or abdominal aortic aneurysm are more common in elderly patients than in younger patients.^{12,13}

Malignancy. Red flags that should raise the suspicion of underlying malignancy include significant weight loss, intractable night pain unrelieved by change in posture or pain medicine, or history of malignancy.¹⁴

Infection. Fever with localized back tenderness, recent systemic infection, or history of an invasive spinal procedure should raise the possibility of a spinal infection.¹³

Vascular claudication. When evaluating leg pain in the elderly, neurogenic claudication must be distinguished from vascular claudication (TABLE 2).

Red flags for spinal malignancy:

- Weight loss
- Intractable night pain
- Prior malignancy



Peripheral neuropathy may also superficially mimic features of spinal stenosis. However, patients with peripheral neuropathy usually have a stocking-glove distribution of pain or paresthesia. There may be a bilateral symmetrical reflex loss. Vibratory sensation is frequently diminished.⁴ Numbness is typically constant with peripheral neuropathy.

Hip disease may produce gait difficulty and leg symptoms. A careful examination of the hips and surrounding soft tissue should be done to exclude significant hip arthritis and gluteal or trochanteric bursitis.

■ DIAGNOSTIC STUDIES

The diagnosis of lumbar canal stenosis is based on the clinical history and findings on physical examination. Spinal imaging is performed to confirm the clinically suspected diagnosis.

Unless you suspect an underlying systemic illness such as malignancy or infection or are concerned about vertebral compression fracture, imaging is not recommended at the initial visit. In the absence of red flags, imaging should be delayed until the patient has completed a conservative treatment program and when surgical intervention is under consideration.

A reason for this recommendation is that even many people with no symptoms whatsoever have abnormal findings—including spinal stenosis—on imaging studies.^{15,16} In a study of patients age 60 and older who did not have back pain, radicular pain, or neurogenic claudication, magnetic resonance imaging (MRI) was abnormal in 57% of cases, 36% of scans demonstrated disc herniation, and 21% demonstrated spinal stenosis.¹⁶

A plain radiograph may be helpful. A weight-bearing anterior-posterior and lateral film of the lumbar spine is recommended. Although plain radiographs cannot assess the presence or absence of neural compression, they can show evidence of degenerative changes such as disc degeneration and facet hypertrophy, which are suggestive. They may also reveal spondylolisthesis, instability, scoliosis, a vertebral fracture, or other spinal deformities that may contribute to symptoms.

Nevertheless, advanced radiographic studies such as MRI, computed tomography

(CT), and myelography for spinal stenosis remain important diagnostic tools. Modic et al¹⁷ compared the sensitivity of MRI, CT, and myelography in surgically confirmed spinal stenosis. The sensitivity of MRI and CT were similar; myelography alone, without subsequent CT imaging, was the least sensitive. When imaging is required, MRI is the first choice, as it is the least invasive and provides excellent neural and soft tissue resolution. When MRI is not possible or feasible, myelography followed by CT (myelo-CT) is preferred.

In most circumstances, an electromyogram/nerve conduction study is unnecessary to confirm a clinical diagnosis of radiculopathy due to canal stenosis. This test is most useful if the history and examination are somewhat atypical or if there is suspicion of peripheral neuropathy.

■ NATURAL HISTORY IS USUALLY BENIGN

Data on the natural history of lumbar canal stenosis are limited. Anecdotally, the clinical course varies considerably. In most patients, the course is chronic and benign.^{18,19} A study of 31 patients with spinal stenosis followed for a mean of 49 months found that symptoms remained unchanged in 70%, improved in 15%, and worsened in 15%.¹⁹

Cauda equina syndrome, defined as compression of the lumbar nerves in the central canal causing sensory and motor deficit, saddle anesthesia, and bowel and bladder dysfunction, is rare. It occurs in the setting of a massive central disc herniation or a burst fracture with retropulsion of fragments, or very rarely as a complication of spinal stenosis surgery.²⁰ It may also occur in moderate stenosis with a superimposed herniated disc.

■ TREATMENT OF LUMBAR SPINAL STENOSIS

Although surgery has been widely viewed as the definitive therapy for lumbar spinal stenosis, no prospective randomized trials have been done to compare surgical vs medical treatment. Decompression surgery was demonstrated to be effective in a number of uncontrolled trials, but the duration of follow-

Many symptom-free people have abnormal spinal MRIs

up varied considerably, and the outcome measures were not consistently described.^{20–28} Though similarly flawed, a number of studies also reported that nonsurgical management is effective.^{8,19,29–33}

One nonrandomized comparison suggested that 60% of surgically treated patients improved, compared with 30% of those treated nonsurgically.²⁵ Improvement was measured by walking capacity, level of pain, and use of analgesics. The follow-up was 31 months in the nonsurgical patients and 53 months in the surgical patients.

Findings: one third of the surgically treated patients and one half of the nonsurgical patients still had neurogenic claudication at the end of follow-up. By visual analogue scale estimation, 60% of the surgically treated patients and 33% of the nonsurgical patients felt better; 58% of the nonsurgical patients were unchanged.

A nonrandomized prospective cohort study over 10 years concluded that the outcome was most favorable with surgical treatment; however, a substantial number of patients also responded to conservative (ie, nonsurgical) treatment.¹⁸ Though 70% of conservatively treated patients reported satisfactory results at 6 months, at 4 years this number had declined to 57%. The authors concluded that an initial nonsurgical approach was advisable for most patients.

■ NONSURGICAL MANAGEMENT

Components of nonsurgical treatment may include activity restrictions, physical therapy, analgesics, anti-inflammatory medications, lumbosacral orthoses, epidural injection, and calcitonin. These therapies have not been compared in any randomized controlled trial, and there is considerable variability among practitioners in their use.

A reasonable approach is to use a stepwise treatment pathway that progresses from least invasive treatments (activity modification, orthoses, physical therapy) to most invasive (epidural injection).³⁴

Physical therapy

Although physical therapy is often the first recommended form of treatment for persons

with spinal stenosis, few studies have closely examined the effect of specific exercise programs on functional outcome.

Generally, active exercise in the form of stretching, strengthening, or aerobic fitness training is recommended. Active exercise may help increase lumbopelvic muscular stabilization, maintaining better posterior pelvic tilt.³⁵ It may also help by improving cardiovascular conditioning and enhancing “soft-tissue function” (strength and flexibility of muscles, ligaments, and tendons).

In an uncontrolled prospective trial,³⁶ we examined the effects of a McKenzie-based exercise approach in 36 patients with spinal stenosis. The McKenzie approach consists of developing a set of patient-specific exercises based on the response of the individual symptoms to repeated end-range spinal movements in various planes and correcting postural deficiencies.³⁷ Significant improvement was defined as at least 50% improvement in at least two of four outcome variables at 12 weeks: pain score, Roland disability score, walking distance, and standing time. The results suggest that, at least in some patients with symptomatic spinal stenosis, an active, customized physical therapy program may produce significant benefit.

Exercises that encourage lumbar flexion and flattening of the lumbar lordotic curve can be of a clinical benefit to patients suffering from lumbar spinal stenosis. Physical therapy may be prescribed with the goals of improving strength, endurance, and flexibility.

NSAIDs and analgesics

Nonsteroidal anti-inflammatory drugs (NSAIDs) and analgesics are sometimes used to treat symptoms of spinal stenosis, though comparative studies demonstrating efficacy in this patient group are not available.

In addition, many patients with spinal stenosis are at relatively high risk for NSAID toxicity in view of their age and comorbid medical problems, such as hypertension and cardiovascular disease. Furthermore, there is no clear rationale for an anti-inflammatory agent in most patients with degenerative spinal stenosis.

Studies comparing acetaminophen and ibuprofen or naproxen in degenerative arthri-

There is usually no clear rationale for an NSAID in degenerative spinal stenosis



tis of the knee have not demonstrated significant differences in outcome, but similar trials have not been conducted in patients with lumbar canal stenosis.³⁸

In the absence of data to show that NSAIDs are superior to simple analgesics such as acetaminophen, the risk of NSAID toxicity is the determining factor in therapeutic decision-making. NSAIDs are strongly contraindicated in patients with a history of congestive heart failure, peptic ulcer, or kidney disease. If an NSAID is used, frequent clinical and laboratory monitoring for adverse renal or gastrointestinal reactions is mandatory.

Long-term opioid therapy should be considered in some patients with spinal stenosis who have had an unsatisfactory response to other medical therapies and who are not surgical candidates. Comorbidity and frailty may limit the usefulness of physical therapy and NSAIDs and increase the risk of surgical therapy, particularly in older patients. In such patients, a careful trial of low-dose opioids is reasonable,³⁹ with the following caveats:

- Assess for pain control and functional improvement, ie, in walking, standing, and self-care activities.
- The possibility that chronic use of opioids may adversely affect cognition, particularly in the older patient, is not well studied. Until you can establish that an older patient is not experiencing any cognitive deficit, he or she must be advised to avoid driving and take measures to prevent falls and accidents.
- Constipation is a universal side effect of opioids, and a preventive program should be initiated at the onset of opioid therapy.
- Though physical dependence occurs with long-term opioid therapy, addictive behavior is exceedingly rare, particularly in this subset of patients.⁴⁰

Calcitonin

Several small clinical trials reported beneficial effects of calcitonin in patients with spinal stenosis.⁴¹⁻⁴⁴ Improvement in both pain and walking tolerance has been described. The beneficial effects were usually apparent within 4 to 6 weeks.

However, a recently completed double-blind, randomized, placebo-controlled trial

was unable to demonstrate clinical effectiveness of calcitonin administered by nasal spray in persons with spinal stenosis (D.J. Mazanec et al, unpublished data 2002).

Though calcitonin's mechanism of action is unknown, some speculate that it acts non-specifically by raising the level of endogenous opioids (beta endorphins).^{45,46} Alternatively, others have suggested that calcitonin may improve symptoms by enhancing circulation to an ischemic cauda equina.⁴²

Flushing or nausea, the two main side effects, are seen in fewer than 5% of patients treated with calcitonin.

Epidural corticosteroid injection

Though epidural steroid injection is often suggested for control of severe radicular symptoms in patients with spinal stenosis, data supporting its efficacy are lacking.

Ciocon et al⁴⁷ did evaluate the effectiveness of caudal epidural injection in elderly patients with spinal stenosis and concluded that significant pain relief could be achieved. Based on a five-point rating scale, pain improved from a mean of 3.4 to 1.5 and was relieved for up to 10 months.

In most other studies of epidural corticosteroid injection, patients with spinal stenosis were intermingled with patients with other radicular syndromes, making it difficult to assess the outcomes. No randomized controlled trial has been performed.

■ SURGICAL TREATMENT: WHEN CONSERVATIVE THERAPY FAILS

Lumbar canal stenosis is the most frequent indication for spinal surgery in patients older than 65 years. Surgery is usually recommended when symptoms, particularly pseudoclaudication, fail to respond adequately to nonsurgical care. Surgery is almost always elective, as cauda equina syndrome is extremely rare in degenerative spinal stenosis.


A variety of surgical techniques are used, including decompressive laminectomy, with or without instrumented or noninstrumented fusion, and laminotomy.^{48,49} Microsurgical techniques are employed in an effort to reduce surgical morbidity in a frequently high-risk patient group.

**Long-term
opioids may be
an option for
frail elderly
patients**

Reported success rates of surgery vary considerably in uncontrolled trials.^{11,50–56} Reoperation rates as high as 21% have been reported.^{11,57} Across the country, rates of lumbar spine procedures for spinal stenosis vary by as much as 50%.⁴⁹

Randomized prospective controlled trials of surgical vs nonsurgical treatment are not available. Most nonrandomized comparisons suggest an advantage in surgically treated patients, at least in the short term. However, up to one third of patients treated nonsurgi-

cally also do well. Data comparing the outcomes of patients who underwent surgery earlier vs later in the disease suggest no difference in outcome.⁵⁸

The recent Maine Lumbar Spine Study,⁵⁸ a nonrandomized study comparing surgical and nonsurgical management of spinal stenosis, found that stenotic symptoms improved significantly more often in surgically treated patients than in conservatively treated patients, and that most surgically treated patients would again choose surgery. 

REFERENCES

- Spivak J. Degenerative spinal stenosis. *J Bone Joint Surg* 1998; 80:1053–1066.
- Katz J, Dalgas M, Stucki G, Lipson S. Diagnosis of lumbar canal stenosis. *Rheum Dis Clin North Am* 1994; 20:471–483.
- Garfin S, Herkowitz H, Mirkovic S. Spinal stenosis. AAOS Instructional Course Lectures 2000; 49:361–374.
- Arbit E, Pannulo S. Lumbar stenosis—a clinical review. *Clin Orthop* 2001; 384:137–143.
- Herkowitz H. Degenerative lumbar spondylolisthesis. *Spine* 1995; 20:1084–1090.
- Arnoldi C, Brodsky A, Cauchoix J. Definition and classification of lumbar spinal stenosis and nerve root entrapment syndromes. *Clin Orthop* 1976; 115:4–5.
- Bridwell K. Lumbar spinal stenosis. Diagnosis, management, and treatment. *Clin Geriatr Med* 1994; 10:677–701.
- Hall S, Bartleson J, Onofrio B, Baker H Jr, Okazaki H, O'Duffy D. Lumbar spinal stenosis—clinical features, diagnostic procedures, and result of surgical treatment in 68 patients. *Ann Intern Med* 1985; 103:271–275.
- Katz J, Dalgas M, Stucki G, et al. Degenerative lumbar spinal stenosis—diagnostic value of the history and physical examinations. *Arth Rheum* 1995; 38:1236–1241.
- Johnsson B, Stromqvist B. Symptoms and signs in degeneration of the lumbar spine. A prospective, consecutive study of 300 operated patients. *J Bone Joint Surg Br* 1993; 75:381–385.
- Turner J, Ersek M, Herron L, Deyo R. Surgery for lumbar spinal stenosis. Attempted meta-analysis of the literature. *Spine* 1992; 17:1–8.
- Mazanec D. Diagnosis and management of low back pain in older adults. *Clin Geriatr* 2000; 8:63–71.
- Deyo R, Rainville J, Kent D. What can history and physical examination tell us about low back pain? *JAMA* 1992; 268:760–765.
- Deyo R, Diehl A. Cancer as a cause of back pain—frequency, clinical presentation, and diagnostic strategies. *J Gen Intern Med* 1988; 3:230–238.
- Jensen M, Brant-Zawadki M, Obuchowski N, Modic M, Malkasian D, Ross J. Magnetic resonance imaging of the lumbar spine in people without back pain. *N Engl J Med* 1994; 331:69–73.
- Boden S, Davis D, Dina T, Patronas N, Wiesel S. Abnormal magnetic resonance scans of the lumbar spine in asymptomatic subjects. *J Bone Joint Surg Am* 1990; 72:403–408.
- Modic M, Masaryk T, Bouchphey F, Goormastic M, Bell G. Lumbar herniated disc disease and canal stenosis: prospective evaluation by surface coil MRI, CT, and myelography. *Am J Radiol* 1986; 7:709–717.
- Amundsen T, Weber H, Nordal H, Magnaes B, Abdelnoor M, Lilleas F. Lumbar spinal stenosis: conservative or surgical management? A prospective 10-year study. *Spine* 2000; 25:1424–1436.
- Johnsson KE, Rosen I, Uden A. The natural course of lumbar spinal stenosis. *Clin Orthop* 1992; 279:82–86.
- Johnsson KE. Lumbar spinal stenosis—a retrospective study of 163 cases in southern Sweden. *Acta Orthop Scand* 1995; 66:403–405.
- Bailey P, Casamayor L. Osteoarthritis of the spine as a cause of compression of the spinal cord and its roots. *J Nerve Mental Dis* 1911; 38:588–609.
- Blau JN, Logue V. The natural history of intermittent claudication of the cauda equina. *Brain* 1978; 101:211–222.
- Elsberg CA. Experiences in spinal surgery: observations upon 60 laminectomies for spinal disease. *Surg Gynecol Obstet* 1913; 16:117–132.
- Epstein JA, Epstein BS, Lavine L. Nerve root compression associated with narrowing of the lumbar spinal canal. *J Neurol Neurosurg Psychiatry* 1962; 25:165–176.
- Johnsson KE, Uden A, Rosen I. The effect of decompression on the natural course of spinal stenosis. A comparison of surgically treated and untreated patients. *Spine* 1991; 16:615–619.
- Wiltse LL, Kirkaldy-Willis WH, McLvor GWD. The treatment of spinal stenosis. *Clin Orthop* 1976; 115:83–91.
- Verbiest H. A radicular syndrome from developmental narrowing of the lumbar vertebral canal. *J Bone Joint Surg Br* 1954; 36:230–237.
- Verbiest H. Results of surgical treatment of idiopathic developmental stenosis of the lumbar vertebral canal. *J Bone Joint Surg Br* 1977; 59:181–188.
- Herno A, Airaksinen O, Saari T, Luukkonen M. Lumbar spinal stenosis: a matched-pair study of operated and nonoperated patients. *Br J Neurosurg* 1996; 10:461–465.
- Lehto MUK, Honkanen P. Factors influencing the outcome of operative treatment for lumbar spinal stenosis. *Acta Neurochir (Wien)* 1995; 137:25–28.
- Onel D, Sari H, Donmez C. Lumbar spinal stenosis: clinical/radiologic therapeutic evaluation in 145 patients. Conservative treatment or surgical intervention? *Spine* 1993; 18:291–298.
- Porter RW, Hibbert C, Evans C. The natural history of root entrapment syndrome. *Spine* 1984; 9:418–421.
- Rosomoff HL, Rosomoff RS. Nonsurgical aggressive treatment of lumbar spinal stenosis. *Spine* 1987; 1:383–400.
- Mazanec DJ, Drucker Y, Segal AM. Lumbar canal stenosis. Nonoperative approaches to treatment. *J Clin Rheumatol* 1997; 3:89–94.
- Simotas CA, Dorey JF, Hansraj KK, Cammisa F, Katz J. Nonoperative treatment for lumbar spinal stenosis. Clinical and outcome results and a 3-year survivorship analysis. *Spine* 2000; 25:197–203.
- Segal AM, Mazanec DJ, Sinks PB, et al. Lumbar canal stenosis: a nonsurgical treatment paradigm [abstract]. *Arth Rheum* 1994; 34(suppl):S239.
- Donelson RG, McKenzie R. Mechanical assessment and treatment of spinal pain. In: Frymoyer JW, editor. *The Adult Spine. Principles and Practices*. New York: Raven Press, 1991:1627–1639.
- Bradley JD, Brandt KD, Katz BP, Kalasinski LA, Ryan SI. Comparison of an antiinflammatory dose of ibuprofen, an analgesic dose of ibuprofen, and acetaminophen in the treatment of patients with osteoarthritis of the knee. *N Engl J Med* 1991; 325:87–91.



39. **American Geriatrics Society Panel on Chronic Pain in Older Persons.** The management of chronic pain in older persons. *J Am Geriatr Soc* 1998; 46:635-651.
40. **Moulin DE, Iezz A, Amirch R, et al.** Randomized trial of oral morphine for chronic non-cancer pain. *Lancet* 1996; 347:143-147.
41. **Eskola A, Pohjolainen T, Alaranta H, Soini J, Talloth K, Slati P.** Calcitonin treatment in lumbar spinal stenosis: a randomized, placebo-controlled, double-blind, cross-over study with one-year follow-up. *Calcif Tiss Int* 1992; 50:400-403.
42. **Porter RW, Hibbert C.** Calcitonin treatment for neurogenic claudication. *Spine* 1983; 5:90-93.
43. **Porter RW, Miller CG.** Neurogenic claudication and root claudication treated with calcitonin. A double-blind trial. *Spine* 1998; 13:1061-1064.
44. **Streifler J, Hering R, Gadoth N.** Calcitonin for pseudo-claudication in lumbar spinal stenosis. *J Neurol Neurosurg Psychiatry* 1989; 52:543-544.
45. **Fraioli F, Fabbri A, Gnassi L, Moretti C, Santoro C, Felici M.** Subarachnoid injection of salmon calcitonin induces analgesia in man. *Eur J Pharmacol* 1982; 78:381-382.
46. **Gennari C.** Clinical aspects of calcitonin in pain. *Triangle* 1983; 22:157-163.
47. **Ciocon JO, Ciocon DG, Amaranath L, et al.** Caudal epidural blocks for elderly patients with lumbar canal stenosis. *J Am Geriatr Soc* 1994; 42:593-596.
48. **Ciol MA, Deyo RA, Howell E, Kreif S.** An assessment of surgery for spinal stenosis: time trends, geographic variations, complications, and reoperations. *J Am Geriatr Soc* 1996; 44:285-290.
49. **Taylor VM, Deyo RA, Cherkin DC, Kreuter W.** Low back pain hospitalization: recent United States trends and regional variations. *Spine* 1994; 19:1207-1213.
50. **Ganz JC.** Lumbar spinal stenosis: postoperative results in terms of preoperative posture-related pain. *J Neurosurg* 1990; 72:71-74.
51. **Getty CJ.** Lumbar spinal stenosis: the clinical spectrum and the results of operation. *J Bone Joint Surg Br* 1980; 62:481-485.
52. **Grob D, Humke T, Dvorak J.** Degenerative lumbar spinal stenosis. *J Bone Joint Surg Am* 1995; 77:1036-1041.
53. **Herno A, Airaksinen O, Saari T.** The long-term prognosis after operation for lumbar spinal stenosis. *Scand J Rehabil Med* 1993; 25:167-171.
54. **Katz J, Lipson S, Chang L, Levine S, Fossel A, Liang M.** Seven to 10 year outcome of decompressive surgery for degenerative lumbar spinal stenosis. *Spine* 1996; 21:92-98.
55. **Katz J, Lipson S, Larson M, McInnes J, Fossel A, Liang M.** The outcome of decompressive laminectomy for lumbar stenosis. *J Bone Joint Surg* 1996; 73:809-816.
56. **Tuite GF, Doran SE, Stern JD, et al.** Outcome after laminectomy for lumbar spinal stenosis. Part II: radiographic changes and clinical correlations. *J Neurosurg* 1994; 81:707-715.
57. **Bigos S, Bowyer O, Braen G, et al.** Acute low back problems in adults. Rockville, Md: Agency for Health Care Policy and Research, Public Health Service, US Department of Health and Human Services; 1994. Clinical Practice Guideline No. 14, AHCPR Publication No. 95-0642.
58. **Atlas SJ, Keller RB, Robson D, et al.** Surgical and nonsurgical management of lumbar spinal stenosis: four-year outcomes from the Maine Lumbar Spine Study. *Spine* 2000; 25:556-562.

ADDRESS: Daniel J. Mazanec, MD, Spine Center, C21, The Cleveland Clinic Foundation, 9500 Euclid Avenue, Cleveland, OH 44195; e-mail mazaned@ccf.org.

CLEVELAND CLINIC
CENTER FOR
CONTINUING EDUCATION

Visit
Our
Website

For Information
on
Online CME
&
Upcoming Courses

- **Glaucoma Summit 2003: Visions for the Future**
January 31-February 1, 2003
- **Stress Echocardiography Workshop**
February 2-5, 2003

www.clevelandclinicmeded.com