


**MARIO E. LACOUTURE, MD**

 Section of Dermatology, University of Chicago  
Hospitals

**FRED H. HSIEH, MD**

 Section of Allergy and Immunology,  
Department of Pulmonary and Critical Care  
Medicine, The Cleveland Clinic

# Skin rash in a transplant patient receiving multiple drugs

**A** 54-YEAR-OLD MAN who has been hospitalized for 7 days for pneumonia develops a rash and fever. The rash consists of itchy red papules and macules on the trunk and extremities and is absent on his mucous membranes, palms, and soles.

## Medical history

The patient received a kidney transplant 4 months ago and has since been on immunosuppressive therapy with cyclosporine and prednisone.

One week ago he came to the emergency department reporting 5 days of dyspnea, chest tightness, nonproductive cough, fever, chills, and anorexia. He had taken antihistamines and decongestants but had not improved. At that time, he had a fever, rapid pulse, rapid respirations, and bilateral rales. His chest radiograph showed bilateral perihilar infiltrates. A sputum examination was nondiagnostic, but fiberoptic bronchoscopy with bronchoalveolar lavage demonstrated culture-positive *Pneumocystis carinii*.

The patient was hospitalized and given intravenous trimethoprim-sulfamethoxazole and subcutaneous heparin. His pulmonary symptoms improved.

## DIFFERENTIAL DIAGNOSIS

**1** What is the most likely diagnosis?

- Serum sickness
- Stevens-Johnson syndrome or toxic epidermal necrolysis
- Maculopapular or morbilliform drug rash
- Urticaria

Cutaneous adverse drug reactions occur in 2% to 3% of hospitalized patients.<sup>1</sup> Maculopapular or morbilliform drug eruptions are the most common, accounting for about 95%, whereas urticaria accounts for less than 5%,<sup>2</sup> and Stevens-Johnson syndrome, toxic epidermal necrolysis, and serum sickness account for less than 1% each.

The drugs responsible for most cutaneous adverse drug reactions are the beta-lactams, sulfonamides, and nonsteroidal anti-inflammatory drugs.<sup>3</sup> Most reactions appear within 1 week after a drug is started, except with antibiotics and allopurinol, which can cause a reaction up to 2 weeks after starting treatment.

Most reactions subside after the drug is stopped, but some do not, especially with sulfonamides, the metabolites of which are haptens—ie, they are not antigenic by themselves but become antigenic when they bind to cell-surface proteins.<sup>4,5</sup>

**Serum sickness** is a Gell-Coombs type III reaction (**TABLE 1**), in which immune complexes are deposited in tissue, causing fever, malaise, arthralgias, and red papules that erupt on the sides of the fingers, toes, and hands. Common triggers include therapeutic antisera, antibodies, and low-molecular-weight drugs such as penicillin.

**Stevens-Johnson syndrome and toxic epidermal necrolysis** are serious but rare. Sulfonamides, anticonvulsants, and allopurinol are common culprits. Eruptions on the skin and mucous membranes usually occur within 4 days of starting the drug and resemble burns (**FIGURE 1**). Patients should be treated in a burn unit; whether anti-inflammatory medications should be used is controversial.

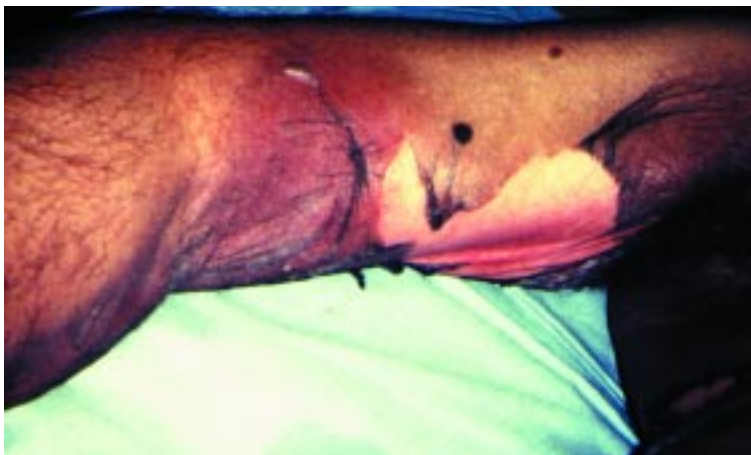**He is on cyclosporine, prednisone, heparin, and trimethoprim-sulfamethoxazole; which one is the culprit?**

TABLE 1

### Gell-Coombs classification of hypersensitivity reactions

TYPE	DESCRIPTION
I	Immediate hypersensitivity
II	Cytotoxic antibody
III	Immune complex
IV	Delayed hypersensitivity

### Toxic epidermal necrolysis



**FIGURE 1.** Toxic epidermal necrolysis. Epidermal detachment is characteristic of this entity. Mucous membranes, palms, and soles may be affected.

PHOTO COURTESY OF SHAIL BUSBEY, MD.

**Urticaria** is a Gell-Coombs type I (immediate) hypersensitivity reaction. The papules or plaques, which occur promptly after receiving the drug, are itchy, red or white, nonpitting, round or oval, edematous, and surrounded by a clear or red halo. Treatment consists of histamine-1 blockers; if anaphylaxis develops, emergency treatment is essential.

**Maculopapular or morbilliform drug rash**, the most likely diagnosis in this patient, occurs within the first week after drug exposure. It begins as erythematous macules or papules on the trunk or areas of pressure or trauma, sparing the mucous membranes, palms, and soles. Within hours or days, the macules and papules coalesce and become confluent and symmetrical (FIGURE 2), and they may persist for up to 2 weeks. Fever and pruri-

tus may be present.

This type of reaction may mimic a skin rash from viral illness.<sup>4</sup> The lesions may fade even if the drugs are continued and may not reappear with subsequent exposures. The immunologic mechanisms are unknown, and skin testing has little role in diagnosing it.

### ■ ESTABLISHING THE DIAGNOSIS

**2** What tests would be useful to establish the diagnosis?

- Blood eosinophil counts
- Rechallenge with a test dose
- Skin biopsy
- No testing

The skin and serum tests that are clinically available are useful only for diagnosing cutaneous adverse drug reactions that are allergic, ie, mediated by antigen-specific immunoglobulin E (IgE) (Gell-Coombs type I reaction). Maculopapular cutaneous adverse drug reactions are not mediated by IgE.

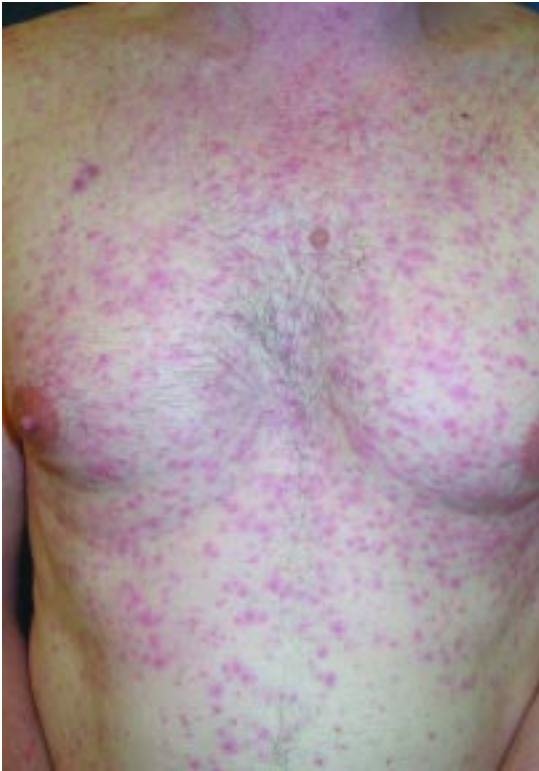**Eosinophil counts** are not very useful for diagnosing drug reactions. Although eosinophilia has been reported in patients with drug reactions, the evidence is weak. Recent studies found eosinophil counts to have low sensitivity: 22% to 36%, depending on arbitrarily defined cutoff rates.<sup>6</sup>

**Rechallenge with a test dose** of the drug in question is rarely done to establish the cause of a maculopapular cutaneous adverse drug reaction because it poses the risk of a severe skin reaction. It is contraindicated if a serious systemic reaction has occurred (TABLE 2), and if done, it must be done with caution. Also, the response to a challenge may not be consistent if the reaction is idiosyncratic or due to intolerance. Nevertheless, it is often the only definitive method of determining if a particular drug was the cause of a cutaneous adverse drug reaction.

**Skin biopsy** can clarify the type of skin reaction and the mechanism (eg, by demonstrating immune complexes, leukocytoclastic vasculitis, or eosinophilia). However, often it helps neither to determine whether the cutaneous reaction is drug-induced nor to identify the causative agent.<sup>7</sup>



## Maculopapular or morbilliform rash



**FIGURE 2.** Maculopapular or morbilliform rash is the most common type of cutaneous adverse drug reaction. It usually involves the trunk and extremities, sparing the palms and soles.

PHOTO COURTESY OF KEYOUNAR SOLTANI, MD.

No testing is needed for this patient or most patients with a maculopapular drug rash. However, if certain organs are thought to be affected, one can obtain laboratory tests to assess the function of those organs, such as blood urea nitrogen and creatinine levels if kidney involvement is suspected.

### ■ IDENTIFYING THE CULPRIT

**3** What drug most likely caused the reaction in this patient?

- Heparin
- Trimethoprim-sulfamethoxazole
- Cyclosporine
- Prednisone

In a suspected cutaneous adverse drug reaction, it is essential to carefully examine the

**TABLE 2**

## Signs of a severe systemic drug reaction

### Systemic findings

- High fever (> 40°C, 104°F)
- Lymphadenopathy
- Arthralgias
- Dyspnea, wheezing, hypotension

### Dermatologic findings

- Confluent erythema
- Facial edema or facial rash
- Tender skin lesions
- Palpable purpura
- Necrotizing skin lesions
- Vesicles, bullae, or epidermal detachment
- Nikolsky sign (outer layer of epidermis separates readily with lateral pressure)
- Mucous membrane erosions
- Urticaria
- Tongue edema

### Laboratory findings

- Abnormal liver function tests
- Lymphocytosis with atypical lymphocytes
- Eosinophil count > 1,000/mm<sup>3</sup>

patient and his or her clinical history and medical records. What did the patient receive, and when? What type of reaction occurred, and when, and is the physical and temporal pattern consistent with the adverse-reaction profile of the suspect drug?

**Sulfamethoxazole** (in trimethoprim-sulfamethoxazole) is the most likely culprit in this case. It is a frequent cause of cutaneous drug reactions, and the timing is consistent: the patient started taking it 1 week before the rash developed. No skin test for sulfonamides is available because the drug's metabolism is complex and data are lacking on the clinically important immunogens.

The trimethoprim component of trimethoprim-sulfamethoxazole, in contrast, rarely causes cutaneous reactions.

Once a patient has had a reaction to a sulfonamide antimicrobial drug, will he or she also have reactions to other sulfa-containing compounds such as furosemide, thiazide diuretics, or celecoxib? The data conflict on this point,<sup>8</sup> and an adverse reaction to sulfamethoxazole should not necessarily preclude the cautious use of these other agents.

**Heparin-induced** adverse reactions include localized urticaria, anaphylaxis, and thrombocytopenia—but not often a maculopapular rash. Cross-reactivity between unfractionated heparin and low-molecular-weight heparin has been described for type IV (delayed-type hypersensitivity) cutaneous adverse drug reactions.<sup>9</sup>

**Cyclosporine and prednisone** are not typically associated with maculopapular eruptions. Side effects of cyclosporine include hirsutism, gingival hyperplasia, and coarsening of facial features. Prednisone may cause acne soon after starting treatment, and also delayed effects such as cushingoid features, impaired wound and fracture healing, and skin atrophy.

#### ■ COURSE OF ACTION

#### 4 What should be done next?

- Stop cyclosporine and prednisone
- Stop trimethoprim-sulfamethoxazole
- Give antihistamines or intravenous steroids or both, and continue trimethoprim-sulfamethoxazole
- Desensitize the patient to trimethoprim-sulfamethoxazole

**Stopping cyclosporine and prednisone** would not be a good idea. These immunosuppressant drugs probably did not cause his reaction: the temporal relationship is wrong (he started the drugs nearly 4 months before the reaction developed), and they rarely cause maculopapular rashes. Furthermore, the risk of transplant rejection would be high. These drugs should be continued unless signs of a life-threatening or severe reaction develop (TABLE 2).

**Stopping trimethoprim-sulfamethoxazole** is the safest option. Although sulfa drugs may be necessary to prevent and treat serious infections in immunosuppressed patients, they must be discontinued if the patient has:

- Rash or fever for more than 5 days
- Neutrophil count less than 500/mm<sup>3</sup>
- Hypotension
- Dyspnea
- Blistering
- Mucous membrane involvement.


**Giving antihistamines and steroids** concurrently with trimethoprim-sulfamethoxazole is generally not recommended because antihistamines and steroids could mask a serious reaction. However, systemic steroids and antihistamines can permit continued sulfa therapy<sup>10</sup> and could be considered on a case-by-case basis, taking into account whether the medication is critical for the patient's survival, whether other antimicrobials are available, the severity of the patient's drug reaction, and the risk of Stevens-Johnson syndrome or toxic epidermal necrolysis.

**Desensitization** is performed if no reasonable alternative agent exists. In general, maculopapular reactions are not amenable to desensitization, but trimethoprim-sulfa-methoxazole is an exception. Since the mortality rate in renal transplant recipients with *P carinii* pneumonia is nearly 50%,<sup>11</sup> and trimethoprim-sulfamethoxazole offers the best chance of survival, this patient should undergo desensitization to allow him to continue to receive it.

Desensitization should be performed under the supervision of a specialist in a controlled setting with appropriate emergency medications and equipment. Safe and effective protocols have been developed to desensitize immunosuppressed patients, such as AIDS patients, to trimethoprim-sulfamethoxazole.<sup>12</sup>

Desensitization works by exhausting the body's ability to react to a certain drug. The effect is temporary, and it must be repeated each time another course of the drug is needed.<sup>13,14</sup> Nevertheless, desensitization allows a course of therapy to be completed, and the drug can be continued prophylactically after acute treatment if therapy is not interrupted.

#### Case continued

The patient is desensitized to trimethoprim-sulfamethoxazole in the hospital and completes his course of therapy. At the end of therapy his symptoms have resolved, and his pulmonary infiltrates have cleared. The rash clears on day 14. Trimethoprim-sulfamethoxazole is continued for *P carinii* prophylaxis. The dosage is trimethoprim 160 mg and sulfamethoxazole 800 mg (one Bactrim DS tablet) daily. 

**Mortality in renal transplant patients with *P carinii* pneumonia is nearly 50%**



## ■ REFERENCES

1. **Bigby M.** Incidence, prevalence and the rates of cutaneous reactions to drugs. *J Eur Acad Dermatol Venerol* 2000; 14:435–440.
2. **Bigby M.** Rates of cutaneous reactions to drugs. *Arch Dermatol* 2001; 137:765–770.
3. **Hunziker T, Kunzi UP, Braunschweig S, Zehnder D, Hoigne R.** Comprehensive hospital drug monitoring (CHDM): adverse skin reactions, a 20-year survey. *Allergy* 1997; 52:388–393.
4. **Wintroub BU, Stern R.** Cutaneous drug reactions: pathogenesis and clinical classification. *J Am Acad Dermatol* 1985; 13:167–179.
5. **Meekins CV, Sullivan TJ, Gruchalla RS.** Immunochemical analysis of sulfonamide drug allergy: identification of sulfamethoxazole-substituted human serum proteins. *J Allergy Clin Immunol* 1994; 94:1017–1024.
6. **Berman B, Villa AM.** Is eosinophilia helpful in diagnosing drug eruptions? *Skin Med* 2002; 1:147–148.
7. **Rojeau JC, Stern RS.** Severe adverse cutaneous reactions to drugs. *N Engl J Med* 1994; 331:1272–1285.
8. **Knowles S, Shapiro L, Shear NH.** Should celecoxib be contraindicated in patients who are allergic to sulfonamides? Revisiting the meaning of “sulfa” allergy. *Drug Saf* 2001; 24:239–247.
9. **Grassegger A, Fritsch P, Reider N.** Delayed-type hypersensitivity and cross-reactivity to heparins and dapsarinoid: a prospective study. *Dermatol Surg* 2001; 27:47–52.
10. **Boxer MB, Dykewicz MS, Patterson R, Greenberger PA, Kelly JF.** The management of patients with sulfonamide allergy. *N Engl Reg Allergy Proc* 1988; 9:219–223.
11. **EBPG Expert Group on Renal Transplantation.** European best practice guidelines for renal transplantation. Section IV: Long-term management of the transplant recipient. IV.7.1 Late infections. *Pneumocystis carinii* pneumonia. *Nephrol Dial Transplant* 2002; 17(suppl 4):36–39.
12. **Rich JD, Sullivan T, Greineder D, Kazanjian PH.** Trimethoprim/sulfamethoxazole incremental dose regimen in human immunodeficiency virus-infected persons. *Ann Allergy Asthma Immunol* 1997; 779:409–414.
13. **Tilles SA.** Practical issues in the management of hypersensitivity reactions: sulfonamides. *South Med J* 2001; 94:817–824.
14. **Gruchalla RS.** Diagnosis of allergic reactions to sulfonamides. *Allergy* 1999; 54(suppl 58):28–32.

ADDRESS: Fred H. Hsieh, MD, Section of Allergy and Immunology, Department of Pulmonary and Critical Care Medicine, The Cleveland Clinic Foundation, A72, 9500 Euclid Avenue, Cleveland, OH 44195.



## CME ANSWERS

Answers to the credit test on page 1095 of this issue

1 B 2 A 3 C 4 B 5 B 6 D 7 D 8 C 9 C 10 D 11 C 12 E

# CCJM Is Now Accepting Professional Classified Advertising

Let our national distribution to 97,000+ internists, cardiologists, nephrologists, and endocrinologists help you land the perfect job candidate.

**See the inside  
back cover  
for rates and  
details**

