

RAFFI GURUNLUOGLU, MD

Microsurgery Laboratory, Department of Plastic and Reconstructive Surgery, The Cleveland Clinic

TEOMAN DOGAN, MD, PhD

Department of Plastic and Reconstructive Surgery, Marmara University School of Medicine, Altunizade-Istanbul, Turkey

KEVIN CARNEVALE, MD

Department of Cell Biology, The Cleveland Clinic

An 18-year-old man with swelling in his left thumb

AN 18-YEAR-OLD MAN from Turkey is referred for evaluation of a painless swelling in his left thumb, present for 1 year. He also has mild pain in the wrist. His younger brother had pulmonary tuberculosis 3 years ago. The patient has no history of trauma or previous arthritis.

Physical examination

The patient is afebrile. He has a mild to moderate swelling of the left thumb and an ill-defined palpable enlargement (4 × 1 cm) in the wrist that is not visible grossly. The thumb and wrist are tender to palpation and painful on movement against resistance.

Absent are signs suggestive of median nerve compression at the wrist, ie, the Tinel sign (a tingling sensation in the fingers in the distribution of the median nerve with percussion over the median nerve) or the Phalen sign (reproduction of pain with hyperflexion or hyperextension of the wrist). The rest of the physical examination is unremarkable.

Radiographic and laboratory studies

A purified protein derivative (PPD) test is positive (20 mm), but a chest radiograph shows no signs of pulmonary tuberculosis. The patient is negative for human immunodeficiency virus (HIV) and is neither immunocompromised nor on any immunosuppressive medications.

Laboratory tests reveal only an elevated C-reactive protein (CRP) level (1.0 mg/dL, normal value < 0.7) and sedimentation rate (25 mm/hour, normal value < 20).

Standard radiographs of thumb and wrist show normal bony structures and articular surfaces. However, there is a minor increase in soft tissue density in the volar aspect of the

thumb starting from the distal phalanx and extending to the proximal.

Magnetic resonance imaging (MRI) shows thickening of the tenosynovium of the flexor pollicis longus, extending from the middle of the distal phalanx proximally up to the level of the scaphoid bone, involving the radial bursa (FIGURE 1). The osseous and articular structures are otherwise normal.

DIFFERENTIAL DIAGNOSIS

1 What is the cause of the tenosynovitis in this patient?

- Tuberculosis
- Nontuberculous mycobacteria
- Fungi
- Rheumatoid arthritis
- Foreign body reaction
- Sarcoidosis
- Gout

A number of causes of tenosynovitis can be considered in the differential diagnosis of this case.

Tuberculosis

Our patient's clinical findings in the hand, positive PPD test, elevated sedimentation rate, elevated CRP level, and normal chest radiographic findings strongly suggest extrapulmonary involvement with mycobacteria.

Worldwide, tuberculosis remains very common, although its incidence is declining in developed countries. Mycobacterial infections are common in people with HIV infection (with or without acquired immunodeficiency syndrome), and HIV infection significantly increases the frequency and severity of mycobacterial infections. Therefore, the HIV

Findings:

- Positive PPD
- Negative chest x-ray
- CRP 1.0
- Sedimentation rate 25



status of a patient suspected of having a mycobacterial infection should always be checked.^{1,2}

Mycobacterium tuberculosis is transmitted through aerosolized secretions. Our patient probably contracted the bacilli from his brother. During the initial encounter, the bacilli disseminate until the host's immune response is sufficient to cause involution of these foci. Most cases of extrapulmonary tuberculosis, including tenosynovitis, seem to result from reactivation of latent disease.³

Inoculation of tuberculous mycobacteria can also occur through the skin of the hand, although these cases are too few to assume that this is the usual portal of entry. Closed trauma is also of doubtful importance.

Tuberculous tenosynovitis occurs usually as the only apparent lesion in the body, often shows a low degree of virulence, and tends to yield to curative measures. The incidence is greatest in the third and fourth decades, and is slightly higher in men.

Only occasionally does the tuberculosis bacillus show an affinity for the tendon sheaths of the hand.⁴⁻⁹ The right hand is affected about twice often as is the left, for unknown reasons.⁸

The course of the disease is slow and insidious, and the earliest symptoms noticed are swelling, mild pain if any, weakness of grip, and limitation of motion. Fever and general symptoms are usually absent.⁸

Tuberculous tenosynovitis usually presents as carpal tunnel syndrome, although any type of tendon-sheath involvement can be encountered in the hand.^{9,10-12} The carpal tunnel is bounded by the carpal bones and the flexor retinaculum (transverse carpal ligament), through which pass the median nerve, the long flexors of the fingers, and the long flexor tendon of the thumb (superficial and deep flexor tendons, and flexor pollicis longus tendon).

Carpal tunnel syndrome associated with tuberculous tenosynovitis is due to inflammation and increased pressure in the tunnel, leading to inflammation and compression of the median nerve. Weakness and clumsiness in the use of the thumb, pain in the palm and the palmar aspect of the wrist, and paresthesias and sensory loss in the distribution of median nerve are the typical symptoms.

Tenosynovitis of the thumb: MRI study

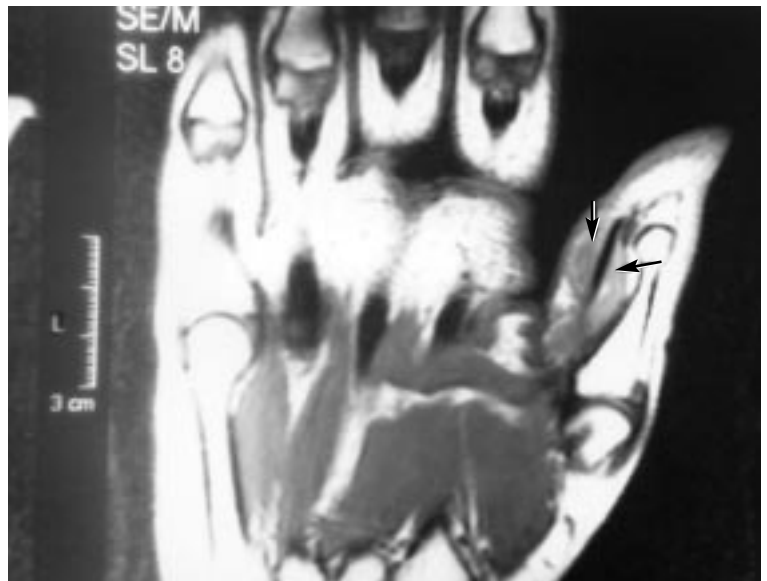


FIGURE 1. Magnetic resonance imaging scan, coronal section that passes through the midvolar level of the left thumb. Arrows indicate the increased volume in the tenosynovium of the flexor pollicis longus at the proximal phalanx.

Isolated disease involving the flexor sheaths of the fingers, such as the case presented here, is very rare.^{8,9} The tuberculous process usually starts in the tendon sheath, but in advanced cases it may spread to the bone or joints.^{13,14} Tuberculosis might produce severe dactylitis, which causes enlarged fingers that show proliferation of the subperiosteal reaction of the phalanges on radiographs and can involve adjacent joints.

A number of types of granulomatous tenosynovitis are similar to tuberculous tenosynovitis both clinically and histologically, however, and should be considered in the differential diagnosis. Thus, patients suspected of having tenosynovitis due to *M tuberculosis* should be referred to a specialist for further investigation, since the definitive diagnosis can only be made after surgery or biopsy.

Nontuberculous mycobacteria

Among a variety of agents that can cause granulomatous tenosynovitis are nontuberculous mycobacteria, most commonly *M marinum*, followed by *M kansasii*. Patients often have a history of a penetrating wound in a marine environment or during farm activity.¹⁵⁻¹⁸

Always check the HIV status of a patient with suspected mycobacterial infection

M marinum is an important cause of digital tenosynovitis. Sources include contaminated swimming pools, fish tanks (fish tank granuloma), piers, boats, fish bites, and fish spines.

To diagnose this infection, one must first suspect it, obtain a thorough history with emphasis on possible exposure to *M marinum*, be aware that inoculation can occur in seemingly trivial trauma, and obtain tissue for culture and histologic examination.

The definitive diagnosis of nontuberculous mycobacterial tenosynovitis is established by culturing a synovial biopsy specimen on Lowenstein-Jensen medium at 30°C and 32°C, temperatures that are lower than the usual incubation temperatures for *M tuberculosis*. Since special techniques are necessary for optimal isolation of *M marinum*, the physician submitting the specimen should inform the microbiology laboratory of the suspected diagnosis.

Microscopically, one sees nonnecrotizing granulomas. In contrast, necrotizing granulomas are typical for tuberculosis.

The PPD test may be negative in patients with *M marinum* infections. Acid-fast bacilli may or may not be identified with Ziehl-Neelsen stain.

Fungal infection

Coccidioides or *Sporothrix* infections occasionally cause granulomatous tenosynovitis.

Coccidioidomycosis affects the hands in only a small proportion of cases, either primarily through a break in the skin or secondarily, and usually in immunosuppressed patients.^{19,20} Coccidioid tenosynovitis resembles tuberculosis in many respects, even having rice bodies.

The coccidioidin skin test and the complement fixation test help confirm the diagnosis. However, the coccidioidin skin test has a very limited role in the diagnosis of active cocci infection and is more useful for epidemiologic studies. Cocci skin tests generally remain positive for life after the initial infection, so many persons from areas where coccidioidomycosis is common have positive skin tests, which does not help with the diagnosis of an acute tenosynovitis.

In a few reported cases, tenosynovitis due

to *S schenckii* mimicked rheumatoid and tuberculous tenosynovitis. These reports stress the importance of obtaining repeated fungal cultures from patients with granulomatous synovitis.²¹⁻²³

Histologic examination of the tissue involved with fungal infection reveals tenosynovitis characterized by a necrotizing granulomatous inflammation. Fungal culture is the definitive diagnostic test. The complement fixation test is adjunctive, and the coccidioidin skin test is of limited value.

Rheumatoid arthritis

Many patients with tuberculosis are first diagnosed with rheumatoid arthritis or nonspecific synovitis. Although rheumatoid disease primarily involves the joints, the tendons on both the dorsal and volar surfaces of the hands and wrist are involved in half of cases.^{24,25}

Rheumatoid arthritis is a disease of the synovium. The synovium-lined sheaths that surround many of the tendons of the hand and wrist can be affected by proliferative synovitis in the same way as the synovium-lined joint spaces. Tendon sheath involvement can occur months before the symptoms of intra-articular disease are noted.

Rheumatoid tenosynovitis is usually multifocal. A single anatomic region can be involved in rare cases, although it is hard to estimate the frequency.²⁶ Thus, it should be considered in the differential diagnosis of digital tenosynovitis. Rheumatoid tenosynovitis can cause pain, tendon dysfunction, and ultimately tendon rupture.²⁷

At surgery, if the tenosynovitis is more extensive and adherent than one would normally see in a rheumatoid patient, the diagnosis of tuberculosis should be considered. Rice bodies can also occur with rheumatoid involvement of the hand. Thus, it is vital to obtain specimens for culture and sections at the time of surgery.

Foreign body reaction

Swellings on the volar surface of the hand or fingers may also result from tissue reaction to a foreign body. In these cases, there is usually a history of injury, often penetrating.

The foreign body sometimes cannot be seen radiographically, owing to the material of



which it is composed. Microscopically, the foreign body is found to be within a dense fibrous tissue capsule, and numerous foreign body giant cells can be seen.^{8,28}

Sarcoidosis

Sarcoidosis is a multisystem granulomatous disease in which the lungs and hilar lymph nodes are the most commonly involved organs, but any tissue can be affected. Sarcoid tenosynovitis is rare, and only a few cases have been reported.²⁹

Varied clinical manifestations in the upper extremities may include extensor and flexor tenosynovitis, which may occur with or without radiographic evidence of hilar lymphadenopathy.^{30,31}

Histologically, the tissue specimen contains numerous noncaseating, nonnecrotic granulomas, in contrast to the caseating, necrotic granulomas of tuberculosis.

Gouty tenosynovitis

Occasionally, what is thought to be tuberculous tenosynovitis may prove to be due to gout, especially when acid-fast stains and cultures are negative for mycobacteria. Gouty arthritis with tenosynovitis can occur with a normal, elevated, or low uric acid level, and the diagnosis is based on the presence of monosodium urate crystals within the tendon sheath or the joint.³²

The usual preparation of biopsy specimens does not dissolve the crystals; thus, one might miss crystal-induced tenosynovitis unless the specimen is processed in a special way.

■ CONFIRMATORY TESTS

2 How would you confirm the diagnosis of tuberculous tenosynovitis in this patient?

- History of exposure to tuberculosis
- Purified protein derivative (PPD) test
- Biopsy of the tenosynovium
- Culture of the tissue specimen
- Staining of direct smears

The initial diagnosis is based on demonstrating necrotizing granulomas histologically in a biopsy specimen. Occasionally, however, patients with nontuberculous inflammatory disease have granulomas with a necrotizing

component. Thus, the definitive diagnosis depends on identifying the tuberculous bacilli on Lowenstein-Jensen culture medium.

Extrapulmonary tuberculosis is difficult to diagnose. One should start with a high index of suspicion and a thorough history. In tuberculous tenosynovitis there is often a delay between the onset of symptoms and the correct diagnosis.

Cultures can differentiate the species of mycobacteria, but take 6 or more weeks to grow niacin-positive *M tuberculosis*. More rapid techniques for identification of *M tuberculosis* include inoculation into Bactec vials (BD, Franklin Lakes, NJ), which many micro-labs use routinely,^{33,34} and use of molecular probes.^{35,36}

Inability to demonstrate acid-fast bacilli on Ziehl-Neelsen smears does not rule out mycobacterial infection.

The PPD test may be falsely negative in immunocompromised and debilitated patients or in patients on immunosuppressive medication.

■ MANAGEMENT

3 How would you manage this patient?

- Exploration of the finger and the wrist
- Tenosynovectomy and carpal tunnel decompression
- Combination of antituberculous chemotherapy after the histological confirmation of the necrotizing granulomas
- Physical therapy within 2 to 3 days following the surgery

All of the above are indicated. Surgical debridement in conjunction with antibiotic therapy is recommended as opposed to percutaneous drainage.¹⁷

Case continued

The patient undergoes surgery. Following axillary block and pneumatic tourniquet application, the left thumb is approached through a volar zigzag incision, extending from the tip to the flexion crease of metacarpophalangeal joint. The carpal tunnel is also opened to explore the palpable mass in the wrist and to decompress possible median nerve compression.

The PPD test can be falsely negative in immunocompromised patients

Necrotizing granuloma

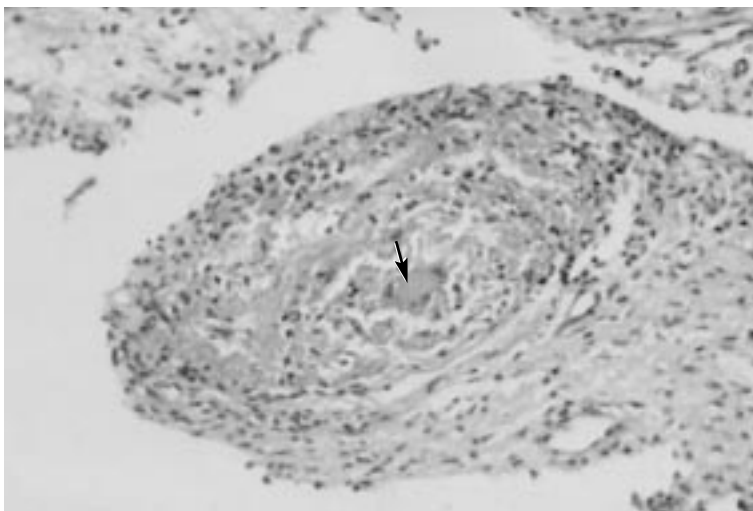


FIGURE 2. Photomicrograph of the surgical specimen. Necrotizing granuloma with a giant cell (arrow) in the center (hematoxylin and eosin, $\times 200$).

On exploration, the sheath of the flexor pollicis longus tendon and of the radial bursa is thick and hypertrophic. There are no rice bodies. Tenosynovectomy is performed. The

operative incisions are closed primarily.

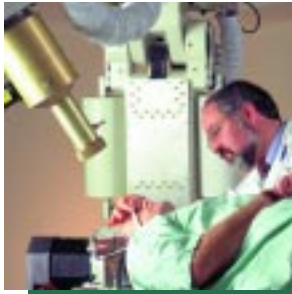Tissue obtained at operation is sent for routine histologic and microbiologic studies. Special stains for acid-fast bacilli (Ziehl-Neelsen) and fungi are also done. Tissue for culture is incubated in Lowenstein-Jensen media at 30°C and 37°C. Acid-fast stain reveals no bacilli. The tissue cultures grow niacin-positive *M tuberculosis* in 7 weeks. Microscopic examination of the surgical specimen shows necrotizing granulomas (FIGURE 2).

The decision to begin antimycobacterial therapy is usually made on the basis of clinical and histologic findings rather than bacteriologic findings. The patient is treated with pyrazinamide 500 mg three times a day, isoniazid 300 mg daily, rifampin 300 mg twice a day, ethambutol 500 mg three times a day, and supplemental B vitamins for 6 months. Physical therapy is started 2 or 3 days following the surgery to avoid disability due to tendon adherence.

Acknowledgment. We would like to thank Maria Siemionow, MD, PhD, Director of Plastic Surgery Research, for her contribution to the paper.

REFERENCES

1. Sepkowitz KA. Opportunistic infections in patients with and patients without acquired immunodeficiency syndrome. *Clin Infect Dis* 2002; 34:1098–1107.
2. Porco TC, Small PM, Blower SM. Amplification dynamics: predicting the effect of HIV on tuberculosis outbreaks. *J AIDS* 2001; 28:437–444.
3. Karanas YL, Yim KK. Mycobacterium tuberculosis infection of the hand: a case report and review of the literature. *Ann Plast Surg* 1998; 40:65–67.
4. Kanavel AB. Tuberculous tenosynovitis of the hand. *Surg Gynecol Obstet* 1923; 37:635–647.
5. Mason ML. Tuberculous tenosynovitis of the hand. *Surg Gynecol Obstet* 1934; 59:363–396.
6. Adams R, Jones G, Marble HC. Tuberculous tenosynovitis. *N Engl J Med* 1940; 223:706–708.
7. Bickel WH, Kimbrough RF. Tuberculous tenosynovitis. *JAMA* 1953; 151:31–35.
8. Bunnell S. Surgery of the hand. In: Bunnell S, editor. *Special Infections of the Hand*, 3rd ed. Philadelphia: J.B. Lippincott Company, 1956:863–891.
9. Robins RHC. Tuberculosis of the wrist and hand. *Br J Surg* 1967; 54:211–218.
10. Kloforn RW, Steigerwald JC. Carpal tunnel syndrome as the initial manifestation of tuberculosis. *Am J Med* 1976; 60:583–586.
11. Suso S, Peidro L, Ramon R. Tuberculous synovitis with “rice bodies” presenting as carpal tunnel syndrome. *J Hand Surg (Am)* 1988; 13:4:574–576.
12. Regnard PJ, Barry P, Isselin J. Mycobacterial tenosynovitis of the flexor tendons of the hand. Report of five cases. *J Hand Surg (Br)* 1996; 21(3):351–354.
13. Leung PC. Tuberculosis of the hand. *Hand* 1978; 10:285–291.
14. Bush DC, Schneider LH. Tuberculosis of the hand and wrist. *J Hand Surg (Am)* 1984; 9(3):391–398.
15. Hurst LC, Amadio PC, Badalamente MA, et al. Mycobacterium marinum infections of the hand. *J Hand Surg (Am)* 1987; 12(3):428–435.
16. Neviasser RJ. Tenosynovitis. *Hand Clin* 1989; 5:525–531.
17. Neviasser RJ. Infections. In: Green DP, Hotchkiss RN, editors. *Operative Hand Surgery*, 3rd ed. New York: Churchill Livingstone, 1993:1021–1038.
18. Hellinger WC, Smilack JD, Greider JL, et al. Localized soft-tissue infections with mycobacterium avium/mycobacterium intracellulare complex in immunocompetent patients: granulomatous tenosynovitis of the hand or wrist. *Clin Infect Dis* 1995; 21:65–69.
19. Gropper PT, Pisesky WA, Bowen V, Clement PB. Flexor tenosynovitis caused by *Coccidioides immitis*. *J Hand Surg [Am]* 1983; 8(3):344–347.
20. Reid GD, Klinkhoff A, Bozek C, Denegri JF. Coccidioidomycosis tenosynovitis: case report and review of the literature. *J Rheumatol* 1984; 11:392–394.
21. Stratton CW, Lichtenstein KA, Lowenstein SR, Phelps DB, Reller LB. Granulomatous tenosynovitis and carpal tunnel syndrome caused by *Sporothrix schenckii*. *Am J Med* 1981; 71:161–164.
22. Hay EL, Collawn SS, Middleton FG. *Sporothrix schenckii* tenosynovitis: a case report. *J Hand Surg (Am)* 1986; 11:431–434.
23. Schwartz DA. *Sporothrix* tenosynovitis: differential diagnosis of granulomatous inflammatory disease of the joints. *J Rheumatol* 1989; 16:550–553.
24. Wilson RL, DeVito MC. Extensor tendon problems in rheumatoid arthritis. *Hand Clin* 1996; 12:551–559.
25. Tolat AR, Stanley JK, Evans RA. Flexor tenosynovectomy and tenolysis in longstanding rheumatoid arthritis. *J Hand Surg (Br)* 1996; 21:538–543.
26. Gray RG, Gottlieb NL. Hand flexor tenosynovitis in rheumatoid arthritis. Prevalence, distribution, and associated




LET US HEAR FROM YOU

- Let us hear your opinions about the *Cleveland Clinic Journal of Medicine*.
- Do you like current articles and sections?
- What topics would you like to see covered and how can we make the Journal more useful to you?

PHONE 216.444.2661
FAX 216.444.9385
E-MAIL ccjm@ccf.org
WWW <http://www.ccjm.org>

CLEVELAND CLINIC JOURNAL OF MEDICINE
The Cleveland Clinic Foundation
9500 Euclid Avenue, NA32
Cleveland, Ohio 44195



GURUNLUOGLU AND COLLEAGUES



- rheumatic features. *Arth Rheum* 1977; 20:1003-1008.
27. Ferlic DC. Rheumatoid flexor tenosynovitis and rupture. *Hand Clin* 1996; 12:561-572.
 28. Freund EI, Weigl K. Foreign body granuloma. A cause of trigger thumb. *J Hand Surg (Br)* 1984; 9:210.
 29. Merle M, Bour C, Foucher G, et al. Sarcoid tenosynovitis in the hand: a case report and literature review. *J Hand Surg (Br)* 1986; 11:281-286.
 30. Gonzalez del Pino J, Diez Ulloa A, Lovic A, et al. Sarcoidosis of the hand and wrist: a report of two cases. *J Hand Surg (Am)* 1997; 22:942-945.
 31. Katzman BM, Caligiuri DA, Klein DM, et al. Sarcoid flexor tenosynovitis of the wrist: a case report. *J Hand Surg (Am)* 1997; 22:336-337.
 32. Kostman JR, Rush P, Reginato AJ. Granulomatous tophaceous gout mimicking tuberculous tenosynovitis: report of two cases. *Clin Infect Dis* 1995; 21:217-219.
 33. Desmond EP, Loretz K. Use of the Gen-Probe amplified mycobacterium tuberculosis direct test for early detection of *Mycobacterium tuberculosis* in BACTEC 12B medium. *J Clin Microbiol* 2001; 39:1993-1995.
 34. Jayakumar KV, Forster T, Kyi MS. Improved detection of *Mycobacterium* species using the Bactec MGIT 960 system. *Br J Biomed Sci* 2001; 58:154-158.
 35. Woods GL. Molecular methods in the detection and identification of mycobacterial infections. *Arch Pathol Lab Med* 1999; 123:1002-1006.
 36. Soini H, Musser JM. Molecular diagnosis of mycobacteria. *Clin Chem* 2001; 47:809-814.

ADDRESS: Raffi Gurunluoglu, MD, Department of Plastic and Reconstructive Surgery, Leopold-Franzens University, Anichstrasse 35, 6020, Innsbruck, Austria; e-mail Raffi.Gurunluoglu@uibk.ac.at.

CCJM Is Now Accepting Professional Classified Advertising

Let our national distribution to 97,000+ internists, cardiologists, nephrologists, and endocrinologists help you land the perfect job candidate.

**See page 270
for rates and details**