



FABIANE MULINARI-BRENNER, MD

International Scholar, Departments of Dermatology and Pathology, The Cleveland Clinic

WILMA F. BERGFELD, MD

Head, Clinical Research, Department of Dermatology, The Cleveland Clinic

Hair loss: Diagnosis and management

■ ABSTRACT

Alopecia is usually treatable and self-limited, but it may be permanent. Careful diagnosis of the type of hair loss will aid in selecting effective treatment. Reassurance is an important component of any treatment regimen.

■ KEY POINTS

Most alopecia is noncicatricial, meaning it is potentially reversible. Subtypes include androgenetic alopecia, telogen effluvium, alopecia areata, and traction alopecia.

To treat telogen effluvium, the cause or causes must be isolated and treated. Patients should always be reassured that their hair is being replaced, and that the chances of becoming bald are remote.

Hair shaft abnormalities produce fragile or brittle hair. Causes include traction, bleaching, perming, or blow-drying.

Tight braids, ponytails, elastic hair bands, rollers, or other devices that place extreme and repetitive stress on the scalp hair are responsible for most cases of traction alopecia.

ALOPECIA IS DISTRESSING to patients because of its effect on appearance, but the problem is often more than skin deep. We physicians should not underestimate its importance, either as a cosmetic problem or as a sign of a potentially serious underlying condition.

In most cases, alopecia is best managed with reassurance and education, but other cases require medical evaluation and therapy. The evaluation includes a personal and family history, physical examination, and sometimes laboratory testing.

In this article, we give a brief overview of the primary care management of the various types of hair loss.

■ TYPES OF HAIR LOSS

Most hair loss can be categorized into three types:

- Noncicatricial (potentially reversible)
- Cicatricial
- Due to hair shaft abnormalities.

■ NONCICATRICAL ALOPECIA

Noncicatricial alopecia, in turn, has several subtypes:

- Telogen effluvium (shedding)
- Androgenetic alopecia (common baldness)
- Alopecia areata (isolated or recurrent patchy hair loss)
- Traction alopecia (caused by pulling hair), and trichotillomania (compulsive hair-plucking). Although these cause temporary hair loss, in chronic cases trauma can affect the follicle stem cells, ie, the middle portion of the hair follicle, producing scarring and permanent hair loss.¹

Androgenetic alopecia

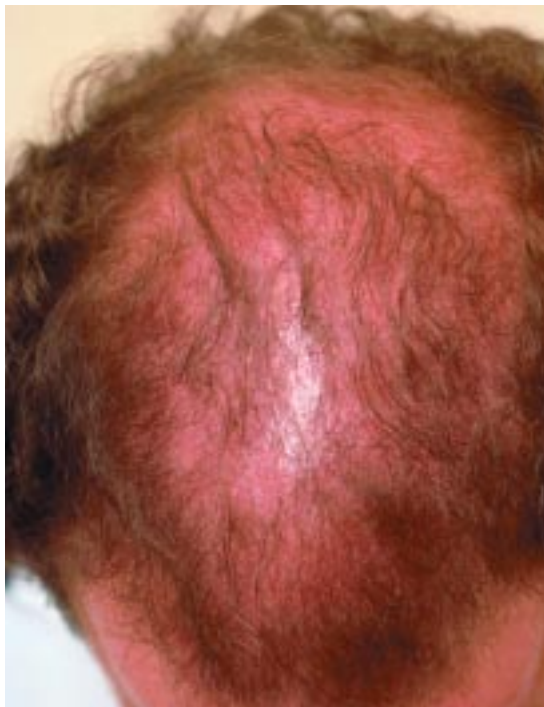
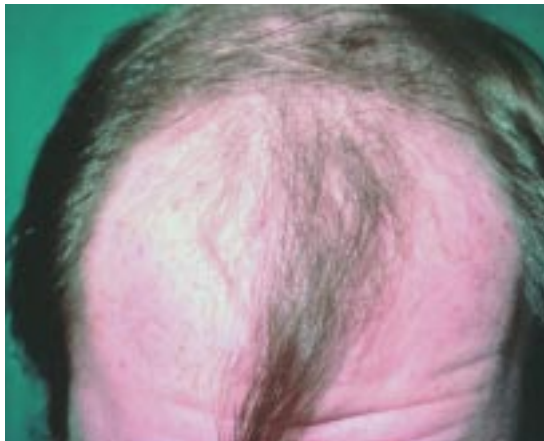
FIGURE 1. Top, male pattern. Bottom, female pattern.

Telogen effluvium

Telogen effluvium or shedding is the most common type of hair loss. In this condition, hair follicles prematurely convert from the growth phase to the resting or shedding (telogen) phase.

Presentation. The primary sign reported by patients is an increase in the number of hairs they are shedding, seen on the shower drain, clothes, or pillow. Normally, people shed up to about 100 hairs on days they do not shampoo;

people with telogen effluvium usually lose 150 to 400 hairs per day. Some patients notice a decrease in hair volume only when hair density is reduced as much as 30% to 50%.²

Causes. Often, an event triggers the process 3 to 6 months before the shedding begins. Acute shedding was initially described after febrile diseases, childbirth, chronic systemic diseases, use of heparin, and emotional distress.³

Other factors identified as both acute and chronic causes of telogen effluvium include numerous drugs, endocrine disorders, severely restrictive diets, surgical procedures, and anesthesia.⁴⁻⁶

Recently, it was proposed that telogen effluvium can herald androgenetic alopecia in either sex.⁷

Diagnosis. The key is to find the trigger, with a careful clinical history. In addition, the clinician should evaluate thyroid function and exclude anemia. Hormonal screening can help detect perimenopausal changes and androgen excess.

The history and physical examination should exclude infectious diseases (eg, syphilis) and nutritional deficiencies (protein, vitamins, and minerals) that are often associated with shedding.

Treatment. To treat telogen effluvium, the cause or causes must be isolated and treated. Patients should always be reassured that their hair is being replaced, and that the chances of becoming bald are remote.

Androgenetic alopecia

Presentation. Androgenetic alopecia may affect genetically predisposed men and women at any time from puberty to senescence. Thinning of the hair usually begins between the ages of 12 and 40 years, and approximately half of the population expresses this trait to some degree before age 50.⁸

The initiating event may be a telogen shed, but the primary sign reported by the patient is thinning. The progressive thinning results from both a gradual miniaturization of the hair follicle and a shortened growth (anagen) phase.

The pattern of hair loss is quite variable. Common in both men and women is the M-pattern, characterized by frontal recession

**In shedding,
look for a
trigger that
occurred 3 – 6
months earlier**



with thinning or absent hair in the temples (FIGURE 1). Another pattern, more common in women, is decreased density of scalp hair in the central area, with retention of the frontal hairline (FIGURE 1).

Causes. Androgens such as dehydrotestosterone and dehydroepiandrosterone sulfate influence hair loss. Dehydrotestosterone, the most potent androgen, reduces the amount of scalp hair and increases the amount of body and genital hair.

Whether androgenetic alopecia is inherited is controversial; it is either polygenic or autosomal dominant with variable penetrance. Androgenetic alopecia affects equal numbers of men and women. One-third of people with a strong family history can expect to be affected, irrespective of sex.⁹

Diagnosis. The diagnosis is based on clinical presentation and family history. Hormonal evaluation is necessary if androgen excess is suspected by the presence of acne, hirsutism, and, in women, irregular menstrual periods.

Treatment. Dehydrotestosterone is one of the targets when treating androgenetic alopecia. Oral finasteride, a 5- α -reductase inhibitor, produces local reductions in this hormone in the scalp follicles. Studies with finasteride demonstrated good results in men, but no improvement in postmenopausal women with female androgenetic alopecia.^{10,11}

In women, topical minoxidil 2% or 5% is the first option. (It is also used in men.¹⁰) Women should take special care to avoid the face when applying minoxidil, because it can promote the growth of facial hair and worsen hirsutism.

Systemic treatments for female androgenetic alopecia, such as spironolactone and flutamide, are controversial but are indicated to block androgen uptake by the follicles.¹² For the same reason, birth control pills and hormone replacement therapy can be used as adjuvant treatment.

Alopecia areata

Presentation. Alopecia areata causes isolated or recurrent patchy hair loss (FIGURE 2), but multiple patches, complete scalp hair loss (alopecia totalis), and complete scalp and body hair loss (alopecia universalis) are other clinical presentations.

Alopecia areata

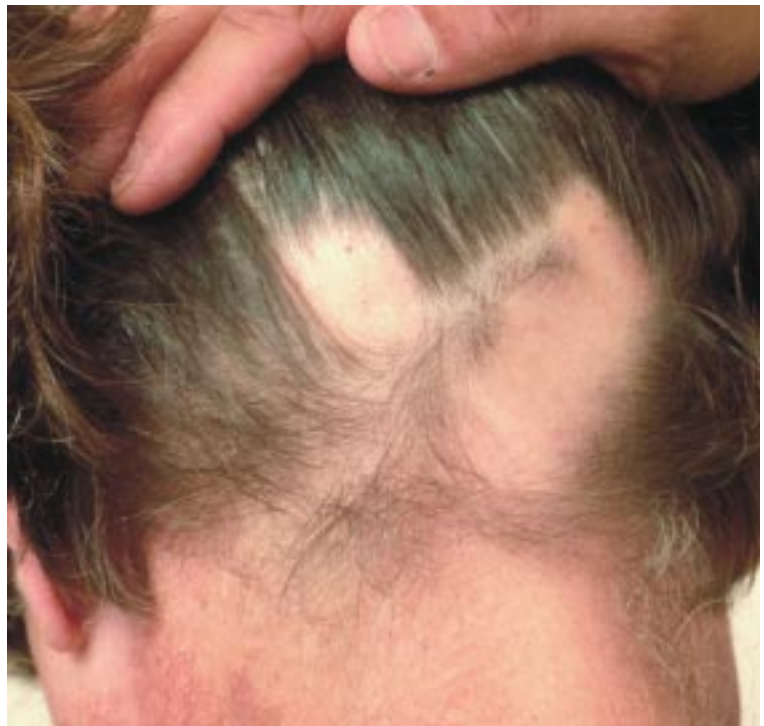

FIGURE 2

The prognosis is unpredictable. The first hair to regrow is thin and light in color (vellus hair); this hair is often replaced by thick white hair before the normal-colored hair (terminal hair) regrows.

Causes. In alopecia areata, a deep inflammatory process around the follicle accelerates the shedding phase.¹³ The affected hair sheds, and no replacement is seen while the inflammation is present.

The exact cause of alopecia areata has not been identified. However, growing evidence suggests that it is an autoimmune disease mediated by T lymphocytes. As an autoimmune disease, alopecia areata can be associated with other diseases of known or suspected autoimmune origin, such as thyroid disease, vitiligo, and atopy.¹⁴ Other autoimmune disorders such as lupus erythematosus, diabetes, and pernicious anemia are common in the family history.

Genetic factors have an important role in alopecia areata, and a family history is found in 10% to 42% of cases.¹⁵

Treatment is based on the extent of the disease and on the patient's age.

Minoxidil is the first option in women with androgenetic alopecia

Traction alopecia

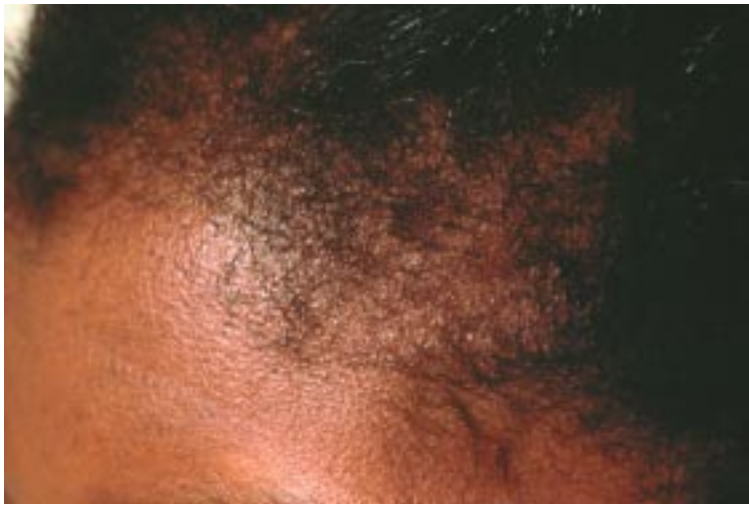

FIGURE 3

Intralesional corticosteroid injections are the first-line therapy for adults with scalp involvement of less than 50%.¹⁵ Reducing the inflammation is the main goal of corticosteroids.

Minoxidil is a biologic response-modifier that enhances hair growth, but it produces cosmetically acceptable results in fewer than half of patients with alopecia areata.¹⁶

Anthralin, a nonspecific immunomodulating agent commonly used in children, produces cosmetically acceptable regrowth in 20% to 25% of patients.¹⁷

Topical immunotherapy with contact sensitizers (dinitrochlorobenzene, squaric acid dibutyl ester, or diphenylcyclopropenone) is the most effective and accepted therapy for chronic severe alopecia areata. However, the rate of acceptable regrowth varies and depends on the extent of the alopecia and on which sensitizer is used.¹⁵ The exact mechanism of action of the topical sensitizers is unclear, but they direct T lymphocytes away from the perifollicular area, causing a mild skin irritation and allergic reaction.

Traction alopecia

Traction can physically damage the hair shaft and also alter the hair growth cycle. If traction is repetitive and chronic, cicatricial alopecia may result.

Presentation. Traction alopecia causes the hair to be sparse and break in the frontal area (FIGURE 3). This condition is quite common

in women with curly hair, especially African Americans.

Causes. Tight braids, ponytails, elastic hair bands, rollers, or other devices that place extreme and repetitive stress on the scalp hair are responsible for most cases.

Treatment of traction alopecia involves urging the patient to change her hairstyle and explaining that the hair loss may be permanent if the traction is not stopped.

Trichotillomania

Trichotillomania is the compulsive pulling out of one's own hair in a bizarre pattern.

Presentation. Trichotillomania clinically presents as areas of incomplete hair loss and short hair, most commonly on the scalp. Eyelashes, eyebrows, and other hairy areas can also be affected.

The condition is frequently seen in children, in whom pulling is often due to insecurity and is not a sign of psychiatric illness.¹⁸ In both younger and older women, the condition can be associated with depression or anxiety.¹⁹ Of note, it is unusual for the patient to admit or report his or her own history of hair pulling.

Causes. The cause may not be obvious; it can range from an underlying emotional problem to a definite mental disorder.

Treatment. Patients with trichotillomania require psychological evaluation and counseling. Psychopharmacologic medications such as fluoxetine are often necessary to control the compulsive hair-pulling.

■ CICATRICAL ALOPECIA

Cicatricial alopecia is irreversible hair loss associated with destruction of the stem cell reservoir located in the middle of the follicle.

Causes

Cicatricial alopecia is caused by a diverse group of cutaneous disorders with a variety of presentations. Common causes are fungal or bacterial folliculitis, discoid lupus erythematosus, and lichen planopilaris. Others include trauma, scarring bullous disorders (epidermolysis bullosa, bullous pemphigoid, porphyria cutanea), and neoplastic disease (skin tumors and cutaneous metastasis).

Traction alopecia is common in women with curly hair



Diagnosis

The evaluation of cicatricial alopecia of unknown origin starts with cultures for bacterial and fungal infection. The diagnosis is based on scalp biopsy; 4-mm punch biopsy is suggested.

Treatment

Even though the hair loss is irreversible, treatment is always recommended to prevent the process from spreading to unaffected areas. These patients should be referred to a dermatologist who has a special interest in hair loss.

HAIR SHAFT ABNORMALITIES

Presentation

Hair shaft abnormalities produce fragile and brittle hair. Patients may present with diffuse or patchy areas of short hair and a history of hair that will not grow beyond a certain length.

Causes


Repeated trauma to the hair shaft from trac-

tion, bleaching, perming, or blow-drying is most often the cause of the hair shaft abnormality in adults.

In addition, inherited disorders (genodermatoses) and external hair shaft damage can change the hair shaft structure.

A variety of hair shaft shapes may develop. The most common hair shaft abnormality is trichorrhexis nodosa, a nodal area where the hair splits into strands. Trichorrhexis nodosa is more commonly acquired as a result of external damage, but it may be associated with genetic and metabolic disorders that alter hair keratinization. Patients with these latter conditions should be referred to a dermatologist with a special interest in hair diseases.

Treatment

Treatment is based on removing the cause, if the problem is traumatically induced. Leave-on conditioners that coat the hair fibers may increase hair strength and prevent breakage. 

REFERENCES

1. Bergfeld WF, Elston DM. Scarring alopecia. In: Roenigk RK, Roenigk HH Jr, editors. *Dermatologic Surgery*. 2nd ed. New York: Marcel Dekker, Inc, 1996:647-663.
2. Reborna A. Telogen effluvium. *Dermatology* 1997; 195:209-212.
3. Kligman AM. Pathologic dynamics of human hair loss. I. Telogen effluvium. *Arch Dermatol* 1961; 83:175-198.
4. Pillans PI, Woods DJ. Drug induced alopecia. *Int J Dermatol* 1995; 34:149-158.
5. Headington JT. Telogen effluvium. *Arch Dermatol* 1993; 129:356-363.
6. Goette DU, Odum RB. Alopecia in crash dieters. *JAMA* 1976; 235:2622-2623.
7. Whiting DA. Chronic telogen effluvium. *Dermatol Clin* 1996; 14:723-731.
8. Price VH. Treatment of hair loss. *N Engl J Med* 1999; 341:964-973.
9. Kuster W, Happle R. The inheritance of common baldness: Two B or not Two B? *J Am Acad Dermatol* 1984; 5:921-926.
10. Whiting DA, Waldestreicher J, Sanches M, Kaufman KD. Measuring reversal of hair miniaturization in androgenetic alopecia by follicular counts in horizontal sections of serial scalp biopsies: results of finasteride 1 mg treatment of men and postmenopausal women. *J Invest Dermatol Symp Proc* 1999; 4:282-284.
11. Kaufman KD, Olsen EA, Whiting D, et al. Finasteride in the treatment of men with androgenetic alopecia. Finasteride Male Pattern Hair Loss Study Group. *J Am Acad Dermatol* 1998; 39:578-589.
12. Pakinson RW. Hair loss in women. *Postgrad Med* 1992; 91:417-431.
13. Shapiro J, Price VH. Hair regrowth: therapeutic agents. *Dermatol Clin* 1998; 16:341-356.
14. MacDonald N. Alopecia areata: identification and current approaches. *Dermatol Nurs* 1999; 11:356-359.
15. Madani S, Shapiro J. Alopecia areata update. *J Am Acad Dermatol* 2000; 42:549-565.
16. Price VH. Double-blind, placebo-controlled evaluation of topical minoxidil in extensive alopecia areata. *J Am Acad Dermatol* 1987; 16:730-736.
17. Fiedler VC, Alaiti S. Treatment of alopecia areata. *Dermatol Clin* 1996; 14:733-738.
18. Whiting DA. Traumatic alopecia. *Int J Dermatol* 1999; 38:34-44.
19. Muller SA. Trichotillomania: a histopathologic study in sixty-six patients. *J Am Acad Dermatol* 1990; 23:56-62.

ADDRESS: Wilma F. Bergfeld, MD, Department of Dermatology, A61, The Cleveland Clinic Foundation, 9500 Euclid Avenue, Cleveland, OH 44195; e-mail bergfew@ccf.org.

Visit our web site at <http://www.ccjm.org>

Contact us by e-mail at ccjm@ccf.org