

**PAUL SCHOENHAGEN, MD**

Section of Cardiovascular Imaging, Department of Radiology, and Department of Cardiovascular Medicine, The Cleveland Clinic

**STEVEN E. NISSEN, MD**

Medical Director, Cardiovascular Coordinating Center, Department of Cardiovascular Medicine, The Cleveland Clinic

**RICHARD D. WHITE, MD**

Head, Section of Cardiovascular Imaging, Department of Radiology, and Department of Cardiovascular Medicine, The Cleveland Clinic

**E. MURAT TUZCU, MD**

Director, Intravascular Laboratory, Department of Cardiovascular Medicine, The Cleveland Clinic

# Coronary imaging: Angiography shows the stenosis, but IVUS, CT, and MRI show the plaque

## ABSTRACT

Angiography is the standard clinical test for advanced coronary artery disease. Tomographic cardiovascular imaging tests, ie, intravascular ultrasonography (IVUS), computed tomography (CT), and magnetic resonance imaging (MRI), can be used to assess atherosclerotic plaques responsible for early, silent disease and may become important tools for early detection and prevention.

## KEY POINTS

Selective coronary angiography is the gold standard for detecting severely stenotic lesions of the coronary lumen but does not provide information about the disease process, which takes place in the vessel wall.

Tomographic coronary imaging tests allow early, direct assessment of atherosclerotic plaques.

IVUS is clinically well established but invasive.

Multislice CT and MRI have great potential for noninvasive imaging of atherosclerotic plaques.

For patients with coronary artery disease, we do not yet know how much value these new imaging tests will add to traditional risk factor assessment and angiography.

**N**EW TYPES OF imaging tests that use tomographic technology can reveal information about coronary artery disease that traditional angiography cannot.

*See related editorial, page 664*

Specifically, these tests—intravascular ultrasonography (IVUS), computed tomography (CT), and magnetic resonance imaging (MRI)—can show clinically significant, yet silent, changes in the vessel wall that precede the narrowing of the lumen that angiography can show.

How these new tests will be used in clinical practice is still being worked out; we believe they will have an important role as adjuncts to traditional risk factor assessment and angiography and will allow us to intervene early to prevent the complications of coronary artery disease. Already, these tests have advanced our understanding of how coronary artery disease develops and progresses.

Here we review the current research on the potential of tomographic imaging to evaluate coronary artery disease.

## STRENGTHS AND WEAKNESSES OF ANGIOGRAPHY

Selective coronary angiography, introduced by Dr. Mason Sones of The Cleveland Clinic Foundation in 1958, reliably identifies luminal dimension in the entire epicardial tree with high resolution. It therefore remains vital for detecting and treating severely stenotic coronary lesions, and it remains the basis for

catheter-based and surgical revascularization.

But angiography shows only the lumen, whereas coronary artery disease is a disease of the vessel wall. Typically, an angiographic study is considered positive only when stenosis is severe enough to limit flow.

We have learned that atherosclerotic plaque begins to accumulate in the arterial wall long before the lumen becomes narrowed. In fact, most acute coronary syndromes are triggered by sudden disruption of atherosclerotic plaques that caused neither significant stenosis nor angina pectoris before the event.

Because early but potentially dangerous lesions are often not associated with changes in lumen size, angiography alone does not tell the whole story.

#### ■ 'RUSTY PIPES': A FLAWED ANALOGY

The angiographic appearance of severe coronary lesions led to the analogy comparing coronary disease to rusty pipes. According to this traditional, simplistic model, plaque gradually accumulates inside the vessel until it eventually obstructs the lumen and causes acute coronary events.

But this model cannot explain several observations from pathological and clinical studies.<sup>1,2</sup>

#### **Atherosclerosis is common, but often does not cause stenosis**

Necropsy studies of patients who died of non-cardiac causes and IVUS examinations in heart transplant recipients have shown that atherosclerotic lesions begin to develop in childhood.

We performed IVUS in 262 heart transplant recipients weeks after they received their transplants; the donors were young, had no clinical evidence of coronary artery disease, and had died of trauma, typically motor vehicle accidents. The prevalence of coronary lesions (defined as intimal thickening > 0.5 mm by IVUS) varied from 17% in hearts from donors younger than 20 years to 85% in those 50 years and older.<sup>2,3</sup>

These findings indicate that clinical symptoms and traditional imaging techniques identify only the "tip of the atherosclerotic iceberg."

Clinical symptoms, stress testing, and angiography are not sensitive in detecting early, silent coronary artery disease because they become positive only when accumulation of atherosclerotic plaque leads to significant, flow-limiting stenosis of the vessel lumen. However, initial plaque development frequently does not lead to stenosis.<sup>4</sup>

#### **Mildly stenotic lesions cause most events**

"Silent" coronary artery disease, although nonobstructive, is still clinically significant. In fact, angiographic studies demonstrate that most acute coronary events start with rupture or superficial erosion of mildly stenotic lesions that had not caused ischemic symptoms before.<sup>5-7</sup> About two thirds of events arise from lesions that caused less than 50% stenosis before the event, another one sixth arise from lesions that previously caused 50% to 70% stenosis, and only about one sixth come from lesions that previously caused more than 70% stenosis.

Myocardial infarction or sudden cardiac death are the initial presentations of coronary artery disease in more than 50% of patients.

#### ■ THE NEW MODEL OF CORONARY DISEASE

##### **Early changes: Outward remodeling**

Histologic and IVUS studies of coronary lesions show that, early on, as plaque grows, the arterial wall expands outward. This outward remodeling (also called "positive" remodeling) maintains luminal size despite plaque accumulation.<sup>8,9</sup> These accumulating lesions, which cause minimal luminal obstruction, are often characterized as "minor luminal irregularities" by angiography.

IVUS has shown that relatively large plaques can accumulate without significant luminal stenosis. Many patients have more than one of these sites, which add up to a relatively large but asymptomatic disease burden.<sup>10</sup>

It was initially believed that outward arterial remodeling was a purely compensatory mechanism with the beneficial effect of maintaining blood flow, and that luminal stenosis and clinical disease ensued when the vessel could not expand further.<sup>8</sup>

**Most acute coronary events come from mildly stenotic lesions**



## FIGURE 1

**Not available for online publication.  
See print version of the  
*Cleveland Clinic Journal of Medicine***

However, several recent studies that examined the relation between arterial remodeling and clinical presentation have changed our understanding of early atherosclerotic changes in the vessel wall.<sup>11</sup> Surprisingly, these studies consistently found outward remodeling to be strongly associated with unstable coronary syndromes.<sup>12–16</sup>

We compared the remodeling response in 85 patients who presented with unstable angina or acute myocardial infarction and in 46 patients with stable clinical presentations. Outward remodeling was significantly more common in the unstable group and negative remodeling, the narrowing of the lumen, was significantly more common in the stable group (FIGURE 1).<sup>15</sup>

In a recent prospective study of mildly stenotic lesions, Yamagishi et al<sup>16</sup> found that plaques with positive remodeling at baseline more frequently led to acute coronary syndromes during follow-up.

Because of this association of outward remodeling with unstable clinical presentations, it has been suggested that the term “positive” remodeling be avoided.

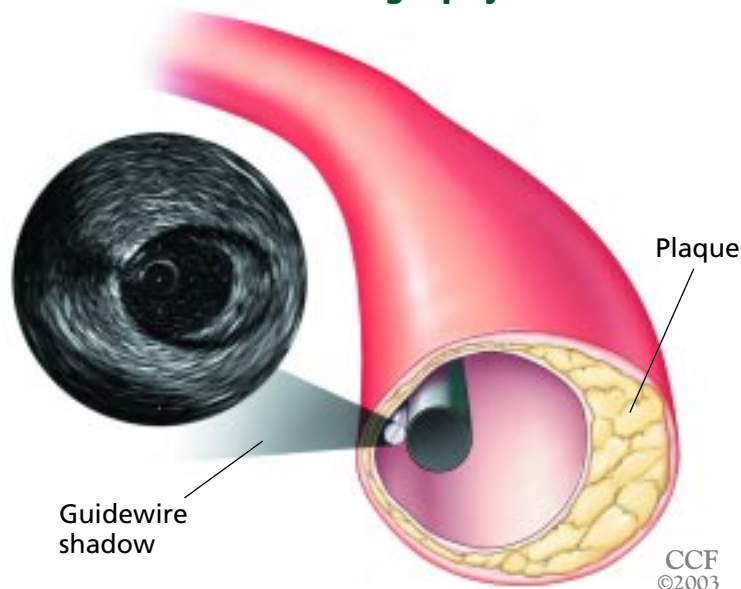
### **A link with inflammation**

A clue to the possible mechanism of the link between remodeling and unstable clinical presentation comes from histologic studies in which positive remodeling was associated with an inflammatory response at the lesion site.<sup>17,18</sup> Inflammation is a central process in the transition from stable to unstable atheroma and in plaque progression.<sup>19,20</sup>

### **A diffuse, systemic disease**

In summary, in the emerging model of coronary artery disease, atherosclerotic lesions develop initially without luminal stenosis.<sup>19</sup> Plaque rupture and subsequent fibrosis are likely frequent, asymptomatic events related to plaque progression.<sup>21,22</sup>

## Intravascular ultrasonography



**FIGURE 2.** Intravascular ultrasonography (IVUS), with its inside-out view of the coronary segment, provides complementary information that angiography cannot. The IVUS catheter is seen in the center, surrounded by the lumen and an eccentric atherosclerotic plaque.

## Calcifications in plaque may be good or bad

Supporting this concept of a systemic disease process is the recent finding that plaque disruption in patients presenting with unstable coronary syndromes is not a focal phenomenon at the “culprit” lesion, but is often found at additional distant sites.<sup>23,24</sup> Clinical acute coronary events, including unstable angina, myocardial infarction, and sudden cardiac death, are caused by plaque rupture or erosion with subsequent obstructing thrombosis and are focal manifestations of this systemic disease process.

After episodes of rupture the plaque may stabilize, eventually leading to inward remodeling (vessel shrinkage) of the coronary segment and fibrosis and calcification of the associated plaque.<sup>25,26</sup> These changes may lead to flow-limiting lesions that are clinically symptomatic but stable.

### ■ TOMOGRAPHIC IMAGING: POTENTIAL ROLE IN SCREENING

These findings suggest that, to prevent the complications of coronary artery disease such

as myocardial infarction and sudden coronary death, we probably need to diagnose and treat coronary artery disease many years before hemodynamically significant coronary stenoses develop. This is the rationale for screening for traditional risk factors such as hyperlipidemia, and there is consistent evidence that early treatment of these risk factors decreases future cardiovascular events.<sup>27,28</sup>

Tomographic imaging tests allow direct assessment of the morphology of the vessel wall and of atherosclerotic plaque.<sup>29,30</sup> The information these tests provide is complementary to the information provided by symptoms, stress testing, and angiography.

Could tomographic imaging play a role in detecting coronary disease early in patients with no symptoms or with only minimal symptoms? We summarize the current and emerging evidence below, but we must emphasize that the current data are not sufficient to recommend these diagnostic tests in routine clinical or general screening.

### Measuring coronary calcification with CT, IVUS, and angiography

Coronary calcification is a reliable sign of atherosclerotic plaque. The extent of coronary calcification can be estimated during angiography, but CT calcium scoring is more sensitive.<sup>31</sup>

Several studies showed that the CT calcium score, a measure of the overall amount of calcified plaque, correlates with, but greatly underestimates, the overall plaque burden. Nonetheless, higher scores seem to predict clinical events.<sup>32,33</sup>

However, coronary calcifications can have different significance.<sup>34,35</sup> In particular, the significance of small calcifications in lipid-rich plaques is unclear: they may be associated with instability, while calcification in more advanced lesions may be a stabilizing factor. It is therefore not completely clear if an increase in coronary calcifications over time is a sign of increased or decreased lesion stability.<sup>36,37</sup> In fact, serial IVUS studies indicate that disease stabilization is associated with increasing lesion calcification.<sup>38</sup>

Current guidelines recommend calcium screening only for selected patients with intermediate risk profiles and after consultation



with a physician familiar with the concepts of preventive cardiology.<sup>39</sup>

### IVUS can assess plaque volume, morphology

Like carotid ultrasonography, coronary IVUS can identify calcified and noncalcified plaque and can be used to assess plaque burden in coronary vessels (FIGURE 2).

A recent study<sup>38</sup> compared changes in plaque volume in a group of patients treated with a lipid-lowering medication and in a control group. The treatment group had a trend towards a smaller increase in plaque volume, but the difference was not significant. In addition, plaques in the treatment group increased in echogenicity over time, presumably reflecting morphologic changes associated with lipid depletion.

Similar, larger trials are under way. For example, the large prospective, randomized REVERSAL study<sup>40</sup> is comparing changes in plaque volume in patients undergoing high-dose lipid-lowering treatment and in a control group. Baseline IVUS studies have already been performed in 657 patients, and matched follow-up studies after 18 months of treatment are available for most of them.

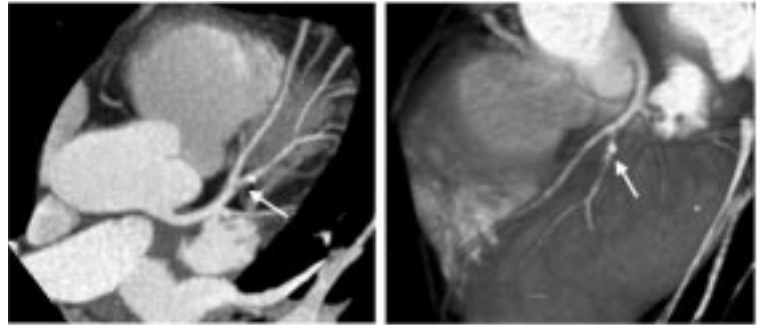
### MRI, CT are noninvasive

IVUS, with its view from inside the artery, has high resolution, but its invasiveness limits its use in preventive settings. Needed are noninvasive imaging tests.

CT scanners have improved to the point that they can now reveal coronary atherosclerotic plaque in clinical settings (FIGURE 3). Several studies reported that CT with intravenous contrast could identify calcified and noncalcified coronary lesions.<sup>41</sup> Schroeder et al<sup>42</sup> performed IVUS and multislice CT in 15 patients undergoing percutaneous interventions. Both tests could distinguish soft, intermediate, and hard (calcified) plaque.

Similar developments can be expected with MRI.<sup>43</sup> MRI has been used to characterize plaque in the carotid artery, and the

## Multislice CT of coronary lesions



**FIGURE 3.** Multiple areas of mild, hemodynamically insignificant stenosis of the left anterior descending coronary artery, consistent with early plaque formation. The arrows show a lesion in the large first diagonal branch with both noncalcified (“soft”) and calcified (white dot) components.

appearance of the plaque on MRI has been correlated with clinical presentation.<sup>44,45</sup> A recent study observed attenuated plaque progression in the aorta during lipid-lowering treatment.<sup>46</sup>

CT and MRI have great potential, as they are noninvasive and provide comprehensive information about stenotic and nonstenotic plaque and myocardial viability.<sup>47,48</sup> However, how much value they will add to traditional risk factor assessment and angiography has not been proven for patients with coronary artery disease.

### CONCLUSION

IVUS, CT, and MRI allow a comprehensive view of coronary anatomy and supplement the information provided by angiography. Direct assessment of the atherosclerotic plaque may in particular be important in detecting early coronary artery disease and stratifying risk in disease prevention.

While these tests are currently the focus of intense clinical research, their incremental value is not yet proven. Accordingly, their use requires a careful clinical assessment of potential risks and benefits in individual patients.

### REFERENCES

- Strong JP, Malcom GT, McMahan CA, et al. Prevalence and extent of atherosclerosis in adolescents and young adults: Implications for prevention from pathobiological determinants of atherosclerosis in youth study. *JAMA* 1999; 281:727-735.
- Tuzcu EM, Kapadia SR, Tutar E, et al. High prevalence of coronary atherosclerosis in asymptomatic teenagers and young adults: evidence from intravascular ultrasound. *Circulation* 2001; 103:2705-2710.
- Tuzcu EM, Hobbs RE, Rincon G, et al. Occult and frequent transmission of atherosclerotic coronary disease with cardiac transplanta-

- tion: insights from intravascular ultrasound. *Circulation* 1995; 91:1706–1713.
4. **Topol EJ, Nissen SE.** Our preoccupation with coronary luminology. The dissociation between clinical and angiographic findings in ischemic heart disease. *Circulation* 1995; 92:2333–2242.
  5. **Little WC, Constantinescu M, Applegate RJ, et al.** Can coronary angiography predict the site of a subsequent myocardial infarction in patients with mild-to-moderate coronary artery disease? *Circulation* 1988; 78:1157–1166.
  6. **Falk E, Shah PK, Fuster V.** Coronary plaque disruption. *Circulation* 1995; 92:657–671.
  7. **Burke AP, Farb A, Malcom GT, et al.** Coronary risk factors and plaque morphology in men with coronary disease who died suddenly. *N Engl J Med* 1997; 336:1276–1282.
  8. **Glagov S, Weisenberg E, Zarins C, et al.** Compensatory enlargement of human atherosclerotic coronary arteries. *N Engl J Med* 1987; 316:1371–1375.
  9. **Losordo DW, Rosenfield K, Kaufman J, et al.** Focal compensatory enlargement of human arteries in response to progressive atherosclerosis: in vivo documentation using intravascular ultrasound. *Circulation* 1994; 89:2570–2577.
  10. **Mintz GS, Painter JA, Pichard AD, et al.** Atherosclerosis in angiographically “normal” coronary artery reference segments: an intravascular ultrasound study with clinical correlations. *J Am Coll Cardiol* 1995; 25:1479–1485.
  11. **Schoenhagen P, Ziada KM, Vince DG, Nissen SE, Tuzcu EM.** Arterial remodeling and coronary artery disease. The concept of “dilated” versus “obstructive” coronary atherosclerosis. *J Am Coll Cardiol* 2001; 38:297–306.
  12. **Smits PC, Pasterkamp G, de Jaegere PP, de Feyter PJ, Borst C.** Angioscopic complex lesions are predominantly compensatory enlarged: an angioscopy and intracoronary ultrasound study. *Cardiovasc Res* 1999; 41:458–464.
  13. **Pasterkamp G, Schoneveld AH, van der Wal AC, et al.** Relation of arterial geometry to luminal narrowing and histologic markers for plaque vulnerability: the remodeling paradox. *J Am Coll Cardiol* 1998; 32:655–662.
  14. **Nakamura M, Nishikawa H, Mukai S, et al.** Impact of coronary artery remodeling on clinical presentation of coronary artery disease: an intravascular ultrasound study. *J Am Coll Cardiol* 2001; 37:63–69.
  15. **Schoenhagen P, Ziada K, Kapadia SR, et al.** Extent and direction of arterial remodeling in stable versus unstable coronary syndromes: an intravascular ultrasound study. *Circulation* 2000; 101:598–603.
  16. **Yamagishi M, Terashima M, Awano K, et al.** Morphology of vulnerable coronary plaque: insights from follow-up of patients examined by intravascular ultrasound before an acute coronary syndrome. *J Am Coll Cardiol* 2000; 35:106–111.
  17. **Burke AP, Kolodgie FD, Farb A, et al.** Morphological predictors of arterial remodeling in coronary atherosclerosis. *Circulation* 2002; 105:297–303.
  18. **Varnava AM, Mills PG, Davies MJ.** Relationship between coronary artery remodeling and plaque vulnerability. *Circulation* 2002; 105:939–943.
  19. **Ross R.** The pathogenesis of atherosclerosis: a perspective for the 1990s. *Nature* 1993; 362:801–809.
  20. **Libby P.** Current concepts of the pathogenesis of the acute coronary syndromes. *Circulation* 2001; 104:365–372.
  21. **Gutstein DE, Fuster V.** Pathophysiology and clinical significance of atherosclerotic plaque rupture. *Cardiovasc Res* 1999; 41:323–333.
  22. **Burke AP, Kolodgie FD, Farb A, et al.** Healed plaque ruptures and sudden coronary death: evidence that subclinical rupture has a role in plaque progression. *Circulation* 2001; 103:934–940.
  23. **Goldstein JA, Demetriou D, Grines CL, et al.** Multiple complex coronary plaques in patients with acute myocardial infarction. *N Engl J Med* 2000; 343:915–922.
  24. **Rioufol G, Finet G, Ginon I, et al.** Multiple atherosclerotic plaque rupture in acute coronary syndrome. A three-vessel intravascular ultrasound study. *Circulation* 2002; 106:804–808.
  25. **Pasterkamp G, Wensing PJ, Post MJ, et al.** Paradoxical arterial wall shrinkage may contribute to luminal narrowing of human atherosclerotic femoral arteries. *Circulation* 1995; 91:1444–1449.
  26. **Mintz GS, Kent KM, Pichard AD, et al.** Contribution of inadequate arterial remodeling to the development of focal coronary artery stenoses: an intravascular ultrasound study. *Circulation* 1997; 95:1791–1798.
  27. **Grundey SM, Pasternak R, Greenland P, Smith S Jr, Fuster V.** AHA/ACC scientific statement: Assessment of cardiovascular risk by use of multiple-risk-factor assessment equations: a statement for healthcare professionals from the American Heart Association and the American College of Cardiology. *J Am Coll Cardiol* 1999; 34:1348–1359.
  28. Executive summary of the third report of the National Cholesterol Education Program (NCEP) expert panel on detection, evaluation, and treatment of high blood cholesterol in adults (Adult Treatment Panel III). *JAMA* 2001; 285:2486–2497.
  29. **Nissen SE, Yock P.** Intravascular ultrasound: novel pathophysiological insights and current clinical applications. *Circulation* 2001; 103:604–616.
  30. **Mintz GS, Nissen SE, Anderson WD, et al.** American College of Cardiology clinical expert consensus document on standards for acquisition, measurement and reporting of intravascular ultrasound studies (IVUS). *J Am Coll Cardiol* 2001; 37:1478–1492.
  31. **Halliburton SS, Stillman AE, White RD.** Noninvasive quantification of coronary artery calcification: a potential tool for the assessment of coronary artery disease in patients with chronic renal failure. *Cleve Clin J Med* 2002; 69(suppl 3):S6–S11.
  32. **Rumberger JA, Simons DB, Fitzpatrick LA, Sheedy PF, Schwartz RS.** Coronary artery calcium area by electron-beam computed tomography and coronary atherosclerotic plaque area. *Circulation* 1995; 92:2157–2162.
  33. **Secci A, Wong N, Tang W, Wang S, Doherty T, Detrano R.** Electron beam computed tomographic coronary calcium as a predictor of coronary events. *Circulation* 1997; 96:1122–1129.
  34. **Schmermund A, Erbel R.** Unstable coronary plaque and its relation to coronary calcium. *Circulation* 2001; 104:1682–1687.
  35. **Schoenhagen P, Tuzcu EM.** Coronary artery calcification and end-stage renal disease. Vascular biology and clinical implications. *Cleve Clin J Med* 2002; 69(suppl 3):S12–S20.
  36. **Callister TQ, Raggi P, Cooil B, Lippolis NJ, Russo DJ.** Effect of HMG-CoA reductase inhibitors on coronary artery disease by electron-beam computed tomography. *N Engl J Med* 1998; 339:1972–1978.
  37. **Achenbach S, Ropers D, Pohle K, et al.** Influence of lipid-lowering therapy on the progression of coronary artery calcification. *Circulation* 2002; 106:1077–1082.
  38. **Schartl M, Bocksch W, Koschyk DH, et al.** Use of intravascular ultrasound to compare effects of different strategies of lipid-lowering therapy on plaque volume and composition in patients with coronary artery disease. *Circulation* 2001; 104:387–392.
  39. **O’Rourke RA, Brundage BH, Froelicher VF, et al.** American College of Cardiology/American Heart Association expert consensus document on electron-beam computed tomography for the diagnosis and prognosis of coronary artery disease. *Circulation* 2000; 102:126–140.
  40. **Nissen SE.** Rationale for a postintervention continuum of care: insights from intravascular ultrasound. *Am J Cardiol* 2000; 86:12H–17H.
  41. **Schroeder S, Kopp AF, Baumbach A, et al.** Noninvasive characterization of coronary lesion morphology by multi-slice computed tomography: a promising new technology for risk stratification of patients with coronary artery disease. *Heart* 2001; 85:576–577.
  42. **Schroeder S, Kopp AF, Baumbach A, et al.** Noninvasive detection and evaluation of atherosclerotic coronary plaques with multislice computed tomography. *J Am Coll Cardiol* 2001; 37:1430–1435.
  43. **Fayad ZA, Fuster V.** Clinical imaging of the high-risk or vulnerable atherosclerotic plaque. *Circ Res* 2001; 89:305–316.
  44. **Yuan C, Mitsumori LM, Ferguson MS, et al.** In vivo accuracy of multi-spectral magnetic resonance imaging for identifying lipid-rich necrotic cores and intraplaque hemorrhage in advanced human carotid plaques. *Circulation* 2001; 104:2051–2056.



45. Cai JM, Hatsukami TS, Ferguson MS, Small R, Polissar NL, Yuan C. Classification of human carotid atherosclerotic lesions with in vivo multicontrast magnetic resonance imaging. *Circulation* 2002; 106:1368-1373.
46. Corti R, Fayad ZA, Fuster V, et al. Effects of lipid-lowering by simvastatin on human atherosclerotic lesions. A longitudinal study by high-resolution, noninvasive magnetic resonance imaging. *Circulation* 2001; 104:249-252.
47. Achenbach S, Giesler T, Ropers D, et al. Detection of coronary artery stenoses by contrast-enhanced, retrospectively electrocardiographically-gated, multislice spiral computed tomography. *Circulation* 2001; 103:2535-2538.
48. Kim WY, Danias PG, Stuber M, et al. Coronary magnetic resonance angiography for the detection of coronary stenoses. *N Engl J Med* 2001; 345:1863-1869.

ADDRESS: E. Murat Tuzcu, MD, Department of Cardiovascular Medicine, F25, The Cleveland Clinic Foundation, 9500 Euclid Avenue, Cleveland, OH 44195; e-mail tuzcue@ccf.org.

# INTERNAL MEDICINE BOARD REVIEW

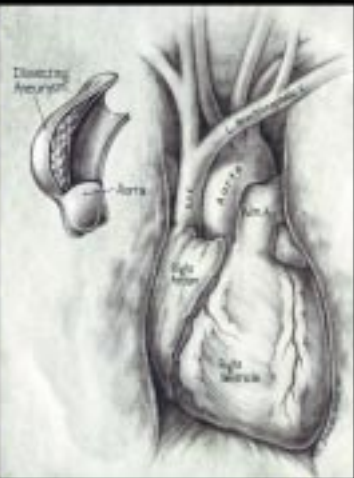


Clinical vignettes and questions on the differential diagnosis and treatment of medical conditions likely to be encountered on the Qualifying Examination in Medicine — as well as in practice.


Take the challenge.

## IN THIS ISSUE PAGE 729

THE CLEVELAND  
CLINIC  
FOUNDATION  
DEPARTMENT of  
CARDIOVASCULAR  
MEDICINE  
PRESENTS



## An Intensive Review of CARDIOLOGY



4th ANNUAL  
COMPREHENSIVE  
5½-DAY SYMPOSIUM  
...  
SEPTEMBER 21 - 26,  
2003  
INTERCONTINENTAL  
HOTEL  
AND CONFERENCE  
CENTER  
CLEVELAND, OH

Co-Directors: Eric Topol, MD, Brian Griffin, MD,  
and Curtis Rimmerman, MD

For more information, please contact the  
Cleveland Clinic Center for Continuing  
Education at  
**1-800-762-8173 or 216-444-5696**  
or visit our website:  
**www.clevelandclinicmeded.com**