

**JAMES S. WU, MD**Department of Colorectal Surgery,
Cleveland Clinic Beachwood Family
Health Center**MARK E. BAKER, MD**Department of Radiology,
The Cleveland Clinic Foundation

Recognizing and managing acute diverticulitis for the internist

ABSTRACT

Colonic diverticulitis can present as mild abdominal discomfort or as life-threatening septic shock and can also mimic many inflammatory conditions. Most patients with acute diverticulitis can be managed with antibiotics and supportive care. Surgery is reserved for those with repeat attacks, disease unresponsive to medical therapy, certain complications, and the possibility of colon cancer that cannot otherwise be excluded.

KEY POINTS

Diverticulitis occurs most commonly in the sigmoid colon with pain in the left lower quadrant or suprapubic area. Diverticulitis in uncommon locations may present atypically.

Patients who are stable can be managed as outpatients. Patients who are immunocompromised, elderly, or have severe findings should be observed in the hospital.

After the patient is stable, computed tomography with contrast is used for diagnostic evaluation, to search for fluid collections, and to guide treatment.

After an initial attack of diverticulitis has resolved, a full colonic evaluation should be performed to search for cancer.

ACU TE DIVERTICULITIS can present in a number of ways and is often confused with colonic spasm or irritable bowel syndrome. Missing the diagnosis, however, can result in serious consequences.

Once acute diverticulitis is diagnosed, its management often requires collaboration between an internist, a gastroenterologist, an infectious disease specialist, a surgeon, and a radiologist.

MUCOSAL HERNIATIONS SET THE STAGE

Diverticulitis begins with diverticulosis: the presence of diverticula, ie, herniations in the colon wall, first described in detail by Cruveilhier in 1849.¹

The colon wall has several layers: the mucosa, the submucosa, and two layers of smooth muscle (one circular and one longitudinal). Arteries (the vasa recta) from the mesentery encircle the bowel and penetrate the muscularis between the teniae coli to supply the inner mucosa. Diverticula are mucosal herniations that protrude through these openings (FIGURE 1).^{2,3} These herniations are thought to be caused by low dietary fiber, which may slow transit time through the colon and increase segmental pressure.⁴

Diverticulosis and diverticulitis may arise anywhere in the large intestine from the cecum to the end of the sigmoid colon but usually not in the rectum, which has no teniae. In Western society, diverticula most often occur in the sigmoid colon, where the greatest intraluminal pressure is generated. However, Asian-Americans have a higher incidence of right-sided diverticulitis and a lower incidence of left-sided diverticulitis than expected.⁵



Diverticulosis typically starts after age 40. The prevalence increases with advancing age, from about 5% in the fifth decade to about 50% in the ninth decade.⁶ Men and women are equally affected.

■ NEXT, PERFORATION AND INFLAMMATION

From 10% to 25% of patients with diverticulosis eventually develop inflammation in the diverticula, ie, diverticulitis.⁷⁻⁹

Diverticular perforation may be the initiating event in diverticulitis.¹⁰ When the thin colonic mucosa of a diverticulum ruptures outside the colon wall, bacteria-laden feces spill from the lumen of the colon into the normally sterile environment outside of the bowel and cause inflammation.

Inflammation may be intraperitoneal, retroperitoneal, or intramesenteric, depending on the location of the perforation. The transverse colon and sigmoid colon are intraperitoneal. The anterior walls of the right and left colon are also intraperitoneal, but their posterior walls are retroperitoneal.

Inflammation may be contained

The contamination that results from perforation may be contained or uncontained, depending on the colonic defect size and on whether neighboring structures “wall off” the infection. Uncomplicated diverticular perforation results in localized inflammation only.

Structures that can contain infection within the peritoneal cavity include the omentum, intestine, stomach, bladder, uterus, ovaries, fallopian tubes, hepatobiliary structures, and abdominal wall. Retroperitoneal structures that may abut and contain an area of diverticular inflammation include the ileopsoas muscle, the kidneys, the ureters, and major blood vessels such as the aorta and the vena cava.

Complications are many

Potential complications of diverticulitis are numerous. Inflammation may directly obstruct the affected intestine or may secondarily compress and obstruct neighboring tubular organs, such as a ureter. Abscesses most often occur locally in the region of the diseased intestine. A fistula may form between the colon and the

Colonic diverticulosis

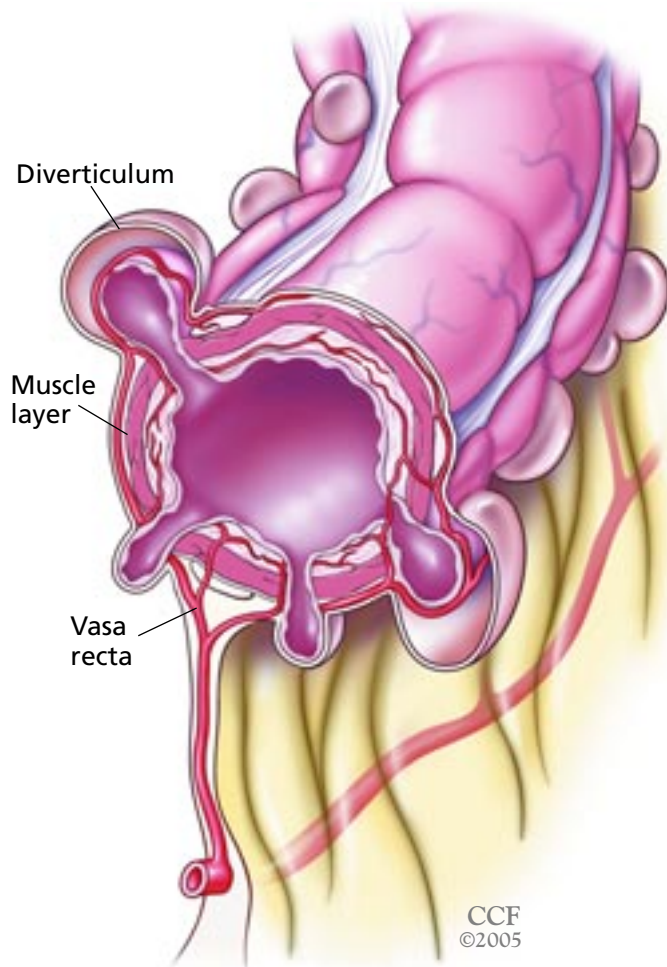


FIGURE 1. Colonic diverticulosis. Diverticula are mucosal herniations that occur at natural openings in the muscularis propria, where nutrient vessels (vasa recta) penetrate from the outside of the bowel to perfuse the mucosa.

skin, bladder, biliary tree, or vagina (after hysterectomy). Erosion of a diverticular mass (known as a phlegmon) into a vascular structure can cause hemorrhage.

Uncontained spillage of feces into the peritoneal cavity is a catastrophic event and may result in septic shock and death if emergency surgery is not performed.

■ DIVERTICULITIS CAN MIMIC OTHER INFLAMMATORY CONDITIONS

Since the colon can reach any part of the abdominal cavity and much of the retroperitoneum, diverticulitis may be confused with

TABLE 1

Differential diagnosis of diverticulitis

Appendicitis
Bowel obstruction
Colon cancer
Colon spasm
Gynecologic disease
Inflammatory bowel disease
Irritable bowel syndrome
Ischemic colitis
Small intestinal disease
Urologic disease

almost any inflammatory condition that occurs within or behind the peritoneal cavity (TABLE 1).

In addition, noninflammatory conditions—especially colonic spasm—can be mistaken for diverticulitis. Morson¹¹ showed that one third of resected specimens from patients with the presumed diagnosis of diverticulitis showed no pathologic evidence of inflammation. In some specimens, muscle thickening had occurred alone, without diverticula.

INITIAL EVALUATION

The initial evaluation of patients with possible diverticulitis should include a complete history, physical examination, measurement of vital signs, and laboratory tests, including a complete blood cell count, an electrolyte analysis, a urinalysis, and, if indicated, plain abdominal radiography.

Symptoms vary

Presenting symptoms can range from mild abdominal discomfort to those of life-threatening sepsis.

The first symptom usually is pain at the site of the perforation. When the sigmoid colon, the most common site, is involved, pain is typically in the left lower quadrant or suprapubic area.

The location of pain, however, may vary. If the sigmoid colon is redundant and crosses the midline, the pain may be on the right side, mimicking appendicitis. If the perforation is

on the posterior wall of the right or left colon, the pain is in the back or flank and may be confused with renal colic.

In addition to the constant pain caused by inflammation due to fecal spillage, there is also intermittent and wavelike pain caused by spasm of the involved colonic segment. Other gastrointestinal symptoms may include nausea, anorexia, and diarrhea.

Other symptoms may arise if the inflamed colon irritates a neighboring structure. For example, if the perforated colon rests on the bladder, the patient may experience urinary frequency or dysuria.

Patients may feel weak and light-headed from dehydration from low oral intake, and feverish from bacterial seeding of the bloodstream.

Physical findings

Physical findings also depend on the location and severity of the inflammation. Vital signs may be normal in a mild attack. At the other extreme, severe contamination causes fever and signs of hemodynamic compromise, including tachycardia and hypotension.

Typically, the region of the inflamed colon is initially tender. An inflammatory mass or phlegmon may be felt. Tenderness tends to be focal if the process is contained and contamination is minimal, and generalized if inflammation extends to a large area. Pain may be elicited by moving the inflamed area, either by gentle palpation or by provocative testing (eg, having the patient move the psoas muscle by walking or raising a leg).

When localized pain is present over a segment of spasmodic colon, it is helpful to ask the patient to point to the pain, although this is not specific. Palpation may also elicit pain over the same site, akin to the Murphy sign for acute cholecystitis elicited during ultrasonography.

In elderly or immunosuppressed patients, the signs and symptoms may be masked or diminished.^{12,13} For this reason, these patients should be hospitalized and closely observed.

Diagnostic tests

Tests should be ordered according to the severity of the clinical presentation.

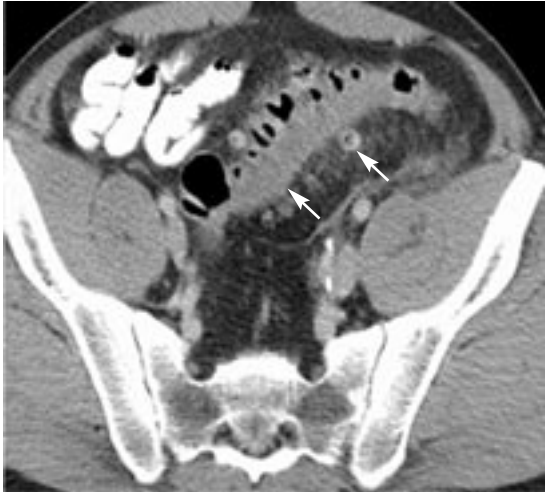The white blood cell count is typically

A normal WBC count does not exclude diverticulitis



Acute diverticulitis: What can computed tomography show?

Wall thickening, diverticula



Abscess

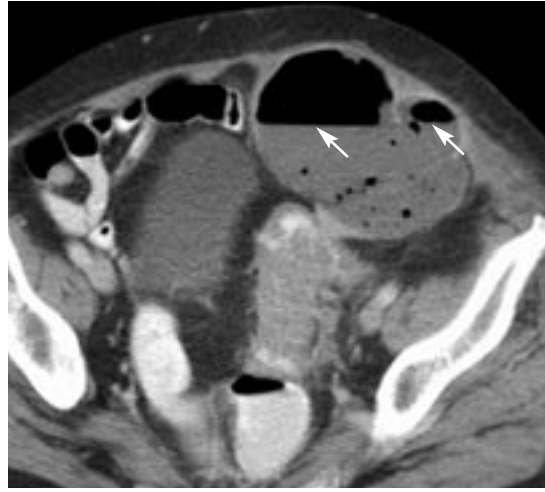


FIGURE 2

elevated in acute diverticulitis, but a normal value does not exclude it.

Plain abdominal radiography is often ordered in patients with acute abdominal pain. Findings, however, are often nonspecific—eg, small intestinal air-fluid levels consistent with ileus, or rarely, a pneumoperitoneum—and rarely point to a diagnosis. Uncommonly, in a patient with acute left-sided diverticulitis, one can see a mass effect with displacement of the intestine away from the inflamed colon in the left lower quadrant.

Water-soluble contrast enemas are almost never ordered for patients with suspected acute left-sided diverticulitis. The only exception is for small bowel obstruction in a patient who has never undergone abdominal surgery: in such a case, one must evaluate whether colonic obstruction is the cause of the small bowel obstruction, and a water-soluble contrast enema can safely be used.¹⁴

Potential findings include diverticula, colonic spasm, thickening of folds, asymmetric tethering of the colon wall, intramural sinus tracts, mass effect, and contrast extravasation (contained or free). Although nonspecific, such findings can be diagnostic in the proper clinical situation.

Ultrasonography is rarely used in the United States to evaluate patients with suspected acute diverticulitis, as the test is highly operator-dependent and is used only in spe-

cialized centers. It is often inaccurate if performed after regular working hours, when less-senior and less-experienced operators are on duty.

However, ultrasonography can detect signs consistent with diverticulitis, including thickening of the bowel wall and abscesses. In two early series (1978 and 1989),^{15,16} the sensitivity of ultrasonography in detecting acute colonic diverticulitis was 85% and 98%, the specificity was 80% and 97%, and the accuracy of detecting an abscess was 90% and 97%. A 1992 series showed 98% sensitivity and specificity, but the study population was highly preselected.¹⁷

Ultrasonography is particularly useful for women who may have a gynecologic condition or who must avoid radiation exposure. Ultrasonography may return a diagnosis of acute left-sided diverticulitis in a woman with pelvic pain in whom the physician suspects pelvic inflammatory disease. If the pelvic sonogram is normal, an astute and experienced sonographer can evaluate the left-sided colon for wall thickening, intramural gas, and adjacent abscess formation.

Using the transducer to elicit pain at the site of wall thickening provides useful diagnostic information, as does palpation in a contrast enema (analogous to eliciting Murphy sign in a patient with suspected acute cholecystitis, as noted above).

The accuracy of ultrasonography to detect diverticulitis is highly operator-dependent

Computed tomography (CT) with oral, rectal, and intravenous contrast has become one of the most useful tests for determining the cause of abdominal pain, including acute diverticulitis and some of its complications (FIGURE 2).

However, no data support the *routine* use of CT in every patient suspected of having acute left-sided diverticulitis.^{18,19} We believe it is used too often in patients with a classic presentation (fever, leukocytosis, change in bowel habits, and left lower quadrant pain). These patients have a high pretest probability of disease and do not need CT.

Rather, CT should be reserved for patients with a confusing clinical presentation or who have a classic presentation accompanied by a palpable left lower quadrant mass (which might be a drainable abscess that is important to detect). It is also useful in evaluating patients whose condition is not responding to standard therapy for acute diverticulitis, and in patients with acute abdominal pain without localizing signs, especially when peritonitis is present.

CT can also be used to guide therapeutic procedures, such as drainage of a percutaneous abscess.

CT findings in acute diverticulitis, first described in 1984 by Hulnick et al,²⁰ include diverticula (not necessary for the diagnosis), soft tissue infiltration of the pericolic fat, colon wall thickening, and pericolic abscesses. Complications of diverticulitis, such as a colovesical fistula, can occasionally be seen on CT as well.

Carcinoma of the colon with perforation, the most important possibility in the differential diagnosis, generally produces a larger, more asymmetrically or eccentrically placed mass than does acute diverticulitis. It also is accompanied by more pericolic and regional lymphadenopathy.

Acute diverticulitis often has an atypical appearance on CT in immunocompromised patients, such as those with diabetes or chronic renal failure or those taking immunosuppressive agents, because their immune systems do not mount an acute inflammatory response. These patients often present with either intraperitoneal or extraperitoneal gas without fluid or abscess formation.

A complete intraluminal examination of the colon, either by colonoscopy or by the combination of flexible sigmoidoscopy and contrast enema, should be performed to exclude colon cancer in all patients diagnosed with acute, left-sided diverticulitis after pain has resolved and they are well enough.

■ MANAGEMENT BASED ON SEVERITY

How diverticulitis is treated depends on its severity.²¹ Management often requires collaboration between an internist, a gastroenterologist, an infectious disease specialist, a surgeon, and a radiologist.

Early classification systems were based on findings at laparotomy and were intended to provide surgeons with guidelines during an operation.^{22,23} For example, Hughes et al²² in 1963 divided diverticulitis into four classes:

- Local peritonitis
- Local paracolic or pelvic abscess
- General peritonitis due to ruptured paracolic or pelvic abscess
- General peritonitis due to free perforation of the colon.

A CT-based staging system proposed by Neff et al^{24,25} is based on the same principles and helps in making management decisions (TABLE 2).

Detry et al²⁶ found that if there is no peritonitis, the prognosis mainly depends on whether an abscess is present: patients with a pericolic abscess had high recurrence rates.

Hospital or outpatient care?

If symptoms and findings are minor, outpatient treatment may suffice, with a liquid diet or low-residue diet and an oral antibiotic effective against colonic flora (including *Bacteroides fragilis* and *Escherichia coli*). The best antibiotic regimen depends on the organisms present and their sensitivity to available medications, the preferred route of administration, the dosing frequency, side effects, and cost.²⁷⁻²⁹

Patients who cannot tolerate oral intake should be admitted to the hospital and undergo intravenous fluid resuscitation, bowel decompression by nasogastric tube, and intravenous antibiotic treatment.

We feel CT is used too often in classic presentations of diverticulitis

**TABLE 2****Computed tomographic staging of colonic diverticulitis**

STAGE	CT SIGNS	TREATMENT
0	Diverticula Pericolonic infiltration Thickening of colonic wall (pericolonic phlegmon)	Conservative
1	Pericolonic abscess (up to 3 cm, limited to mesenterium)	Conservative
2	Pelvic abscess (perforation of the mesentery)	Percutaneous drainage, one-stage sigmoid resection
3	Extrapelvic abscess	Surgery Eventual percutaneous drainage with surgery followed electively
4	Large diverticular penetration with spread of fecal material into the abdominal cavity	Urgent surgery

BASED ON NEFF CC, VANSONNENBERG E. CT OF DIVERTICULITIS. DIAGNOSIS AND TREATMENT. *RADIOL CLIN NORTH AM* 1989; 27:743-752;
TABLE FROM DORINGER E. COMPUTERIZED TOMOGRAPHY OF COLONIC DIVERTICULITIS. *CRIT REV DIAGN IMAGING* 1992; 33:421-435.

Pain medications controversial

Whether to give pain medication to patients with acute abdominal complaints is controversial. Pain medications may mask the pain of intra-abdominal inflammation. On the other hand, it is not necessary to withhold pain medication from a stable patient in whom no intervention is contemplated.

Is surgery needed?

Medical treatment of acute uncomplicated diverticulitis will resolve the patient's symptoms in most cases. Most patients improve with supportive treatment, and it is reasonable to continue with this approach as long as there is no worsening of findings on serial examinations.

Emergency surgery may be needed to stop further fecal spillage if the patient has a perforated hollow viscus, indicated by pneumoperitoneum. Another indication for emergency surgery is if signs of sepsis continue despite treatment with antibiotics, fluids, and drainage.

Elective surgery. Most patients have limited disease that resolves without surgery and do not need elective "prophylactic" sigmoid resection.³⁰ Among the reasons for considering elective resection, however, are (TABLE 3):

- After repeated attacks of diverticulitis,

especially if severe enough to require hospitalization

- If concomitant carcinoma cannot be excluded
- In patients with chronic complications, such as a fistula or an obstruction.³¹
The goals of surgery, in order of importance, are to:
 - Eliminate contamination
 - Remove the diseased segment of intestine
 - Restore bowel continuity.

Surgery for first attack in young patients?

Some authors advocate surgical resection after a first attack of diverticulitis in young patients because of a perceived increased risk for disease recurrence and subsequent emergency surgery.^{32,33} However, others argue that routine surgery is unwarranted in young patients after a single attack of diverticulitis that resolves with antibiotics.^{34,35} No clear consensus exists on this subject.

Single-stage or multi-stage surgery

Diverticulitis may be treated with single-stage or multi-stage procedures. Ideally, resection and anastomosis are done in a single procedure when conditions are optimal, ie, in an elective surgery after the patient has com-

Most patients with acute diverticulitis recover with medical treatment

TABLE 3

Indications for surgery for diverticulitis

One attack of complicated diverticulitis
 Lack of improvement with medical therapy
 Recurrent attacks of diverticulitis (two or more requiring hospitalization)
 Inability to exclude carcinoma
 Fistula formation
 Generalized peritonitis
 Abscess
 High-grade bowel obstruction

pletely recovered from acute illness, after the bowel has been prepared, and when no undrained purulence is present.

In selected cases, resection and immediate anastomosis in an obstructed unprepared colon can be done after intraoperative colonic irrigation.^{36,37} However for cases in which anastomosis is not safe (eg, if there is septic shock or gross fecal contamination), fecal diversion can be done with or without resection.

In emergency situations, several options exist, including resection with colostomy and rectal pouch; resection, primary anastomosis, and proximal diversion; and drainage and proximal diversion. Each of these operations requires additional surgery to restore bowel continuity.

It is best to allow the patient to recover from an initial attack of acute diverticulitis and then plan an elective one-stage resection. Many patients who are given a “temporary” ostomy for acute diverticulitis never have it closed, either because they are medically unfit or because they decline further surgery.

Abscess drainage

Whether an abscess can be drained depends on its size and location. Diverticular abscesses smaller than 3 cm in diameter cannot be successfully drained with a catheter, because the pigtail catheter diameter is 3 cm. In addition, some authors believe that abscesses smaller than 5 cm should not be drained because they often resolve with antibiotic therapy.^{38–40}

We recommend trying to drain abscesses larger than 3 cm if the location is accessible. Early CT-guided needle drainage of abscesses may allow patients to avoid emergency surgery and to have elective single-stage surgical resection.⁴¹

Occasionally, the bony pelvis, urinary bladder, uterus, and surrounding bowel prevent catheter placement. A trans-sciatic approach⁴² is safe and effective in trained hands.

Treatment with intravenous antibiotics is essential if a catheter is placed.

The catheter must not be removed if a communication to the colon exists. To detect this, once catheter output has stopped, the catheter should be injected with iodinated contrast media under fluoroscopic observation. ■

REFERENCES


1. **Cruveilhier LJ.** *Traité d'anatomie pathologique générale.* Vol 1. Paris: J.B. Ballière; 1849–1864:593. Cited by Ellis H. Historical aspects of diverticula of the colon. *Perspect Colon Rectal Surg* 1991; 4:161–177.
2. **Drummond H.** Sacculi of the large intestine with special reference to their relations to the blood vessels of the bowel wall. *Br J Surg* 1916; 4:407–413.
3. **Slack WW.** The anatomy, pathology, and some clinical features of diverticulitis of the colon. *Br J Surg* 1962; 50:185–190.
4. **Painter NS, Burkitt DP.** Diverticular disease of the colon, a 20th century problem. *Clin Gastroenterol* 1975; 4:3–21.
5. **Lo CY, Chu KW.** Acute diverticulitis of the right colon. *Am J Surg* 1996; 171:244–246.
6. **Parks TG.** Natural history of diverticular disease of the colon. *Clin Gastroenterol* 1975; 4:53–69.
7. **Morson BC.** Pathology of diverticular disease of the colon. *Clin Gastroenterol* 1975; 4:37–52.
8. **Almy TP, Howell DA.** Medical progress. Diverticular disease of the colon. *N Engl J Med* 1980; 302:324–331.
9. **Chappuis CW, Cohn I Jr.** Acute colonic diverticulitis. *Surg Clin North Am* 1988; 68:301–313.
10. **Berman LG, Burdick D, Heitzman ER, Prior JT.** A critical reappraisal of sigmoid diverticulitis. *Surg Gynecol Obstet* 1968; 127:481–491.
11. **Morson BC.** The muscle abnormality in diverticular disease of the sigmoid colon. *Br J Radiol* 1963; 36:385–392.
12. **Perkins JD, Shield CF 3rd, Chang FC, Farha GJ.** Acute diverticulitis. Comparison of treatment in immunocompromised and nonimmunocompromised patients. *Am J Surg* 1984; 148:745–748.
13. **Cheskin LJ, Bohlman M, Schuster MM.** Diverticular disease in the elderly. *Gastroenterol Clin North Am* 1990; 19:391–403.
14. **Hiltunen KM, Kolehmainen H, Vuorinen T, Matikainen M.** Early water-soluble contrast enema in the diagnosis of acute colonic diverticulitis. *Int J Colorect Dis* 1991; 6:190–192.
15. **Verbanck J, Lambrecht S, Rutgeerts, et al.** Can sonography diagnose acute colonic diverticulitis in patients with acute intestinal inflammation? A prospective study. *J Clin Ultrasound* 1989; 17:661–666.
16. **Taylor KJ, Wasson JF, De Graaff C, Rosenfield AT, Andriole VT.** Accuracy of grey-scale ultrasound diagnosis of abdominal and pelvic abscesses in 220 patients. *Lancet* 1978; 1:83–84.
17. **Schwerk WB, Schwarz S, Rothmund M.** Sonography in acute colonic diverticulitis. A prospective study. *Dis Colon Rectum* 1992; 35:1077–1084.
18. **Stollman NH, Raskin JB.** Diagnosis and management of diverticular disease of the colon in adults. Ad Hoc Practice Parameters Committee of the American College of Gastroenterology. *Am J Gastroenterol* 1999; 94:3110–3121.



19. Kohler L, Sauerland S, Neugebauer E. Diagnosis and treatment of diverticular disease: results of consensus development conference. The Scientific Committee of the European Association for Endoscopic Surgery. *Surg Endoscop* 1999; 13:430-436.
20. Hulnick DH, Megibow AJ, Balthazar EJ, Naidich DP, Bosniak MA. Computed tomography in the evaluation of diverticulitis. *Radiology* 1984; 152:491-495.
21. Wong WD, Wexner SD, Lowry A, et al. Practice parameters for the treatment of sigmoid diverticulitis-supporting documentation. The Standards Task Force. The American Society of Colon and Rectal Surgeons. *Dis Colon Rectum* 2000; 43:290-297.
22. Hughes ESR, Cuthbertson AM, Carden ABG. The surgical management of acute diverticulitis. *Med J Aust* 1963; 1:780-782.
23. Hinchey EJ, Schaal PGH, Richards GK. Treatment of perforated diverticular disease of the colon. *Adv Surg* 1978; 12:85-109.
24. Neff CC, vanSonnenberg E. CT of diverticulitis. Diagnosis and treatment. *Radiol Clin North Am* 1989; 27(4):743-752.
25. Doring E. Computerized tomography of colonic diverticulitis. *Crit Rev Diagn Imaging* 1992; 33:421-435.
26. Detry R, Jomez J, Kartheuser A, et al. Acute localized diverticulitis: optimum management requires accurate staging. *Int J Colorectal Dis* 1992; 7:38-42.
27. Kellum JM, Sugerman HJ, Coppa GF, et al. Randomized, prospective comparison of cefoxitin and gentamycin-clindamycin in the treatment of acute colonic diverticulitis. *Clin Ther* 1992; 14:376-384.
28. Duma RJ, Kellum JM. Colonic diverticulitis: microbiologic, diagnostic, and therapeutic considerations. *Curr Clin Top Infect Dis* 1991; 11:218-247.
29. Elsagr R, Johnson DA, Younes Z, Oldfield EC 3rd. Antimicrobial treatment of intra-abdominal infections. *Dig Dis* 1998; 16:47-60.
30. Harisinghani MG, Gervais DA, Maher MM, et al. Transgluteal approach for percutaneous drainage of deep pelvic abscesses: 154 cases. *Radiology* 2003; 228:701-705.
31. Haglund U, Hellberg R, Johnsen C, Hulten L. Complicated diverticular disease of the sigmoid colon. An analysis of short and long term outcome in 392 patients. *Ann Chir Gynaecol* 1979; 68:41-46.
32. Konvolinka CW. Acute diverticulitis under age forty. *Am J Surg* 1994; 167:562-565.
33. Cunningham MA, Davis JW, Kaups KL. Medical versus surgical management of diverticulitis in patients under age 40. *Am J Surg* 1997; 174:733-736.
34. Spivak H, Weinrauch S, Harvey JC, Surick B, Ferstenberg H, Friedman I. Acute colonic diverticulitis in the young. *Dis Colon Rectum* 1997; 40:570-574.
35. Vignati PV, Welch JP, Cohen JL. Long-term management of diverticulitis in young patients. *Dis Colon Rectum* 1995; 38:627-629.
36. Kohler L, Sauerland S, Neugebauer E, et al. Diagnosis and treatment of diverticular disease: results of a consensus development conference. The Scientific Committee of the European Association for Endoscopic Surgery. *Surg Endosc* 1999; 13:430-436.
37. Muir EG. Safety in colonic resection. *Proc R Soc Med* 1968; 61:401-408.
38. Mueller PR, Saini S, Wittenburg J, et al. Sigmoid diverticular abscesses: percutaneous drainage as an adjunct to surgical resection in 24 cases. *Radiology* 1987; 164:321-325.
40. Stabile BE, Puccio E, vanSonnenberg E, Neff CC. Preoperative percutaneous drainage of diverticular abscesses. *Am J Surg* 1990; 159:99-104.
41. Neff CC, vanSonnenberg E, Casola G, et al. Diverticular abscesses: percutaneous drainage. *Radiology* 1987; 163:15-18.
42. Hachigian MP, Honickman S, Eisenstat TE, Rubin RJ, Salvati EP. Computed tomography in the initial management of acute left-sided diverticulitis [published erratum appears in *Dis Colon Rectum* 1993; 36:193]. *Dis Colon Rectum* 1992; 35:1123-1129.
42. Dudley HA, Radcliffe AG, McGeehan D. Intraoperative irrigation of the colon to permit primary anastomosis. *Br J Surg* 1980; 67:80-81.

.....
ADDRESS: James S. Wu, MD, Department of Colorectal Surgery, N32, Cleveland Clinic Beachwood Family Health Center, 26900 Cedar Road, Beachwood, OH 44122; Mark E. Baker, MD, Department of Radiology, Hb6, The Cleveland Clinic Foundation, 9500 Euclid Avenue, Cleveland, OH 44195.

Get current on women's health.



Get your copy of the *Cleveland Clinic Journal of Medicine's* new **Special Issue on Women's Health**.

This 104-page compilation of 15 peer-reviewed articles from recent issues of the CCJM will update you on a host of women's health topics, from new guidelines for cervical cancer screening to the current role of hormone therapy to the latest contraceptive options.

Supplies are limited, so get your copy today. Cost is \$18.00 per copy. Send check or money order, payable to *Cleveland Clinic Journal of Medicine*, to:

Cleveland Clinic Journal of Medicine
 Attn: Kathy Dunasky
 9500 Euclid Avenue, NA32
 Cleveland, OH 44195
 Email: dunaskk@ccf.org Phone: 216-445-3605
 Fax: 216-444-9385

Send issue to:

NAME _____

ADDRESS _____

CITY _____

STATE _____

ZIP _____