



# Update on Wegener granulomatosis

## CAROL A. LANGFORD, MD, MHS

Director, Center for Vasculitis Care and Research,  
Department of Rheumatic and Immunologic Diseases,  
The Cleveland Clinic Foundation

### ■ ABSTRACT

Wegener granulomatosis classically involves clinical disease of the upper airways, lungs, and kidneys. Ninety percent of patients present with symptoms involving the upper or lower airways, or both, and it should be suspected in any patient with pulmonary hemorrhage, glomerulonephritis, mononeuritis multiplex, unexplained multisystem disease, or progressive unresponsive sinus disease. Current treatments induce remission and allow long-term survival.

**A**LTHOUGH WEGENER GRANULOMATOSIS is uncommon, it is relevant to internists because it is a multisystem disease that presents in a variety of ways. This article covers how to recognize, diagnose, and treat this complex disease. Its etiology and future research areas are also discussed.

### ■ A VASCULITIC DISEASE

Wegener granulomatosis belongs to a diverse group of diseases involving vasculitis. Blood vessel inflammation leads to damage in two ways: by narrowing the vessel lumen, leading to organ ischemia, and by thinning the vessel wall, leading to aneurysms and hemorrhage.

Under the microscope, the nonrenal tissues show necrotizing granulomatous inflammation and vasculitis of small-to-medium vessels.

No definite trigger has been identified for Wegener granulomatosis. However, strong evidence supports the theory that the disease is immunologic.

### ■ AFFECTS UPPER AIRWAY, LUNGS, KIDNEYS

Wegener granulomatosis affects about 3 in 100,000 people—men and women equally—and can occur at any age (mean 41 years).

The classic clinical pattern is a triad involving the upper airways, lungs, and kidneys.<sup>1,2</sup>

**Upper airway involvement** occurs in 95% of cases. On physical examination, one may see inflammation of the nasal mucosa that gives it a cobblestone appearance. Computed tomography may show thickening of the sinus mucosa. Blood supply to the cartilaginous nasal septum may be disrupted, causing the nasal bridge to perforate or collapse.

Subglottic tracheal stenosis occurs in about 20% of patients. Patients suspected of having subglottic stenosis should be urgently referred to an otolaryngologist, as the encroachment of soft tissue on the trachea can become life-threatening.

**Lungs** are affected in about 85% of patients. Possible radiographic findings include bilateral nodular pulmonary infiltrates (most common), thin-walled and thick-walled cavities, and “ground-glass” infiltrates from alveolar hemorrhage (FIGURE 1).

**Kidneys.** Glomerulonephritis eventually develops in about 80% of patients, although only 20% have renal disease when they first present. The glomerulonephritis is usually asymptomatic and may progress rapidly and lead to renal failure. Clues are proteinuria and active urine sediment containing dysmorphic

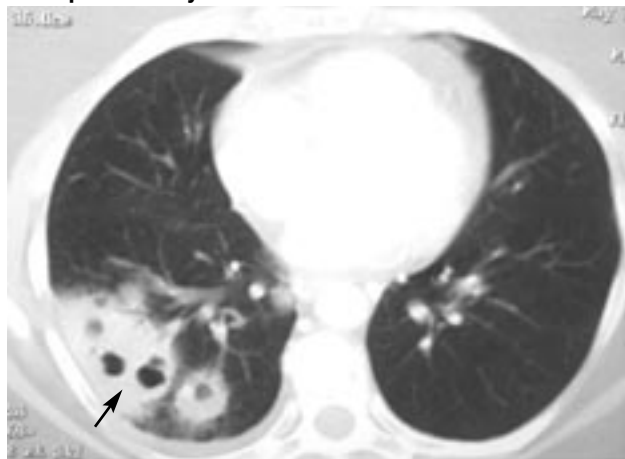
**The classic clinical pattern is a triad involving the upper airway, lungs, and kidneys**

No therapeutic agents are specifically approved for the treatment of Wegener granulomatosis. All references to a commercial product constitute an unlabeled use.

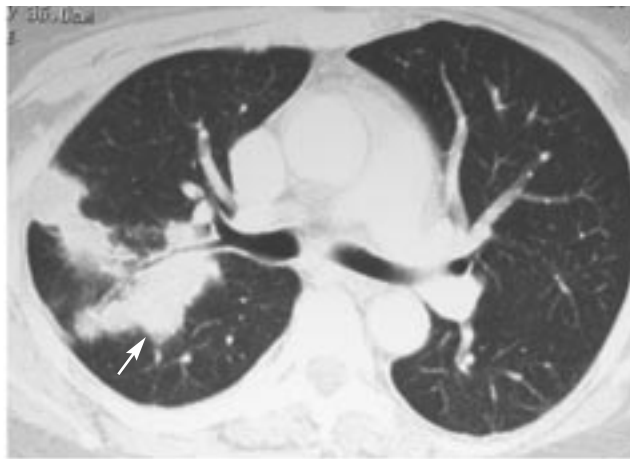
Medical Grand Rounds articles are based on edited transcripts from Division of Medicine Grand Rounds presentations at The Cleveland Clinic Foundation. They are approved by the author but are not peer-reviewed.

## Diversity of radiographic appearance in Wegener granulomatosis

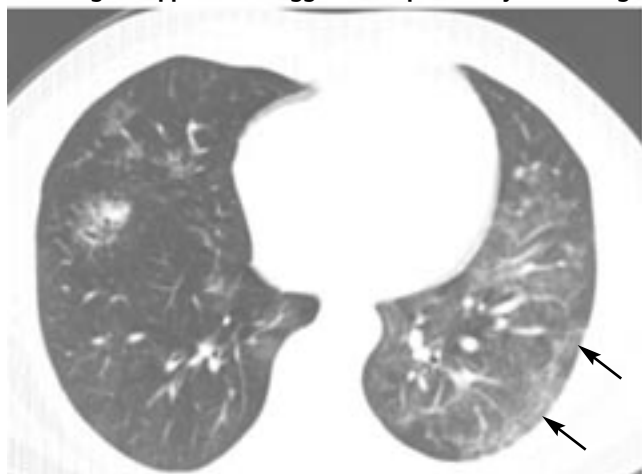
### Multiple cavitary lesions



### Nodular densities



### Ground glass appearance suggestive of pulmonary hemorrhage



### Pulmonary infiltrates

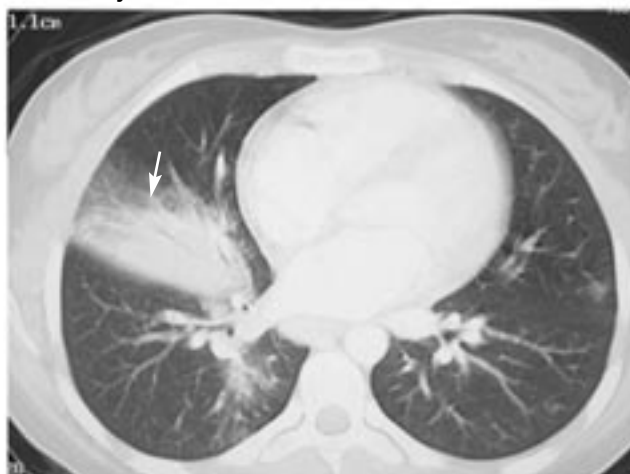

FIGURE 1.

red blood cells and red blood cell casts. Histologically, the glomerulonephritis is focal, segmental, crescentic, and necrotizing. It contains few or no immune complexes and has been referred to as a pauci-immune glomerulonephritis.

### Other sites of disease activity

**Joints and muscles.** About two thirds of patients develop pain in the joints or muscles, or joint swelling.

**Eyes** are involved in 56% of patients, and vision can be threatened. Almost any ocular structure can be affected: common problems include scleritis, episcleritis, and retro-orbital disease.

**Skin** is involved in 46% of patients, with

wart-like lesions—particularly around the elbow, palpable purpura, and nail-fold infarctions.

**Pericarditis** and **cerebral vasculitis** are serious complications, but each occurs in less than 5% of patients.

### When to suspect Wegener granulomatosis

Because of its multiorgan involvement and its wide range of disease severity, Wegener granulomatosis presents in a variety of ways. It should be considered in any patient presenting with:

- Pulmonary hemorrhage
- Glomerulonephritis
- Mononeuritis multiplex resulting in wrist or foot drop



- Progressive migratory arthralgias or arthritis (different joints involved within 1 to 2 days)
- Unexplained multisystem disease
- Sinus disease that does not respond to antibiotics, decongestants, or nasal steroids.

## ■ DIAGNOSIS

Diagnosing Wegener granulomatosis can be a challenge, but it is important to distinguish it from other diseases (TABLE 1). Immuno-suppressive therapy, which is appropriate for Wegener granulomatosis, can be catastrophic if the patient actually has an infection or certain other conditions.

**Biopsy** is not always diagnostic. Histologic changes tend to be patchy, requiring a lot of tissue for a positive yield.

Biopsy of the ear, nose, and throat is positive only about 20% of the time. The highest yield (91%) comes from open biopsy of radiographically abnormal pulmonary parenchyma. In contrast, transbronchial biopsy affords only a small amount of tissue and is positive in only 7% of cases.

Glomerulonephritis is typically focal and segmental with few or no immune deposits. Skin biopsy is usually insufficient for diagnosis, as the skin pathology of Wegener granulomatosis can also be found in other diseases.

Like Wegener granulomatosis, infection can also cause necrosis, granulomatous inflammation, and vasculitis histologically, so microorganisms must be ruled out with special stains.

**History.** Clues from a patient's history may indicate which organs are involved and for how long.

**Physical examination.** Particular attention should be paid to the nasal membranes, eyes, skin, joints, and nerves for clues of active disease.

**Chest radiography** should always be performed: up to one third of patients who have no pulmonary signs or symptoms have an abnormality on chest radiography.

**Laboratory tests** should include serum chemistries to evaluate renal function, a complete blood cell count, an erythrocyte sedimentation rate, urinalysis to look for red cell casts, and a blood test for antineutrophil cytoplasmic antibodies (ANCA).

**TABLE 1**

### Differential diagnosis of Wegener granulomatosis

#### Infection

#### Neoplasms

(especially lymphoproliferative disease)

#### Connective tissue disease

(eg, systemic lupus erythematosus, rheumatoid arthritis)

#### Other granulomatous disease

(eg, sarcoidosis)

#### Other causes of glomerulonephritis

(eg, anti-glomerular basement membrane disease, poststreptococcal nephritis)

### ANCA as a diagnostic tool

Commercial laboratories use two different methods to test for ANCA: indirect immunofluorescence (IIF) and testing for specific target antigens by enzyme-linked immunosorbent assay (ELISA).

In Wegener granulomatosis, 75% to 90% of patients with active disease have antibodies directed against proteinase 3 that produce a diffuse cytoplasmic staining by IIF (cANCA). Antibodies directed against myeloperoxidase occur in 5% to 20% of Wegener patients and produce a perinuclear staining by IIF (pANCA). Certain patients with Wegener granulomatosis may also be negative for ANCA.

Vasculitides associated with pANCA and cANCA include microscopic polyangiitis, pauci-immune crescentic glomerulonephritis, and Churg-Strauss syndrome, as well as other diseases. The strongest association, however, is between cANCA and Wegener granulomatosis.

A positive ANCA test by IIF should be confirmed by an antigen-specific ELISA test. In certain disorders, cANCA or pANCA tests can be positive while tests for the antiproteinase 3 or antimyeloperoxidase antigens are negative (TABLE 2).

In a meta-analysis of cANCA testing, Rao et al<sup>3</sup> found a pooled specificity of 98% (95% confidence interval [CI] 88%–100%), but a wide range of sensitivity (pooled sensitivity 66%, 95% CI 34%–92%).

In a rare disease like Wegener granulo-

**pANCA and cANCA are seen in various vasculitides, but the strongest association is between cANCA and Wegener**

TABLE 2

### A positive ANCA by immunofluorescence should be confirmed by antigen-specific ELISA

TEST RESULTS	ASSOCIATED CONDITIONS
Positive cANCA by IIF, and positive antiproteinase 3 by ELISA	Wegener granulomatosis Microscopic polyangiitis Churg-Strauss syndrome
Positive cANCA by IIF, and negative antiproteinase 3 by ELISA	Mostly infection in case reports
Positive pANCA by IIF, and positive antimyeloperoxidase by ELISA	Wegener granulomatosis Microscopic polyangiitis Churg-Strauss syndrome Idiopathic crescentic glomerulonephritis
Positive pANCA by IIF, and negative antimyeloperoxidase by ELISA	Inflammatory bowel disease Other autoimmune disease Infection Medications

IIF = indirect immunofluorescence, ELISA = enzyme-linked immunosorbent assay

**Long-term survival is now possible with cyclophosphamide, but the drug is toxic**

matosis, the positive predictive value, which also takes into account disease prevalence, is a more useful measure than the specificity of the likelihood that a patient with a positive test actually has the disease. Wegener granulomatosis is highly prevalent in patients who present with characteristic sinus, lung, and renal disease, and for such patients, the positive predictive value of cANCA is very high. However, since glomerulonephritis is present in only 20% at the time of presentation, most patients have only sinus or lung disease or both, and their potential for infection or neoplasm is higher. Because the prevalence of Wegener's granulomatosis in these patients is low, the positive predictive value of a positive cANCA test is poor. Hence, in most cases, biopsy is needed to confirm the diagnosis.

ANCA levels vary in an individual patient over time. In large series of Wegener granulomatosis, patients with active disease were more likely to have a positive ANCA test and have higher titers of the antibody.

However, titers do not correlate well enough with disease activity to be used as a basis for starting or adjusting immunosuppressive therapy. In two studies,<sup>4,5</sup> more than 40% of

patients who had a fourfold rise in titer did not relapse. Even patients who relapsed sometimes did so more than a year after the titer rose.

#### ■ TREATMENT

Patient survival is the foremost goal of treatment. However, the effectiveness of treatment has allowed broadening the goals to address issues of remission, relapse, and treatment toxicity.

Fifty years ago, no treatment was available, and patients died of pulmonary or renal failure after a median of 5 months.<sup>6</sup> The use of glucocorticoids, which was first reported in the mid-1960s, prolonged survival time to just over 1 year.<sup>7</sup>

#### **Prednisone plus cyclophosphamide**

In 1973, Fauci and Wolff<sup>8,9</sup> introduced a regimen that significantly improved outcome: prednisone 1 mg/kg daily, tapered and discontinued after 6 to 9 months, plus cyclophosphamide 2 mg/kg daily continued for 1 year past remission.

This regimen brought about complete remission in 75% of patients, marked improve-



ment in 91% (FIGURE 1), and survival in 80%.<sup>1</sup>

Unfortunately, at least half of patients who have a successful remission subsequently have a relapse.<sup>1</sup> Relapses are problematic, not only because of the potential for organ injury, but because of the need for repeat treatment, which causes serious morbidity in 42% of patients (TABLE 3).<sup>1</sup>

Cyclophosphamide is associated with transitional cell carcinoma of the bladder, which has occurred in 6% of patients to date. Some estimate that this figure may rise to 16% at 15 years after exposure to the drug.<sup>10</sup>

### Strategies to reduce toxicity

Various strategies to reduce cyclophosphamide toxicity have been tried.

**Staged treatment regimens.** Substituting other agents for cyclophosphamide after remission has been achieved is a possible way to reduce toxicity.

**Methotrexate.** In a study in 42 patients, methotrexate was substituted for cyclophosphamide after remission was induced. The rate of relapse (52%) was similar to that typically seen with cyclophosphamide maintenance, and the rate of serious toxicity was 10%.<sup>11,12</sup>

Methotrexate also has potential serious side effects, ie, bone marrow suppression, pneumonitis, hepatic fibrosis, mucositis, and nausea. Some effects can be reduced with folic acid 1 mg daily or folinic acid 5 to 10 mg each week taken 24 hours after methotrexate.

Methotrexate is contraindicated in patients with renal insufficiency (creatinine concentration > 2.0 mg/dL), hepatic disease, or severe chronic pulmonary impairment, conditions often present in patients with Wegener granulomatosis.

**Azathioprine**, a purine antimetabolite, can be used in the setting of renal insufficiency. Recently, 155 patients with generalized vasculitis were initially treated with prednisolone and cyclophosphamide, then at remission were randomized either to continue cyclophosphamide for up to 1 year or to switch to azathioprine. Rates of relapse were similar with both therapies.<sup>13</sup>

Serious side effects of azathioprine include bone marrow suppression, infection, severe allergic reaction, gastrointestinal intolerance,

**TABLE 3**

### Complications of prednisone-plus-cyclophosphamide treatment for Wegener granulomatosis

COMPLICATION	% OF PATIENTS
Sterility	> 50
Major infection	46
Cystitis	43
Cataracts	21
Fractures	11
Bladder cancer	3
Avascular necrosis	3
Lymphoma	2
Myelodysplasia	2

DATA FROM HOFFMAN GS, KERR GS, LEAVITT RY, ET AL. WEGENER GRANULOMATOSIS: AN ANALYSIS OF 158 PATIENTS. ANN INTERN MED 1992; 116:488-498.

and in transplant recipients, a 1% to 2% rate of leukemia and lymphoma.

**Mycophenolate mofetil** was approved for preventing renal transplant rejection in 1995. It was used in two small open-label trials<sup>14,15</sup> to maintain remission in patients with Wegener granulomatosis after initial treatment with cyclophosphamide. In both studies it was well tolerated, but the relapse rate was 43% in one study.<sup>15</sup>

**Intermittent intravenous cyclophosphamide** is effective for lupus nephritis and may be less toxic than daily oral administration. However, studies in Wegener granulomatosis have found a higher rate of relapse with intermittent intravenous therapy vs daily oral treatment. The studies have not had sufficient power to establish whether the treatments are equally effective.<sup>16-18</sup>

**Using another agent to induce remission** is another possible strategy for patients with less severe illness.<sup>19-21</sup> Sneller et al,<sup>20</sup> in an open-label trial, treated 42 patients who had active but not severe disease with combined methotrexate (20-25 mg once a week) and prednisone (1 mg/kg daily with taper) and reported rates of remission of 79%, survival 93%, relapse 58%, and serious toxicity 17%.

Other agents used as a substitute for cyclophosphamide in case reports and small series include cyclosporine, chlorambucil, leflunomide, and intravenous immunoglob-

**Azathioprine or methotrexate may be substituted for cyclophosphamide after remission**

ulin. These should be considered only when standard medications are contraindicated because of concerns about efficacy and toxicity.

### Use of trimethoprim-sulfamethoxazole

Reports from the 1980s suggest that trimethoprim-sulfamethoxazole may help patients with upper airway disease, although whether the benefit is due to its antimicrobial action is uncertain. It can be considered for the treatment of isolated upper airway disease under close monitoring for the emergence of other disease features, but should never be used alone to treat glomerulonephritis or major-organ disease.

Stegeman et al<sup>22</sup> randomized 81 patients who were in remission to receive either trimethoprim-sulfamethoxazole or placebo and found that while the recurrence rate of nasal and upper airway lesions was lower with drug therapy, there was no difference in the relapse rate of major-organ disease.

Trimethoprim-sulfamethoxazole does, however, play an important role in preventing *Pneumocystis carinii* pneumonia, which occurs in about 10% of patients receiving induction therapy and can have a 35% mortality rate. We recommend prophylaxis with trimethoprim-sulfamethoxazole (one double-strength tablet 3 times per week) for all patients who are not allergic to sulfa drugs and who are receiving glucocorticoids plus a cytotoxic agent. For patients with sulfa allergy, other considerations include dapsone, inhaled pentamidine, or atovaquone.

### Treating subglottic stenosis

Subglottic stenosis is frequently unresponsive to systemic immunosuppressive therapy, largely because of fibrotic scarring following inflammation. It is treated with mechanical dilation of the trachea and intratracheal injection of a long-acting glucocorticoid.<sup>23</sup>

## ■ AREAS OF RESEARCH

Biologic agents that directly target specific immunologic components are being studied for their potential to reduce drug toxicity, prevent relapse, and even induce remission. Cautious investigation of these agents is necessary, as specific targeting may not be suffi-

cient to modulate the complex pathways involved, and unexpected effects on the disease and toxicities may arise.


**Etanercept.** Granulomas, a pathognomonic feature of Wegener granulomatosis, are initiated and maintained with the help of CD4 T cells with a Th-1 pattern. Data from the laboratory suggest that patients with Wegener granulomatosis may have an unbalanced Th-1 cytokine response, as suggested by high levels of interferon gamma and tumor necrosis factor (TNF).<sup>24-27</sup>

Etanercept, which is used in treating rheumatic diseases, binds to TNF and prevents it from binding to receptors on cells.

Stone et al<sup>28</sup> treated 20 patients with Wegener granulomatosis with standard therapy plus etanercept for 6 months in a phase I trial and found the drug to be well tolerated. In the randomized, double-blind Wegener's Granulomatosis Etanercept Trial,<sup>29</sup> 180 patients were treated with standard therapy plus etanercept or placebo. There were no differences between the etanercept and placebo groups in rates of sustained remission, time to sustained remission, or numbers of disease flares. These findings do not provide support for the use of etanercept in either the induction or the maintenance of remission in patients with Wegener granulomatosis.

**Infliximab,** a chimeric monoclonal antibody that binds to TNF, has also been studied, but only in very small, short-term studies using concurrent nonstandardized therapies.<sup>30-33</sup>

**Rituximab.** B cells are the precursors of plasma cells, which produce ANCA. Rituximab, a chimeric monoclonal antibody, binds to the CD-20 antigen found on normal and malignant B cells. It has been approved for treating B-cell non-Hodgkin lymphoma and has been investigated for other diseases in which B cells may play a role. Rituximab has side effects, including severe infusion reactions that sometimes result in death.

Rituximab showed promising results in a patient with resistant relapsing Wegener granulomatosis,<sup>34</sup> and in an open-label trial.<sup>35</sup> A multicenter randomized clinical trial has been undertaken to determine if rituximab can induce remission as effectively as cyclophosphamide. 

**Trimethoprim-sulfamethoxazole prevents *P carinii* pneumonia in patients on glucocorticoids plus cytotoxic drugs**



## ■ REFERENCES

1. Hoffman GS, Kerr GS, Leavitt RY, et al. Wegener granulomatosis: an analysis of 158 patients. *Ann Intern Med* 1992; 116:488–498.
2. Reinhold-Keller E, Beuge N, Latza U, et al. An interdisciplinary approach to the care of patients with Wegener's granulomatosis: long-term outcome in 155 patients (erratum appears in *Arthritis Rheum* 2000; 43:2379). *Arthritis Rheum* 2000; 43:1021–1032.
3. Rao JK, Weinberger M, Oddone EZ, Allen NB, Landsman P, Feussner JR. The role of antineutrophil cytoplasmic antibody (c-ANCA) testing in the diagnosis of Wegener granulomatosis. A literature review and meta-analysis. *Ann Intern Med* 1995; 123:925–932.
4. Kerr GS, Fleisher TA, Hallahan CW, Leavitt RY, Fauci AS, Hoffman GS. Limited prognostic value of changes in antineutrophil cytoplasmic antibody titer in patients with Wegener's granulomatosis. *Arthritis Rheum* 1993; 36:365–371.
5. Boomsma MM, Stegeman CA, van der Leij MJ, et al. Prediction of relapses in Wegener's granulomatosis by measurement of antineutrophil cytoplasmic antibody levels: a prospective study. *Arthritis Rheum* 2000; 43:2025–2033.
6. Walton EW. Giant-cell granuloma of the respiratory tract (Wegener's granulomatosis). *Br Med J* 1958; 34:265–270.
7. Hollander D, Manning RT. The use of alkylating agents in the treatment of Wegener's granulomatosis. *Ann Intern Med* 1967; 67:393–398.
8. Fauci AS, Wolff SM. Wegener's granulomatosis: studies in eighteen patients and a review of the literature. *Medicine (Baltimore)* 1973; 52:535–561.
9. Fauci AS, Haynes BF, Katz P, Wolff SM. Wegener's granulomatosis: prospective clinical and therapeutic experience with 85 patients for 21 years. *Ann Intern Med* 1983; 98:76–85.
10. Talar-Williams C, Hijazi YM, Walther MM, et al. Cyclophosphamide-induced cystitis and bladder cancer in patients with Wegener granulomatosis. *Ann Intern Med* 1996; 124:477–484.
11. Langford CA, Talar-Williams C, Barron KS, Sneller MC. A staged approach to the treatment of Wegener's granulomatosis: induction of remission with glucocorticoids and daily cyclophosphamide switching to methotrexate for remission maintenance. *Arthritis Rheum* 1999; 42:2666–2673.
12. Langford CA, Talar-Williams C, Barron KS, Sneller MC. Use of a cyclophosphamide-induction methotrexate-maintenance regimen for the treatment of Wegener's granulomatosis: extended follow-up and rate of relapse. *Am J Med* 2003; 114:463–469.
13. Jayne D, Rasmussen N, Andrassy K, et al. A randomized trial of maintenance therapy for vasculitis associated with antineutrophil cytoplasmic autoantibodies. *N Engl J Med* 2003; 349:36–44.
14. Nowack R, Gobel U, Klooker P, Hergesell O, Andrassy K, van der Woude FJ. Mycophenolate mofetil for maintenance therapy of Wegener's granulomatosis and microscopic polyangiitis: a pilot study in 11 patients with renal involvement. *J Am Soc Nephrol* 1999; 10:1965–1971.
15. Langford CA, Talar-Williams C, Sneller MC. Mycophenolate mofetil for remission maintenance in the treatment of Wegener's granulomatosis. *Arthritis Rheum* 2004; 51:278–283.
16. Hoffman GS, Leavitt RY, Fleisher TA, Minor JR, Fauci AS. Treatment of Wegener's granulomatosis with intermittent high-dose intravenous cyclophosphamide. *Am J Med* 1990; 89:403–410.
17. Reinhold-Keller E, Kekow J, Schnabel A, et al. Influence of disease manifestation and antineutrophil cytoplasmic antibody titer on the response to pulse cyclophosphamide therapy in patients with Wegener's granulomatosis. *Arthritis Rheum* 1994; 37:919–924.
18. Guillevin L, Cordier JF, Lhote F, et al. A prospective, multicenter, randomized trial comparing steroids and pulse cyclophosphamide versus steroids and oral cyclophosphamide in the treatment of generalized Wegener's granulomatosis. *Arthritis Rheum* 1997; 40:2187–2198.
19. Hoffman GS, Leavitt RY, Kerr GS, Fauci AS. The treatment of Wegener's granulomatosis with glucocorticoids and methotrexate. *Arthritis Rheum* 1992; 35:1322–1329.
20. Sneller MC, Hoffman GS, Talar-Williams C, Kerr GS, Hallahan CW, Fauci AS. An analysis of forty-two Wegener's granulomatosis patients treated with methotrexate and prednisone. *Arthritis Rheum* 1995; 38:608–613.
21. Langford CA, Sneller MC, Hoffman GS. Methotrexate use in systemic vasculitis. *Rheum Dis Clin North Am* 1997; 23:841–853.
22. Stegeman CA, Tervaert JW, de Jong PE, Kallenberg CG. Trimethoprim-sulfamethoxazole (co-trimoxazole) for the prevention of relapses of Wegener's granulomatosis. Dutch Co-Trimoxazole Wegener Study Group. *N Engl J Med* 1996; 335:16–20.
23. Langford CA, Sneller MC, Hallahan CW, et al. Clinical features and therapeutic management of subglottic stenosis in patients with Wegener's granulomatosis. *Arthritis Rheum* 1996; 39:1754–1760.
24. Ludviksson BR, Sneller MC, Chua KS, et al. Active Wegener's granulomatosis is associated with HLA-DR+ CD4+ T cells exhibiting an unbalanced Th1-type T cell cytokine pattern: reversal with IL-10. *J Immunol* 1998; 160:3602–3609.
25. Csernok E, Trabandt A, Muller A, et al. Cytokine profiles in Wegener's granulomatosis: predominance of type 1 (Th1) in the granulomatous inflammation. *Arthritis Rheum* 1999; 42:742–750.
26. Balding CE, Howie AJ, Drake-Lee AB, Savage CO. Th2 dominance in nasal mucosa in patients with Wegener's granulomatosis. *Clin Exp Immunol* 2001; 125:332–339.
27. Komocsi A, Lamprecht P, Csernok E, et al. Peripheral blood and granuloma CD4(+)CD28(-) T cells are a major source of interferon-gamma and tumor necrosis factor-alpha in Wegener's granulomatosis. *Am J Pathol* 2002; 160:1717–1724.
28. Stone JH, Uhlfelder ML, Hellmann DB, Crook S, Bedocs NM, Hoffman GS. Etanercept combined with conventional treatment in Wegener's granulomatosis: a six-month open-label trial to evaluate safety. *Arthritis Rheum* 2001; 44:1149–1154.
29. Wegener's Granulomatosis Etanercept Trial (WGNET) Research Group. Etanercept plus standard therapy for Wegener's granulomatosis. *N Engl J Med* 2005; 352:351–361.
30. Specks U, Fervenza FC, McDonald TJ, Hogan MC. Response of Wegener's granulomatosis to anti-CD20 chimeric monoclonal antibody therapy. *Arthritis Rheum* 2001; 44:2836–2840.
31. Keogh KA, Wylam ME, Stone JH, Specks U. Induction of remission by B lymphocyte depletion in eleven patients with refractory antineutrophil cytoplasmic antibody-associated vasculitis. *Arthritis Rheum* 2005; 52:262–268.
32. Booth AD, Jefferson HJ, Ayliffe W, Andrews PA, Jayne DR. Safety and efficacy of TNF alpha blockade in relapsing vasculitis. *Ann Rheum Dis* 2002; 61:559.
33. Bartolucci P, Ramanoelina J, Cohen P, et al. Efficacy of the anti-TNF-alpha antibody infliximab against refractory systemic vasculitides: an open pilot study on 10 patients. *Rheumatology (Oxford)* 2002; 41:1126–1132.
34. Lamprecht P, Voswinkel J, Lillenthal T, et al. Effectiveness of TNF-alpha blockade with infliximab in refractory Wegener's granulomatosis. *Rheumatology (Oxford)* 2002; 41:1303–1307.

ADDRESS: Carol Langford, MD, MHS, Director, Center for Vasculitis Care and Research, Department of Rheumatic and Immunologic Diseases, A50, The Cleveland Clinic Foundation, 9500 Euclid Avenue, Cleveland, OH 44195.