



# Vaginal vault prolapse: Identification and surgical options

DANIEL H. BILLER, MD, AND G. WILLY DAVILA, MD

**M**aintenance of normal vaginal anatomy depends on the interrelationships of intact pelvic floor neuromusculature, ligaments, and fascia. This complexity of anatomic support is becoming better understood. Perhaps the least well understood area of vaginal support is the coalescence of ligaments and fascia at the vaginal apex or vault. As a result, identification of vaginal vault prolapse in a woman with an advanced degree of vaginal prolapse can be challenging. Surgical failure in any or all compartments is likely if support to the vaginal apex is not restored during operative therapy. This paper reviews the identification of vaginal vault prolapse by physical examination and the effective surgical options available to the reconstructive surgeon.

## ■ NORMAL VAULT SUPPORT ANATOMY

The vaginal apex represents a site where multiple important support structures coalesce.<sup>1</sup> If present, the cervix serves as an obvious strong attachment point. However, in a woman who has had a hysterectomy, the support structures lack a strong attachment site, resulting in support weakness and prolapse. The support structures include ligaments and endopelvic fascia (**Figure 1**), as detailed below.

---

From the Section of Urogynecology and Reconstructive Pelvic Surgery, Department of Gynecology, Cleveland Clinic Florida, Weston, FL.

**Address:** G. Willy Davila, MD, Section of Urogynecology and Reconstructive Pelvic Surgery, Department of Gynecology, Cleveland Clinic Florida, 2950 Cleveland Clinic Boulevard, Weston, FL 33331; [davilag@ccf.org](mailto:davilag@ccf.org).

**Disclosure:** Dr. Biller reported that he has no financial interests or affiliations that pose a potential conflict of interest with this article. Dr. Davila reported that he has received grant/research support from American Medical Systems, Synovis Surgical Innovations, Adamed, and Tyco Healthcare/U.S. Surgical and that he is a consultant for and on the speakers' bureau of American Medical Systems.

## Ligaments

**The uterosacral ligaments** are peritoneal and fibromuscular tissue bands extending from the apex to the sacrum. They are considered the principal support structures for the vaginal apex, despite their apparent lack of significant strength.

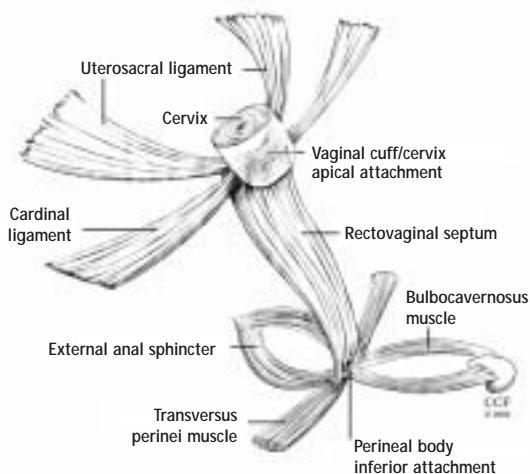
**The cardinal ligaments** extend laterally from the apex to the pelvic sidewall adjacent to the ischial spine. Their role in support is less clear, as their course is less well understood. In addition, since they lie in proximity to the ureters, their use in restoring vault support by shortening or reattaching them to the apex is less attractive, unlike the uterosacral ligaments.

It is the coalescence of both ligaments, in the uterosacral-cardinal ligament complex (UCLC), that is likely crucial to maintaining vault support. In a woman who has had a hysterectomy, identifying the site of the UCLC attachment to the cuff (seen on vaginal examination as apical "dimples") is key to identifying the presence of vault prolapse.

## Endopelvic fascia

The fibromuscular tissue layer that underlies the vaginal epithelium has been termed *endopelvic fascia*. Although its actual composition is somewhat controversial, it has been noted to envelop the entire vaginal canal, extending from apex to perineum and from arcus tendenius to arcus tendenius. Much like the abdominal wall aponeurosis, it maintains integrity of the anterior and posterior vaginal walls. A tear in this layer—along its lateral, inferior, or apical edges, or stretching along its central portion—will lead to herniation of the underlying tissues. If the fascial layer becomes detached from the vaginal apex, a true hernia can develop in the form of an enterocele, which can be anterior or posterior. This can lead, in turn, to further weakening of vaginal vault integrity.

Reconstructive surgeons recently have begun to espouse the concept that many cystoceles and rectoceles actually originate as a detachment of the endopelvic fascia from the vaginal apex. It is critical to restore



**FIGURE 1.** Ligamentous and fascial supports of the vaginal apex or cervix.

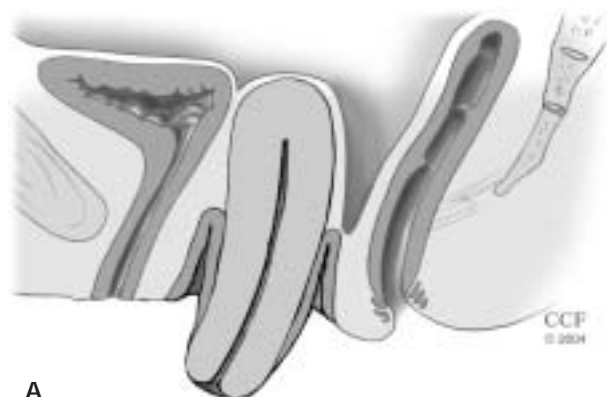anterior and posterior vaginal wall fascial integrity from apex to perineum by reattaching the patient's endogenous fascia to the vaginal apex, or augmenting the repair using a biologic or synthetic graft.

#### ■ IDENTIFICATION OF VAGINAL VAULT PROLAPSE

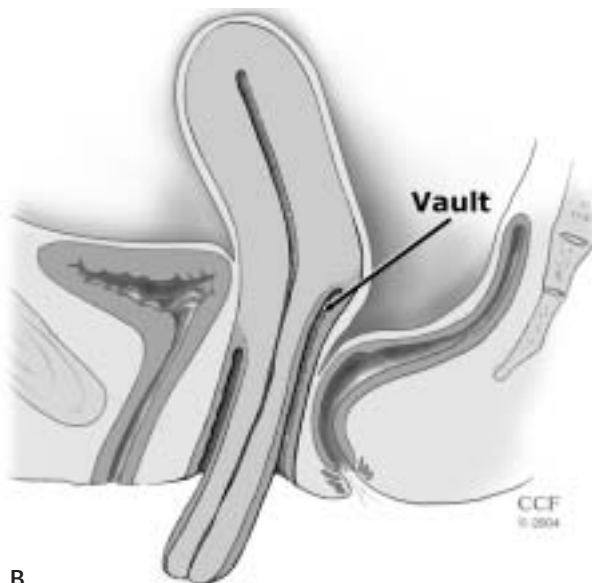
When managing a patient with an advanced degree of vaginal prolapse, it is imperative to ascertain whether vaginal vault prolapse, with or without associated enterocele, is present. A careful and structured pelvic examination is therefore required. Whether the uterus is present or not, it may be difficult to evaluate the degree of vault support. The tools required include a bivalved speculum and a right-angled retractor, or the posterior blade of another gynecologic speculum.

#### When the uterus is present

The presence of an exteriorized cervix does not mean vault prolapse is present. In the presence of significant cervical hypertrophy or elongation, the cervix may be exteriorized while the apex is well supported (**Figure 2**). The right-angled speculum blade should be placed in the posterior fornix (behind the cervix) and inserted to its full extent. If vault prolapse is present, upon Valsalva efforts, as the speculum is removed slowly, the uterus will descend further. Reinsertion of the speculum will resuspend the uterus. If the vault is well supported, the cervix will remain in place despite Valsalva efforts. An approximation of the degree of vault prolapse can be made during this maneuver, and the effectiveness of a McCall culdoplasty in restoring vault support can be ascertained. If using the POP-Q prolapse quantification system, a patient with cervical hyper-



A



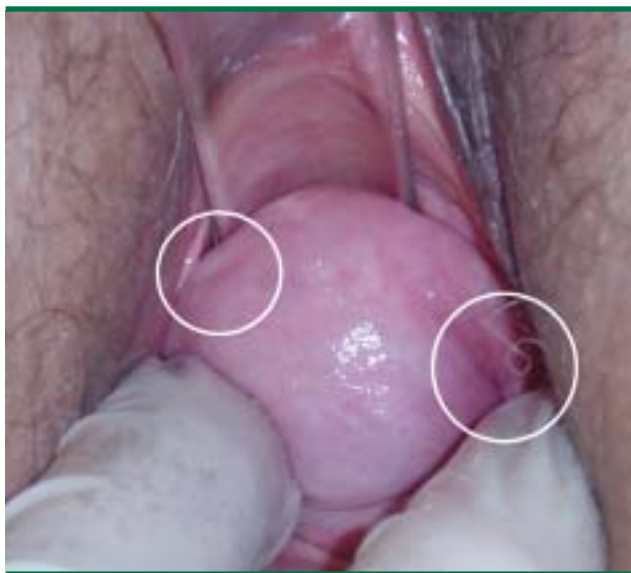B

**FIGURE 2.** Cervical prolapse may be associated with vault prolapse (A) or may not (cervical hypertrophy without vault prolapse) (B).

trophy and no vault prolapse will have a positive point C with a well-supported point D which will equal the total vaginal length (TVL). If a uterine suspension is performed in the face of significant cervical hypertrophy, cervical prolapse may persist, requiring partial amputation (ie, Manchester procedure).

#### When the patient has had a prior hysterectomy

It may be quite difficult to identify vault prolapse in a woman who has undergone a previous hysterectomy. The goal during physical examination will be to identify the apical scar tissue (cuff) resulting from the hysterectomy. In most patients, the cuff can be seen as a transverse band of tissue firmer than the adjacent vaginal walls. In a patient with extensive prolapse, the tissue is stretched and the cuff tissue is less obvi-



**FIGURE 3.** Vault prolapse associated with extensive exteriorized prolapse can be identified by the presence of scarring sites from previous uterosacral ligament attachments.

ous. Using a bivalved speculum can help visualize the apex, but in women with extensive prolapse the redundant vaginal tissue may make visualization difficult. Fortunately, the sites of previous UCLC attachment can usually be identified as “dimples” on either side of the midline at the cuff (**Figure 3**). Using both right-angled speculum blades, or one blade along the anterior vaginal wall and the examiner’s index and middle fingers along the posterior vaginal wall, the dimples can usually be identified. The patient is asked to perform a Valsalva maneuver. The tip of the speculum can then be placed between the dimples, the vault elevated, and the degree of vault prolapse determined. This can then be confirmed during digital examination by identifying the dimples by tact and elevating them to their ipsilateral ischial spines.

#### Accuracy of the pelvic exam is key

The importance of an accurate pelvic examination cannot be overemphasized. In addition to assessing the degree and type of prolapse present, it is important to perform the examination with surgical planning in mind if the patient is considering surgical therapy. The presence of any fascial tears or defects can usually be predicted during careful vaginal examination, and usually identified by an area of abrupt change in vaginal wall thickness. A standing examination may be necessary to assess the full extent of the prolapse, and bimanual examination (one finger

in the vagina and one finger in the rectum) can sometimes help to detect enterocele.

#### ■ FACTORS THAT GUIDE THE SURGICAL APPROACH

The goals for repair of vaginal vault prolapse include normalizing support of all anatomic compartments, alleviating clinical symptoms, and optimizing sexual, bowel, and bladder function. Care must be taken to restore normal anatomy and function to all compartments, without precipitating new support or functional problems. A thorough evaluation as described above is necessary before surgical correction.

Currently, most surgeons prefer a vaginal approach to pelvic reconstruction. However, the choice of approach should be based on what is best for the patient’s individual variables. The following factors are particularly important when planning a surgical approach for vault prolapse.

**Importance of sexual function.** If the patient reports that vaginal sexual function is of great importance to her (age may be an unrelated issue here), a sacrocolpopexy should be primarily considered, as it avoids vaginal incisions and associated potential vaginal narrowing/shortening.

**Vaginal length.** A patient whose vaginal apex (dimples) reaches the ischial spines with ease will do well with a vaginal procedure, whereas a patient whose dimples either do not reach or extend far above the ischial spines may be better served by an abdominal sacrocolpopexy or an obliterative procedure, if appropriate.

**Previous reconstructive procedures.** The degree of existent scarring and fibrosis must be kept in mind, as the area around the sacral promontory, or sacrospinous ligaments, may be difficult or risky to reach. This is especially important in this age of commonplace graft use.

**Presence of large paravaginal defects.** Although paravaginal defect repairs can be performed vaginally, they can be technically difficult and their long-term outcomes have not been reported. Thus, an abdominal approach may be better if significant paravaginal defects are present.

**Medical comorbidities.** For a medically delicate patient or a patient of advanced age, a vaginal, if not obliterative, procedure under regional anesthesia is preferable.

**Tissue quality and presence of large fascial defects.** Tissue quality will usually improve with preoperative local estrogen therapy (see final article in this supplement), but large fascial defects may require graft reinforcement, which can be routinely accomplished either abdominally or vaginally.

**Associated colorectal problems.** The frequent

coexistence of colorectal dysfunction in women with vault prolapse requires that these problems be kept in mind during surgical planning. It may be best for a woman with extensive rectal prolapse to undergo a concomitant Ripstein rectopexy and sacrocolpopexy, or a perineal proctosigmoidectomy and vaginal-approach vault suspension.

## ■ VAGINAL PROCEDURE OPTIONS

### McCall culdoplasty

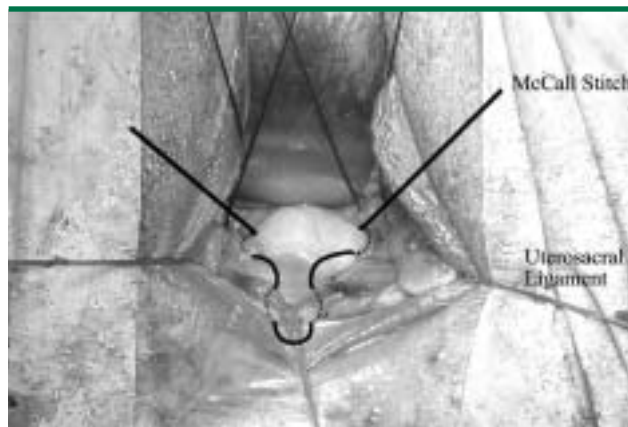
The technique of plicating the uterosacral ligaments in the midline while reefing the peritoneum in the cul-de-sac, combined with a posterior culdoplasty, was introduced by McCall in 1957. This technique, most commonly performed at the time of vaginal hysterectomy, typically uses nonabsorbable sutures to incorporate both uterosacral ligaments, intervening cul-de-sac peritoneum, and full-thickness apical vaginal mucosa. Delayed absorbable sutures may also be used. Multiple sutures may be required if extensive prolapse is present. As a general rule, we try to place our uppermost suture on the uterosacral ligaments at a distance from the cuff equal to the amount of vault prolapse that is present (ie, POP-Q: TVL minus point D [or point C if uterus is absent]) (Figure 4).

Care must be taken not to injure or kink the ureters when placing the suture through the uterosacral ligaments, as the ureters lie 1 to 2 cm lateral at the level of the cervix. We recommend cystoscopy with visualization of ureteral patency following the procedure. Intravenous indigo carmine, with attention to bilateral ureteral spill, is particularly helpful. Reported success rates are high,<sup>2</sup> but objective long-term data are limited.

### Uterosacral ligament suspension

Excellent anatomic outcomes have been described with reattachment of the uterosacral ligaments to the vaginal apex, a procedure similar to the McCall technique. The physiologic nature of this technique makes it very attractive.

The technique involves opening the vaginal wall from anterior to posterior over the apical defect and identifying the pubocervical fascia, rectovaginal fascia, and uterosacral ligaments. One permanent 1-0 suture and one delayed absorbable 1-0 suture are placed in the posteromedial aspect of each uterosacral ligament, 1 to 2 cm proximal and medial to each ischial spine. One arm of each permanent suture is then placed through the pubocervical and rectovaginal fascia, and one arm of each delayed absorbable suture is placed in a similar fashion but also incorporating the vaginal epithelium. After all



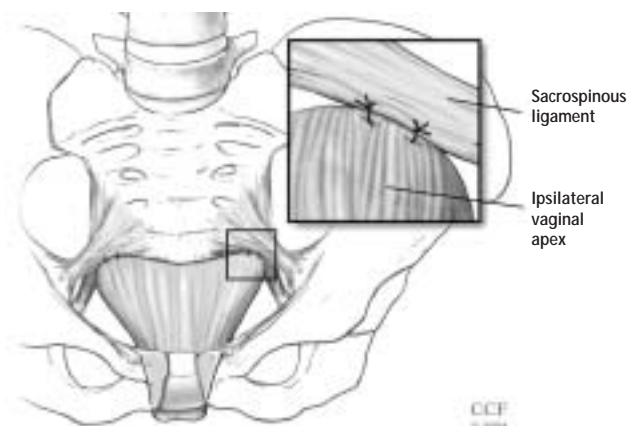
**FIGURE 4.** McCall culdoplasty at the time of vaginal hysterectomy. Monofilament sutures are placed through the uterosacral ligaments (at a distance from the cuff of total vaginal length [TVL] minus point D [cm]) and the full thickness of the apical vaginal wall.

additional defects are repaired, the sutures are tied, suspending the vault. In cases of extensive prolapse, redundant peritoneum makes identifying the uterosacral ligaments and endopelvic fascia challenging. Success rates range from 87% to 90%, but ureteral injury is a limiting factor, with rates as high as 11%.<sup>3</sup> Therefore, cystoscopy is essential. Long-term results are lacking.

### Iliococcygeus suspension

Elevation of the vaginal apex to the iliococcygeus muscles along the lateral pelvic sidewall may be the simplest way of addressing vault prolapse. It can be performed without a vaginal incision by placing a monofilament permanent suture (ie, polypropylene) at full thickness through the vaginal wall into the muscle, either unilaterally or bilaterally to resuspend the apex. The main utility of this iliococcygeus suspension procedure is in the management of isolated unilateral vaginal vault prolapse, which can occur following an opposite-side unilateral sacrospinous fixation, or from a unilateral high paravaginal detachment. In a patient who is not sexually active, the presence of an intravaginal monofilament suture at the vaginal apex should not be associated with dyspareunia and should not cause significant granulation tissue. Therefore, this procedure is most useful as an adjunct or salvage procedure for a patient with an isolated apical unilateral defect.

Iliococcygeus suspension can also be performed following a posterior vaginal wall dissection and entering the pararectal space. The sutures are placed into the fascia overlying the iliococcygeus muscle, anterior to the ischial spine and inferior to the arcus tendineus fasciae pelvis, and incorporated into the pubocervical fas-



**FIGURE 5.** Bilateral sacrospinous fixation.

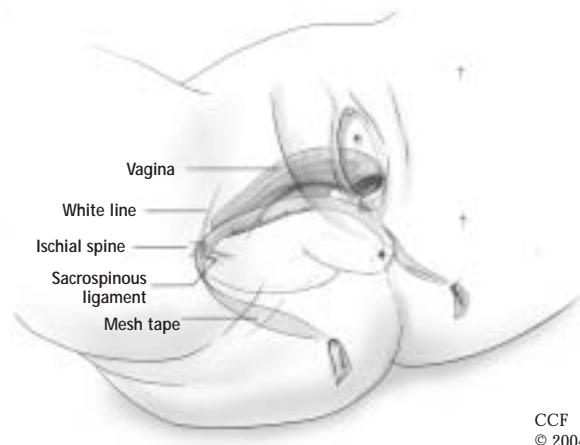
cia anteriorly and the rectovaginal fascia posteriorly.

Shull et al<sup>4</sup> reported a 95% cure rate of the apical compartment following iliococcygeus suspension among 42 women who were followed up for 6 weeks to 5 years. However, 6 of the women (14%) had occurrence of prolapse at other sites during the follow-up period.<sup>4</sup> A randomized trial comparing iliococcygeus suspension with sacrospinous fixation demonstrated similar satisfactory outcomes.<sup>5</sup>

### Sacrospinous fixation

Elevation of the vaginal apex to the sacrospinous ligament is one of the most commonly performed vaginal-approach vault suspension procedures. It can be performed unilaterally or bilaterally, depending on surgeon preference. The pararectal space is entered after a posterior wall dissection, after which the surgeon identifies the ischial spine and sacrospinous ligament extending from the spine to the sacrum. Anterior and mid-compartment approaches to the sacrospinous space have also been described. Two nonabsorbable sutures are placed *through* the ligament, rather than around it (**Figure 5**). Placement of the sutures in this fashion is important, as the pudendal nerve, artery, and vein are located immediately deep to the sacrospinous ligament, and damage to these structures can cause significant morbidity.

The first suture is placed 2 cm medial to the ischial spine, and the second 1 cm medial to the first. Each suture is then passed through the underside of the vaginal apex—in the midline if the procedure is done unilaterally, and under each apex if done bilaterally.



**FIGURE 6.** Schematic of the Apogee system for vault prolapse, which involves the creation of neo-cardinal ligaments.

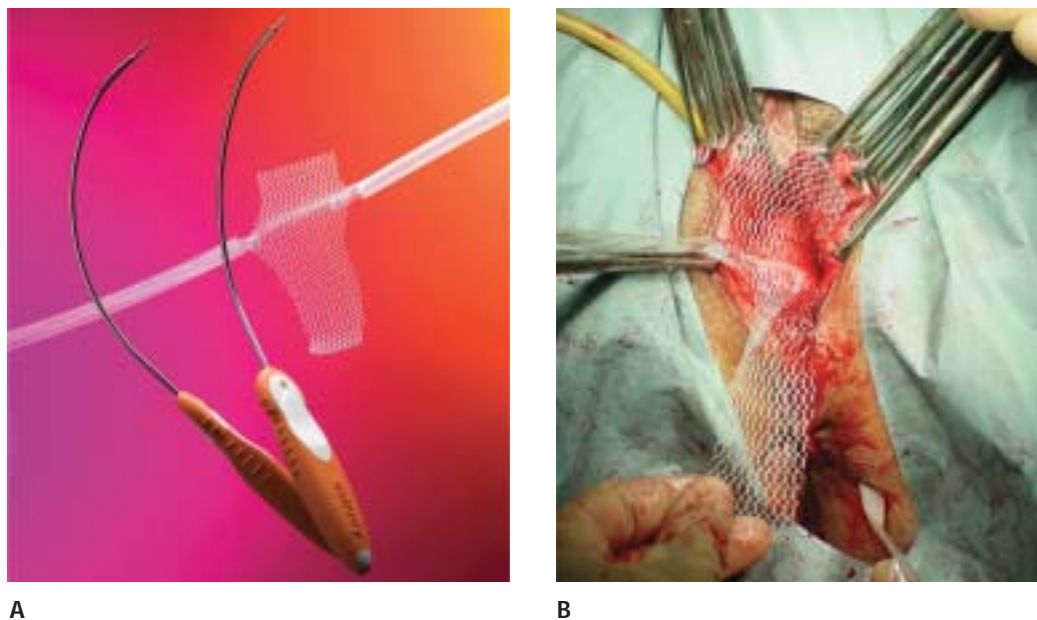
When tied, the sutures suspend the vaginal apex by approximating the apex to the ligament, ideally without a suture bridge.<sup>6</sup> Any additional reconstructive procedures are then performed.

The bilateral approach (**Figure 5**) may provide a more physiologic correction of vaginal vault prolapse. Reinforcement of each vaginal apex with a graft does not appear to improve the success rate. The success rate of the sacrospinous fixation and restoration of vaginal vault support is greater than 90% in multiple series.<sup>7</sup> The main concern with this procedure is the fact that the vagina is placed in an exaggerated horizontal position, which increases force on the anterior compartment with increases in abdominal pressure. This is especially likely if a concomitant anti-incontinence procedure is performed. This nonphysiologic axis likely results in a higher rate of cystocele formation, reported at around 20% to 30%.<sup>8</sup> Other complications include hemorrhage, vaginal shortening, sexual dysfunction, and buttocks pain.

### Posterior IVS vault suspension

Introduced as the infracoccygeal sacropexy, the posterior intravaginal slingplasty (Posterior IVS, Tyco/U.S. Surgical, Norwalk, CT) is a novel minimally invasive technique using a polypropylene tape for treating vaginal vault prolapse in a fashion analogous to the anti-incontinence tension-free vaginal tape procedure. This procedure recreates a central suspensory ligament at the level of the ischial spines, analogous to the cardinal ligaments, with a synthetic tape to restore vault support.

For the posterior intravaginal slingplasty, a posterior vaginal dissection is performed to the level of the vaginal apex. The tape is placed through bilateral pararec-



**FIGURE 7.**  
 (A) Apogee system.  
 (B) System being placed with mesh arms through pararectal incisions and mesh secured to the vaginal apex. Panel A reproduced with permission from American Medical Systems, Inc.

tal incisions about 3 cm lateral and posterior to the anus. A metal tunneller is guided through the levator muscles and into the endopelvic fascia over the iliococcygeus muscle or immediately anterior to the ischial spine and sacrospinous ligament. The tape is secured to the vaginal apex and adjusted to provide vault support.

Concerns have been raised about the resultant vaginal length and risk of rectal injury. Our short-term experience is promising, with vaginal lengths of 7 to 8 cm and no rectal injuries.<sup>9</sup>

#### Apogee vaginal vault suspension

The Apogee system (American Medical Systems, Minnetonka, MN) represents the next generation in vault suspension. Neoligaments analogous to the cardinal ligaments are created by anchoring graft arms at sites adjacent to the ischial spines and under the arcus tendineus (**Figure 6**).

The pararectal space is accessed in a fashion similar to the sacrospinous ligament fixation. The ischial spine and arcus tendineus are then palpated. A modified SPARC needle is passed through bilateral pararectal incisions 3 cm lateral and 3 cm posterior to the anus, guided through the ipsilateral levators, and then passed laterally through the iliococcygeus muscle, anchoring to the white line at the level of the ischial spines. The insertion point for the polypropylene mesh arms with attached graft (polypropylene mesh or porcine dermis) is 0.5 to 1 cm anterior to the ischial spine through the white line. The graft arms are

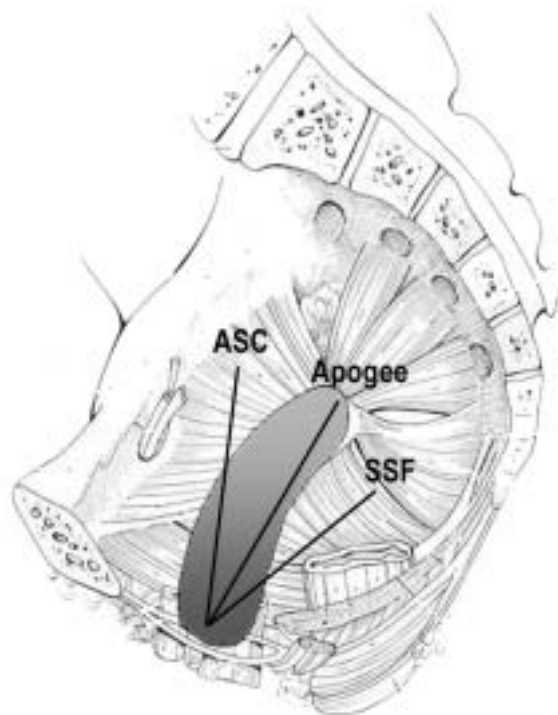
attached with small-profile connectors to the needles and are brought out through the para-anal incisions. The attached graft is then secured to the apex proximally and to the perineal body distally with interrupted delayed absorbable sutures (**Figure 7**). Central support of the vaginal apex running from ischial spine to ischial spine is thus recreated. The resultant vaginal axis is physiologic and vaginal length is normalized (**Figure 8**). The attached synthetic (soft polypropylene) or biologic (non-cross-linked porcine dermis) graft will provide posterior vaginal wall support.

Short-term experience from multicenter use has been very promising, with resultant vaginal lengths of 8 cm and no significant recurrence of apical or posterior wall prolapse.<sup>10</sup> Combining apical and posterior wall repairs allows for efficient use of operating room time. Concomitant use with the Perigee system (American Medical Systems, Minnetonka, MN) allows for correction of coexistent anterior vaginal wall prolapse.

#### Abdominal sacrocolpopexy

Suspension of the vaginal apex through an abdominal incision to the sacral promontory using a graft bridge (**Figure 9**) is considered by most surgeons to be the gold-standard procedure for vaginal vault prolapse. Although this procedure requires an abdominal incision, the resultant anatomy carries the greatest longevity and least risk of sexual dysfunction and dyspareunia.<sup>11</sup>

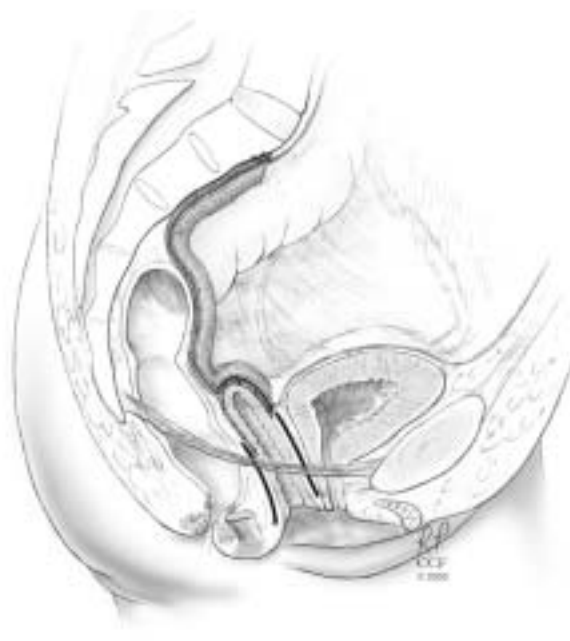The procedure entails performing an abdominal incision and exposing the sacral promontory by incising



**FIGURE 8.** Differences in the vaginal axis following sacrocolpopexy (ASC), the Apogee procedure, and sacrospinous fixation (SSF).

ing the peritoneum between the right ureter and the sigmoid colon. The periosteum is cleared of any connective tissue. Two or three sutures (2-0 polypropylene) are then placed through the periosteum at the level of the L1 vertebra. The vaginal apex can be identified with the obturator of an end-to-end anastomosis rectal tool. We prefer the operator's hand for better identification of the vaginal apex. The peritoneum and bladder are dissected off of the anterior vaginal wall. Along the posterior vaginal wall, any fascial defects are identified and the rectal reflection is clearly noted.

Grafting for the vault suspension should be done with a synthetic polypropylene graft. It should have a long arm (4 to 5 cm) for the posterior wall and a shorter arm (2 to 3 cm) for the anterior vaginal wall. This can be fashioned from a standard 10 cm × 13 cm piece of polypropylene mesh folded in half. Typically, three rows of 2-0 polypropylene sutures are placed along the posterior wall of the vagina and two rows along the anterior wall. Once these are secured to the graft, the graft can be suspended to the sacral promontory with minimal tension. Before suspending the graft, the posterior cul-de-sac should be obliterated either by a uterosacral ligament plication or by the Halban/Moskowitz technique. If a biologic graft is



**FIGURE 9.** Abdominal sacrocolpopexy. A polypropylene bridge is placed from the sacral promontory to the vaginal apex in continuity with anterior and posterior wall fascia.

used for this technique, the reported failure rate is significantly increased.<sup>12</sup>

Once the vault has been suspended, any additional necessary reconstructive procedures can be performed. These typically include paravaginal repair as well as posterior colporrhaphy.

Follow-up in most studies of abdominal sacrocolpopexy has ranged from 6 months to 3 years. The success rate ranged from 78% to 100% when defined as lack of apical prolapse postoperatively and from 58% to 100% when defined as no postoperative prolapse.<sup>13</sup>

The most concerning complications include life-threatening bleeding from the sacral promontory and postoperative ileus. The risk of bleeding can be minimized by the use of bone anchors on the sacral promontory (Straight-In System, American Medical Systems, Minnetonka, MN).

#### ■ SUMMARY

Reconstructive surgeons should be familiar with the identification and treatment of vaginal vault prolapse. Most utilized techniques can be effective in terms of suspension of the vaginal apex. New technology has allowed for the performance of vaginal-approach techniques with increasingly physiologic anatomic and functional outcomes (**Figure 8**).

## ■ REFERENCES

1. **Stepp K, Barber MD.** Genital anatomic correlates. In: *Pelvic Floor Dysfunction: A Multidisciplinary Approach*. Davila GW, Wexner SD, Ghoniem G, eds. London: Springer Verlag; 2005.
2. **Webb MJ, Aronson MP, Ferguson LK, Lee RA.** Posthysterectomy vaginal vault prolapse: primary repair in 693 patients. *Obstet Gynecol* 1998; 92:281–285.
3. **Barber MD, Visco AG, Weidner AC, Amundsen CL, Bump RC.** Bilateral uterosacral ligament vaginal vault suspension with site-specific endopelvic fascia defect repair for treatment of pelvic organ prolapse [see comment]. *Am J Obstet Gynecol* 2000; 183:1402–1410.
4. **Shull BL, Capen CV, Riggs MW, Kuehl TJ.** Bilateral attachment of the vaginal cuff to iliococcygeus fascia: an effective method of cuff suspension. *Am J Obstet Gynecol* 1993; 168:1669–1674.
5. **Maher CE, Murray CJ, Carey MP, Dwyer PL, Ugoni AM.** Iliococcygeus or sacrospinous fixation for vaginal vault prolapse. *Obstet Gynecol* 2001; 98:40–44.
6. **Morley GW, DeLancey JOL.** Sacrospinous ligament fixation for eversion of the vagina. *Am J Obstet Gynecol* 1988; 158:872–881.
7. **Guerette N, Davila GW.** Sacrospinous fixation: does reinforcement of the vaginal vault improve outcome? [abstract]. *Int Urogynecol J* 2003; 12(Suppl 1):S69.
8. **Pollak JT, Togami J, Davila GW, Ghoniem G.** Vaginal axis and vault position following vaginal vault suspension [abstract]. *J Pelvic Med Surg* 2004; 10(Suppl 1):S14–S15.
9. **Davila GW, Miller D.** Vaginal vault suspension using the posterior IVS technique [abstract]. *J Pelvic Med Surg* 2004; 10(Suppl 1):S39.
10. **Davila GW, Beyer R, Moore R, Del Rio S.** Restoration of vaginal apical and posterior wall support with the Apogee system [abstract]. *Int Urogynecol J* 2005; 16(Suppl 2):S118.
11. **Benson JT, Lucente, V, McClellan E.** Vaginal versus abdominal reconstructive surgery for the treatment of pelvic support defects: a prospective randomized study with long-term outcome evaluation. *Am J Obstet Gynecol* 1996; 175:1418–1422.
12. **Culligan PJ, Blackwell L, Goldsmith LJ, et al.** A randomized controlled trial comparing fascia lata and synthetic mesh for sacral colpopexy. *Obstet Gynecol* 2005; 106:29–37.
13. **Nygaard IE, McCreery R, Brubaker L, et al.** Abdominal sacrocolpopexy: a comprehensive review. *Obstet Gynecol* 2004; 104:805–823.