



DAVID Z. ROSE, MD

Department of General Internal
Medicine, Cleveland Clinic

NAVIN KEDIA, DO

The University of Arizona Sarver
Heart Center, Tucson

JESSE T. JACOB, MD

Division of Infectious Diseases,
Emory University School of Medicine,
Atlanta, GA

J. WALTON TOMFORD, MD

Department of Infectious Diseases,
Cleveland Clinic

The Clinical Picture

A 48-year-old man with acute, 'knife-like' rectal pain

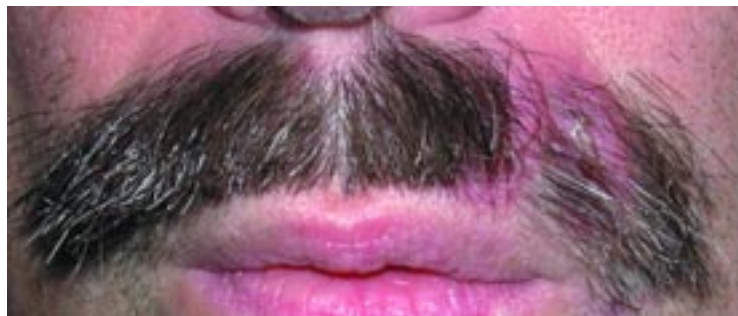

FIGURE 1

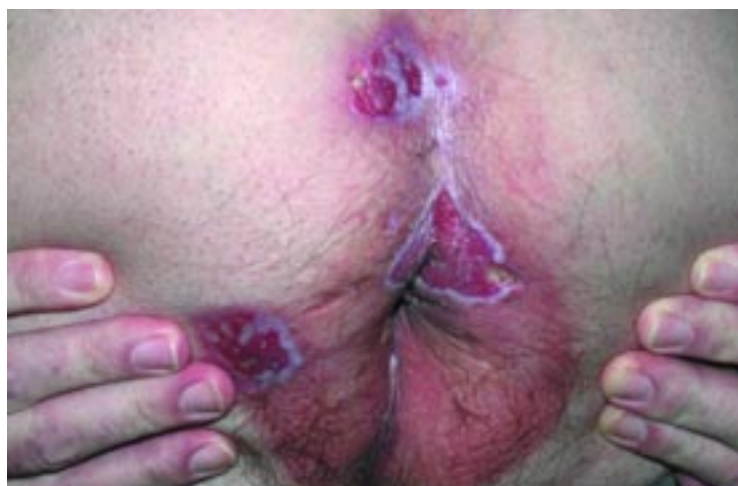

FIGURE 2

A 48-YEAR-OLD WHITE MAN presents to the emergency department with acute, excruciating rectal pain, which he describes as “knife-like” and which has lasted for 15 straight hours. He also reports moderate hematochezia and an episode of syncope, both of which occurred at the onset of the rectal pain. He is admitted to the hospital on

the internal medicine service.

He says that over the past 9 months he has had incessant diarrhea, low-grade fever, and anorexia, and has lost 90 pounds. Physicians at other hospitals had diagnosed possible Crohn disease and had prescribed mesalamine (eg, Asacol), prednisone, metronidazole (Flagyl), and ciprofloxacin (Cipro), which gave mild relief.

■ PHYSICAL AND LABORATORY FINDINGS

A previous workup included colonoscopy, revealing internal hemorrhoids, a hyperplastic cecal polyp, patchy colitis, and edema with hyperemia. Colon biopsy revealed mild chronic inflammation and focal acute cryptitis.

He has also had white oral plaques, diagnosed as thrush, and recurrent hematochezia, diagnosed as hemorrhoid flares.

On physical examination, his temperature is 38.5°C (101.3°F); his heart rate is 94 beats per minute while seated and 116 standing; blood pressure is 154/97 mm Hg seated and 139/83 mm Hg standing.

His upper lip has an erythematous papular eruption (FIGURE 1), and his oropharynx is covered with white plaques. Funduscopic and cardiopulmonary examinations are normal, but palpation of his abdomen reveals moderate tenderness in a diffuse pattern. Rectal examination reveals a large, diamond-shaped, erythematous area with scattered ulcerations (FIGURE 2).

His white blood cell count is $2.6 \times 10^9/L$ (normal range 4.5–11.0), and his hemoglobin concentration is 12.0 g/dL (normal range 14.0–17.5).



Q: What is the likely cause of the papillary lip eruption?

- Bacterial abscess and cellulitis
- Viral inflammation
- Lip hypertrophy
- Angular or actinic cheilitis
- Cheilosis

A: Direct fluorescent antibody testing and viral culture confirm that the lip inflammation is due to herpes simplex virus infection. Herpes simplex virus is also discovered in intranuclear inclusions in biopsy specimens of the plaque in the patient's gluteal cleft. Biopsy of the patient's anal fissures, however, shows numerous intracellular acid-fast bacilli—*Mycobacterium avium intracellulare* by DNA gene probe—in addition to cytomegalovirus (CMV) inclusions. Serum testing for CMV by polymerase chain reaction reveals 68,263 copies/mL. Stool cultures are positive for *Campylobacter jejuni*.

The patient denies receiving blood transfusions, using intravenous drugs, or getting any tattoos, piercings, acupuncture treatments, or needles. He is married and has two healthy children.

Q: Given the panoply of unusual infections in this man, which is the most likely diagnosis?

- Acquired immunodeficiency syndrome (AIDS)
- Behçet syndrome
- Relapsing Crohn disease
- Systemic lupus erythematosus
- Ulcerative colitis

A: The aforementioned infections all may be explained by undiagnosed AIDS. It is tempting to believe the thrush is from exposure to antibiotics and steroids, but the many infec-

tions coupled with the marked leukopenia mandate further exploration.

Upon more intense and detailed questioning the patient admits to having secret extramarital homosexual encounters. He consents to testing for human immunodeficiency virus (HIV): infection is confirmed by two enzyme-linked immunosorbent assays and a Western blot assay. His CD4 cell count is 6 cells per mL (3%), and his viral load exceeds 400,000 copies per mL.


The patient is discharged home on intravenous ganciclovir (Cytovene) (to treat both CMV and herpes simplex virus infections), oral erythromycin for the *C jejuni* infection, clotrimazole (Mycelex) troches for the thrush, and prophylactic trimethoprim-sulfamethoxazole (Bactrim, Septra) to prevent *Pneumocystis carinii* infection.

He returns to the infectious disease clinic 2 weeks later, at which time he begins antiretroviral therapy with ritonavir (Norvir), atazanavir (Reyataz), tenofovir (Viread), and emtricitabine (Emtriva). After 8 weeks of therapy, his symptoms have abated completely, his CD4 count has increased to 47 (38%), and his viral load has declined by 3 log to 400 copies/mL.

Of note, the patient's wife and children tested negative for HIV.

■ TAKE-HOME POINTS

- Advanced AIDS can mimic inflammatory bowel disease.
- Lack of obvious risk factors for HIV should not discourage a more intensive evaluation if the clinical signs point to this diagnosis.
- Multiple opportunistic infections often arise simultaneously in untreated AIDS.

It should be noted that starting highly active antiretroviral therapy, or HAART, can substantially improve CD4 counts and reduce viral load, even in late-stage AIDS. 

ADDRESS: David Z. Rose, MD, Internal Medicine Residency Program, NA10, Cleveland Clinic, 9500 Euclid Avenue, Cleveland, OH 44195; e-mail rosed@ccf.org.

Test for HIV if the patient has multiple opportunistic infections, even without clear risk factors

Visit our web site at <http://www.cjcm.org>

Contact us by e-mail at ccjm@ccf.org