

**ANDREY S. STOJIC, MD, PhD**

Department of Neurology, Cleveland Clinic

**TAREK MEKHAIL, MD**Department of Hematology and  
Oncology, Cleveland Clinic**BRYAN E. TSAO, MD**Department of Neurology,  
Cleveland Clinic

# Leg weakness in a 66-year-old woman: A common presentation of an uncommon disease

**A** 66-YEAR-OLD WOMAN presents with progressive, painless weakness of the proximal legs, which began 2 years ago. The onset was gradual: at first she had difficulty standing from a sitting position, such as when rising from a chair, but over a 1-year period the weakness progressed to the point where she could no longer stand or walk without assistance. Arm strength is not impaired. Six months before her visit she developed numbness and tingling in the legs to the mid-calf level.

Review of systems reveals she has unintentionally lost 50 pounds over the past 2 years. She reports that her mouth is dry, and she feels light-headed when rising from a sitting or lying position. She denies any oculobulbar symptoms, incontinence, back pain, myalgias, or arthralgias.

Previous evaluations included an electrodiagnostic examination 1 year earlier that suggested a mild motor radiculopathy involving the left L4–S1 roots and segments. At that time, magnetic resonance imaging (MRI) of the lumbar spine showed moderate spondylosis with foraminal narrowing at the L4–S1 levels. A multilevel hemilaminectomy (L4–L5) was performed, but it produced little improvement in her weakness.

She has 80 pack-years of tobacco use. She has no personal or family history of neurologic disorders.

## Physical examination

On physical examination, the patient is cachectic and in a wheelchair. She can stand with assistance but cannot walk.

Blood pressure while sitting is 153/81 mm Hg, heart rate 75; blood pressure while standing is 106/71 mm Hg, heart rate 87. She is alert and appropriate, and her cognition is intact. Cranial nerves II to XII are normal except for a soft voice. She can swallow water normally. She has no ptosis.

Motor examination shows normal tone and muscle bulk throughout. There is no pain to palpation over the spine. Strength in her neck flexors and extensors is graded 4 on the 5-point Medical Research Council scale. She has normal strength in her arms; both her legs are weak, graded 2/5 proximally and 3/5 distally.

Deep tendon reflexes are absent in all four extremities; sustained muscle contraction of the quadriceps muscles resulted in trace patellar reflexes. Vibratory and proprioceptive sensation are diminished in the distal lower extremities, with normal temperature and pin testing. Finger-to-nose testing and evaluation of rapid alternating movements reveal no evidence of cerebellar dysfunction.

## ■ DIFFERENTIAL DIAGNOSIS

**1** Which is the most likely cause of this patient's lower-extremity weakness?

- Infiltrative (metastatic) disease of the lumbar spinal cord
- Amyotrophic lateral sclerosis
- Sensorimotor peripheral neuropathy
- Neuromuscular junction disease
- Inflammatory myopathy

## She has:

- Leg weakness
- Weight loss
- Dry mouth
- Orthostasis
- Diminished sensation in arms and legs

This patient presented with slowly progressive leg weakness (proximal greater than distal) and distal paresthesias. Several red flags were noted on the review of systems, namely significant weight loss, dry mouth, and orthostatic intolerance. The distribution of her weakness points to the lower motor neurons, which extend (proximal to distal) from the spinal cord, anterior horn cells, peripheral nerves, and neuromuscular junction to the muscle. Her associated autonomic symptoms suggest a more systemic disorder.

Let's look at the diagnostic possibilities.

#### **Infiltrative (metastatic) disease of the lumbar spinal cord**

Primary spinal cord tumors in this age group include astrocytoma and ependymoma, while secondary spread occurs in a number of cancers, eg, cancers of the lung and breast and lymphomas. Patients with malignant invasion of the lumbosacral spine can present with cauda equina syndrome, characterized by subacute flaccid leg weakness, incontinence, and pain. In some cases, there is anesthesia in the groin and perineum, with a saddle pattern of sensory loss.<sup>1</sup>

Our patient's course of weakness was more indolent than would be expected from direct cancer spread. In addition, she had more widespread symptoms (sensory disturbance in the arms, dry mouth, and lightheadedness) than could be accounted for by lumbosacral cord disease alone.

#### **Amyotrophic lateral sclerosis**

Amyotrophic lateral sclerosis or progressive motor neuron disease is a relentless neurodegenerative disorder. By definition, it affects both the upper and lower motor neurons. Early in its course there may be a predominance of either upper motor neuron signs (spastic weakness, hyperreflexia) or lower motor neuron signs (flaccid weakness, muscle atrophy, fasciculations).

However, even though amyotrophic lateral sclerosis may initially present with symptoms and signs primarily affecting the bulbar, cervical, or lumbosacral segments, in the end, all are invariably affected.<sup>2</sup> Lumbosacral weakness lasting at least 2 years without any other segmental involvement would be atyp-

ical for amyotrophic lateral sclerosis. Moreover, our patient's distal large-fiber sensory loss (including loss of vibration and proprioceptive sensation) and symptoms of autonomic failure are not consistent with motor neuron disease.

#### **Sensorimotor peripheral neuropathy**

The most common form of sensorimotor peripheral neuropathy involves loss of longer axons, manifesting as distal sensory loss, weakness, and loss of reflexes starting distally and progressing proximally. However, a few notable peripheral neuropathies present with proximal weakness.

**Diabetic amyotrophy** is a self-limited form of lumbosacral plexopathy that presents with weight loss, severe thigh pain, and neurogenic weakness of the anterior thigh muscles. In most cases, pain and weakness become maximal within a few months. The absence of pain and the duration of symptoms in our patient essentially exclude this diagnosis.

**Chronic inflammatory demyelinating polyradiculoneuropathy**, a form of acquired neuropathy due to demyelination (as opposed to axon loss), can present with weakness (proximal greater than distal), areflexia, and mild autonomic failure.<sup>3</sup>

Thus, her differential diagnosis should include this disorder, although a few notable features of her case argue against it. First, her prior electrodiagnostic evaluation did not show features of an acquired demyelinating polyneuropathy. Second, significant weight loss is atypical in this disorder and raises the concern for systemic disease. Third, the incremental response of deep tendon reflexes following sustained muscle contraction is not seen with this disorder.

**Nutritional neuropathies** (eg, vitamin B<sub>12</sub> deficiency) should be considered in any patient with significant weight loss, but the rapid progression over 2 years and lack of significant involvement in her arms relative to the advanced state of disease in her legs make this unlikely.

#### **Neuromuscular junction disease**

Diseases of the neuromuscular junction (the most likely cause of this patient's symptoms)

**Cancer in the lumbosacral spine can cause cauda equina syndrome**

**TABLE 1****Lambert-Eaton myasthenic syndrome and myasthenia gravis**

	LAMBERT-EATON MYASTHENIC SYNDROME	MYASTHENIA GRAVIS
<b>Weakness</b>	Yes, nonfluctuating	Yes, often fluctuating
<b>Diplopia, dysphagia</b>	Rare	Common
<b>Tendon reflexes</b>	Absent or reduced	Normal (even in severe cases)
<b>Autonomic failure</b> (dry mouth, orthostasis, constipation, sluggish pupillary reflexes)	Yes	No
<b>Repetitive nerve stimulation</b>		
Slow	Decrement	Decrement
Fast	Increment	No change
<b>Commonly associated malignancy</b>	Small-cell lung cancer	Thymoma
<b>Associated antibodies</b>	Voltage-gated calcium channel	Acetylcholine receptor

are divided into presynaptic and postsynaptic disorders.

**Lambert-Eaton myasthenic syndrome**, the most common presynaptic disorder, is an autoimmune disease that presents with slowly progressive proximal weakness and loss of tendon reflexes. The finding of weakness of the neck flexors and extensors is sensitive but not specific for either neuromuscular junction disorders or myopathic disorders. However, tendon reflexes tend to be preserved until the end stages of myopathies and preserved in even severe myasthenia gravis (see below), while early areflexia is a pathognomonic feature of Lambert-Eaton myasthenic syndrome. An interesting clinical finding is an increment in previously absent reflexes following 10 seconds of sustained contraction.

Approximately 50% to 70% of cases of Lambert-Eaton myasthenic syndrome are associated with malignancy, most commonly small-cell lung cancer, but cases have also been identified in patients with lymphoproliferative disorders. Other hallmark features are often autonomic such as diminished pupillary reflexes, orthostasis, dry mouth, and constipation.<sup>4</sup>

**Myasthenia gravis** is the prototypical postsynaptic neuromuscular junction disorder. Unlike Lambert-Eaton myasthenic syn-

drome, myasthenia gravis has a predilection for the extraocular and pharyngeal muscles; diplopia, ptosis, and dysarthria are common in myasthenia gravis and rare in Lambert-Eaton myasthenic syndrome.<sup>5</sup> Respiratory failure is another feature seen in myasthenia gravis (TABLE 1).

#### **Inflammatory myopathy**

Inflammatory myopathy or myositis includes the categories of dermatomyositis, polymyositis, and inclusion-body myositis.

Myositis and the collagen vascular diseases can overlap; dermatomyositis is associated with a higher rate of malignancy, while the relationship between polymyositis and malignancy is more variable. All of them feature proximal weakness, except for inclusion-body myositis, which classically presents with very slowly progressive weakness of the anterior thigh muscles and finger flexors.<sup>6</sup>

Our patient does not have any cutaneous stigmata associated with adult-onset dermatomyositis, and her sensory and autonomic symptoms are not consistent with myositis.

#### **■ CASE CONTINUED**

During rehabilitation from her previous hemilaminectomy, our patient had had an acute

**Lambert-Eaton syndrome affects the presynaptic neuromuscular junction; myasthenia gravis is postsynaptic**

episode of dyspnea, and computed tomography (CT) of the chest performed at that time found evidence of hilar adenopathy. Subsequent bronchoscopy with mediastinal biopsy revealed small-cell lung cancer. Staging MRIs of the brain and abdomen were normal. Her vitamin B<sub>12</sub> level, thyroid function, creatine kinase level, and diabetes screening tests were negative.

### ■ DIAGNOSTIC TESTING

**2** Which test should be performed next in this patient?

- MRI of the lumbar spine
- Electrodiagnostic evaluation with repetitive nerve stimulation
- MRI of the brain
- MRI of the pelvis
- Muscle biopsy

#### MRI of the lumbar spine

Given her recent history of back surgery and a preoperative MRI that did not show significant compression of the neural elements, a repeat MRI would be of little value.

#### Electrodiagnostic examination with repetitive nerve stimulation

Electrodiagnostic evaluation with repetitive nerve stimulation is the best choice.

This test is composed of three basic components: sensory nerve conduction, motor nerve conduction, and direct needle electrode examination of muscles. In this way, the integrity of the peripheral nerves, neuromuscular junction, and muscles is assessed.

Repetitive nerve stimulation examines the response of muscles by measuring the compound muscle action potential or area under the curve with trains of nerve stimulation (usually two to four serial stimulations) given at frequencies of 2 to 4 Hz.<sup>7</sup> Normally, stimulation of a motor nerve results in release of sufficient amounts of acetylcholine at the neuromuscular junction to generate an action potential, thereby leading to muscle contraction and a compound muscle action potential. With repetitive stimulation, normal individuals maintain efficient acetylcholine transmission and never go below the so-called safety threshold necessary to generate an action potential. Thus, serial stimulation leads to a

compound muscle action potential that is uniform in appearance and size.

In patients with neuromuscular disease, impairment in the release of acetylcholine (as in Lambert-Eaton myasthenic syndrome) or in the ability of acetylcholine to bind on the muscle membrane (as in myasthenia gravis) leads to suboptimal activation of the muscle. This manifests itself as decreasing amplitude in the compound muscle action potential with successive electrical stimulation, known as a decremental response. However, if the frequency of stimulation is increased to 30 Hz or more (the equivalent firing frequency of voluntary muscle contraction), the compound muscle action potential in patients with Lambert-Eaton myasthenic syndrome (but not myasthenia gravis) will increase by at least 100%, and sometimes greater than 200%: this is known as an abnormal incremental response. This response is due to increased release of acetylcholine into the neuromuscular junction and improved activation of the muscle.<sup>8</sup> The incremental response is the classic electrodiagnostic feature of a disorder of presynaptic neuromuscular transmission.

Accurate electrodiagnostic assessment of neuromuscular junction disorders requires a skilled and experienced physician. Most electrodiagnostic laboratories do not routinely perform repetitive stimulation studies or needle electrode examinations or interpret their meaning in this setting; clinicians should consider referring patients with neuromuscular junction disorders to laboratories at academic centers where the electrodiagnosticians have considerable experience with neuromuscular diseases.

Our patient undergoes electromyography with repetitive nerve stimulation. The repetitive nerve stimulation demonstrates electrodecremental response with low-frequency stimulation (**FIGURE 1**), but higher frequency stimulation (100 Hz) produces a marked increase in the compound muscle action potential (**FIGURE 2**). This confirms the diagnosis of a presynaptic neuromuscular junction disorder such as Lambert-Eaton myasthenic syndrome.

Of note, botulism is another presynaptic disorder in which the electrodiagnostic pic-

**Proximal weakness is evident in all neuromuscular junction diseases**

ture may be very similar to that of Lambert-Eaton myasthenic syndrome. The clinical presentation of botulism, however, is quite different and consists of descending paralysis with a predilection for early oculomotor and bulbar involvement.

Interestingly, our patient was also found to have evidence of severe polyneuropathy (discussed below).

### Other studies

MRI of the brain has no direct role at this point. MRI of the pelvis is reasonable; however, the diagnostic yield would be enhanced if the electrodiagnostic evaluation pointed towards a lumbosacral plexus lesion or if there was a concern for a primary gynecologic or other pelvic malignancy. In myopathies, the role of the electrodiagnostic evaluation is to confirm the diagnosis and help determine which specific muscle might be appropriately affected, to optimize the yield of the muscle biopsy.

### AUTOANTIBODIES AND OTHER DIAGNOSTIC FEATURES

**3** Lambert-Eaton myasthenic syndrome is associated with autoantibodies directed against which protein?

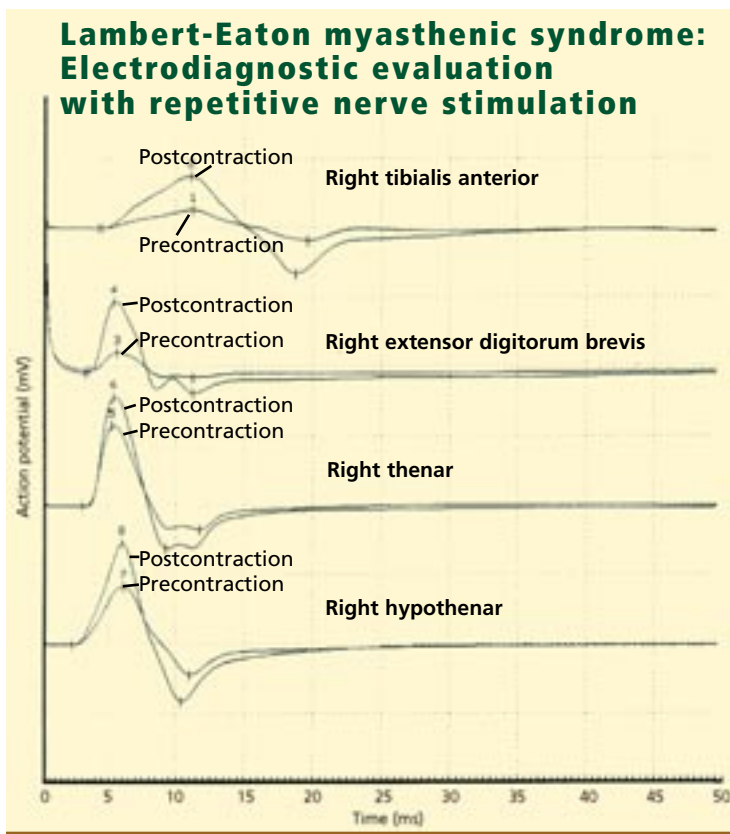
- Nicotinic cholinergic receptors
- Voltage-gated potassium channels
- P/Q-type voltage-gated calcium channels
- M3 subtype muscarinic acetylcholine receptors

### Nicotinic cholinergic receptors


Nicotinic cholinergic receptors are found in all autonomic ganglia (parasympathetic and sympathetic) and also in neuromuscular junctions.<sup>9</sup> Antibodies against postsynaptic acetylcholine receptors are found in most patients with generalized myasthenia gravis, whereas the antiacetylcholine ganglionic receptor antibody (known as alpha-3) has been linked to autonomic neuropathies.<sup>10</sup>

### Voltage-gated potassium channels

Antibodies against voltage-gated potassium channels are described in Isaacs syndrome, a disorder of muscle membrane hyperexcitability.



**FIGURE 1.** Improved motor nerve conduction responses (as reflected in increased compound muscle action potentials) with 10-second, sustained contraction of selected test muscles. Note the significant increase in compound muscle action potentials following sustained muscle contraction that is commonly seen in Lambert-Eaton myasthenic syndrome.



**FIGURE 2.** The classic electrodiagnostic confirmation of Lambert-Eaton myasthenic syndrome with high-frequency repetitive nerve stimulation. The left extensor digitorum was stimulated at 40 Hz, which resulted in significant increase in compound muscle action potential response (reflected as rising slope of the response in the first 8 milliseconds of the tracing).



### P/Q-type voltage-gated calcium channel

Lambert-Eaton myasthenic syndrome is an autoimmune disorder characterized by impaired presynaptic function at the neuromuscular junction.<sup>11</sup> Antibodies against the P/Q-type voltage-gated calcium channel reduce the influx of calcium into the presynaptic terminal, which is key to the release of acetylcholine. Insufficient release of acetylcholine into the neuromuscular junction produces the characteristic features of this disease (TABLE 1). The other features of Lambert-Eaton myasthenic syndrome, including autonomic dysfunction, are due to a similar effect of these autoantibodies on the same voltage-gated calcium channels in the autonomic ganglia.

To some extent, the effects of these autoantibodies can be transiently overcome by sustained contraction of muscles, resulting in transiently induced tendon reflexes, or by high-frequency repetitive stimulation of the nerves, resulting in the incremental response.

### M3 subtype muscarinic acetylcholine receptors

There are at least four subtypes of muscarinic receptor (M1–M4); all are tied mainly to the parasympathetic system. No muscarinic antibody is linked to a neurologic disease.

### ■ WHAT IS CAUSING HER NEUROPATHY?

**4** The patient's sensory loss and the findings of polyneuropathy on her electromyogram can be best explained by which of the following?

- Overlapping paraneoplastic sensory neuropathy
- Vitamin deficiency due to poor nutrition
- History of lumbar spinal disease
- A medication side effect

### Paraneoplastic sensory neuropathy

Many patients with Lambert-Eaton myasthenic syndrome and small-cell lung cancer have overlapping paraneoplastic syndromes. Our patient tested positive for antineuronal antibodies (anti-Hu) in addition to having autoantibodies against the voltage-gated calcium channel.

Several reports have described patients with small-cell lung cancer and Lambert-Eaton myasthenic syndrome with overlapping paraneoplastic syndromes, most commonly progressive cerebellar degeneration, as well as limbic encephalitis, brainstem encephalomyelitis, and sensory neuropathy.<sup>11,12</sup> Thus, these autoantibodies appear to predict an underlying malignancy but do not predict a single paraneoplastic syndrome.

### Vitamin deficiency

Vitamin or nutritional deficiencies (ie, of vitamin B<sub>12</sub>, thiamine, and vitamin E) can cause peripheral neuropathy.

The sine qua non of vitamin B<sub>12</sub> deficiency (also called *subacute combined degeneration*) is a myelopathy (presenting with spastic weakness and hyperreflexia), encephalopathy, and varying degrees of peripheral neuropathy. Our patient had a normal vitamin B<sub>12</sub> level.

Thiamine deficiency is associated with peripheral neuropathy and (in isolation or with other nutritional deficiencies) with neuritic or dry beri-beri and the classic Wernicke-Korsakoff syndrome.

Deficiency of vitamin E causes a slowly progressive spinocerebellar syndrome.

Although these deficiencies are associated with polyneuropathies, none of them would be associated with voltage-gated calcium channel antibodies or the incremental responses seen with electrodiagnostic testing.

### Lumbar spinal disease

Polyneuropathies can be difficult to distinguish from lumbar spinal disease in elderly patients; the sensory responses that indicate whether the disease process is located within the spinal canal (radiculopathy) or distal to it (polyneuropathy) can be absent in patients over age 60. Nevertheless, our patient had sensory symptoms in her arms that could not be explained by lumbar spine disease alone.

### Medication side effect

Although several chemotherapeutic agents can cause sensory neuropathy, including those commonly used in the treatment of small-cell carcinoma (vincristine and cisplatin, among

**3,4-DAP**  
provides only  
symptomatic  
treatment for  
Lambert-Eaton  
syndrome

**TABLE 2****Treatment options in Lambert-Eaton myasthenic syndrome**

THERAPY*	DOSING	COMMENTS AND SIDE EFFECTS
<b>3,4-Diaminopyridine</b> <sup>15,16</sup> (3,4-DAP)	Start at 10 mg by mouth twice a day; increase to goal of 80 mg per day, divided into two or three doses	Effective symptomatic treatment, lasting 3–4 hours Not readily available in United States Paresthesias, gastrointestinal symptoms, and rare seizures at doses of >100 mg/day
<b>Pyridostigmine</b> <sup>17,18</sup>	30–60 mg by mouth three times a day	Limited efficacy but may prolong effect of 3,4-DAP when used in conjunction Fasciculations, bradycardia, gastrointestinal symptoms (diarrhea, abdominal pain).
<b>Prednisone</b> <sup>19</sup>	Start at 1–1.5 mg/kg daily	Good efficacy Well-known side effects with long-term use
<b>Azathioprine</b> <sup>20</sup>	Titrate to 2.5 mg/kg daily	Moderate efficacy Used to treat autonomic-predominant Lambert-Eaton myasthenic syndrome
<b>Cyclosporine</b> <sup>20</sup>	3–4 mg/kg	Modest efficacy for patients failing to respond to azathioprine
<b>Intravenous immunoglobulin</b> <sup>21,22</sup>	400 mg/kg/day for 5 days, then 400–1,000 mg/kg/monthly	Limited studies; probably moderately effective Anaphylaxis, thromboembolism, stroke, aseptic meningitis
<b>Plasma exchange</b> <sup>20</sup>	No established guidelines We use every-other-day exchanges for 5–7 total treatments (which exchanges the equivalent of total body plasma)	Limited studies; probably good efficacy Risks of catheter placement, line infection, hemodynamic instability in patients at risk

\*See Maddison and Newsom-Davis<sup>23</sup> for meta-analysis review of current treatment options.

others), our patient was not taking these at the time of her diagnosis.

### ■ HER DIAGNOSIS

Paraneoplastic Lambert-Eaton myasthenic syndrome with associated sensory neuropathy due to small-cell carcinoma of the lung.

### ■ TREATMENT

**5** Which is the most appropriate treatment for Lambert-Eaton myasthenic syndrome in this patient?

- Start oral cyclosporine 3 mg/kg
- Start oral azathioprine 2.5 mg/kg
- Give a course of intravenous

immunoglobulin for 1 month and then treat her underlying malignancy

- Treat the underlying malignancy and provide graded medical therapy directed against Lambert-Eaton myasthenic syndrome

Treatment of the patient's cancer is the first step in management. A small case series has shown that cancer treatment produces significant improvement of symptoms in patients with paraneoplastic Lambert-Eaton myasthenic syndrome.<sup>13,14</sup>

Specific treatments for Lambert-Eaton myasthenic syndrome are listed in **TABLE 2**.<sup>15–23</sup>

First-line symptomatic treatment includes 3,4-diaminopyridine (3,4-DAP), which inhibits

presynaptic voltage-gated potassium channels, thus prolonging the action potential duration. It has been shown in placebo-controlled trials to improve the symptoms of Lambert-Eaton myasthenic syndrome significantly, but it is not approved by the US Food and Drug Administration and is available only at tertiary-care neuromuscular centers that have an investigational drug approval for its use.<sup>15,16</sup>

Pyridostigmine<sup>17,18</sup> is an acetylcholinesterase inhibitor primarily used in myasthenia gravis. Pyridostigmine works by increasing available acetylcholine in the synaptic cleft, thereby increasing the probability of binding to muscle membrane receptors and of muscular contraction. For most patients with Lambert-Eaton myasthenic syndrome, pyridostigmine alone produces little improvement. However, when taken together with 3,4-DAP, pyridostigmine appears to prolong the effects of 3,4-DAP and thus may serve as a useful adjuvant.

In summary, the effects of 3,4-DAP for Lambert-Eaton myasthenic syndrome are equivalent to the effects of pyridostigmine for myasthenia gravis: both are short-acting therapies and do not treat the underlying disease. The side effects of these medications are listed in TABLE 2.

Immunomodulating therapy is required for patients with Lambert-Eaton myasthenic syndrome who do not benefit from 3,4-DAP or pyridostigmine alone. The decision when to initiate such treatment, especially in patients with malignancy, is difficult and should be made in concert with the patient, the treating oncologist, and the neurologist. Prednisone and azathioprine are frequently used in patients with nonparaneoplastic and paraneoplastic Lambert-Eaton myasthenic syndrome.<sup>18,19</sup> Prednisone has shown moderate benefit, although no data from randomized control trials are available. Azathioprine has also demonstrated modest benefit for patients who do not respond to steroids or who cannot tolerate their side effects. Cyclosporine has modest benefit in patients failing to respond to azathioprine.<sup>20</sup> Thus, these choices would be inappropriate as initial therapy.

In our institution, patients with mild Lambert-Eaton myasthenic syndrome who are still ambulatory are generally treated with 3,4-DAP first, with or without pyridostig-

mine. For those with greater disability or weakness, prednisone 1.0 to 2.0 mg/kg is given orally once in the morning along with a histamine<sub>2</sub> receptor antagonist. In cases of autoimmune Lambert-Eaton myasthenic syndrome, azathioprine is either started at the same time as prednisone or delayed until subsequent prednisone taper results in recurrence of weakness.

In severe cases, nonrandomized data support the use of plasma exchange to treat Lambert-Eaton myasthenic syndrome, although its efficacy is moderate and often less dramatic than in myasthenia gravis.<sup>20</sup>

Intravenous immunoglobulin is another option: a small placebo-controlled study in 10 patients with nonparaneoplastic Lambert-Eaton myasthenic syndrome demonstrated improved strength and reduction in serum levels of voltage-gated calcium channel after two treatments with intravenous immunoglobulin 1 g/kg. The effects were maximal at 2 to 4 weeks, but declined by 8 weeks. In general, there are no guidelines for long-term use of intravenous immunoglobulin in Lambert-Eaton myasthenic syndrome, and treatment should be designed specifically for each patient.

We recommend plasma exchange as the initial therapy for severe cases. If there is a contraindication such as hemodynamic instability or venous access, then intravenous immunoglobulin is a reasonable alternative.

In our patient, both plasma exchange or intravenous immunoglobulin are appropriate therapies, but only if they are given in conjunction with cancer-related treatment.

### Drugs that adversely affect Lambert-Eaton syndrome

As with other myasthenic syndromes, the symptoms of Lambert-Eaton myasthenic syndrome may worsen when patients are exposed to new medications. Some medications can exacerbate myasthenic symptoms. Interferon- $\alpha$ , botulinum toxin, and D-penicillamine are absolutely contraindicated. Neuromuscular blocking agents, aminoglycosides, quinine, calcium channel blockers, and beta-blockers, as well as quinidine, procainamide, and magnesium salts, are relatively contraindicated.

**The severity of Lambert-Eaton syndrome is not affected by tumor volume**





## Neurologic prognosis

O'Neill et al<sup>24</sup> reported in 1988 that 18 of 25 patients with paraneoplastic Lambert-Eaton myasthenic syndrome died an average of 10 months after diagnosis, most from malignancy-related complications. Only 3 of the 5 surviving patients had complete responses to treatment of their malignancy 3 to 4 years after tumor diagnosis. Chalk et al,<sup>25</sup> in 1990, demonstrated a similar improvement in neurologic symptoms with combined treatment of the underlying malignancy and Lambert-Eaton myasthenic syndrome.

These findings support the conclusion that patients with paraneoplastic Lambert-Eaton myasthenic syndrome whose underlying malignancy responds to therapy may expect improvement in their neurologic symptoms as well.

For patients with nonparaneoplastic or autoimmune Lambert-Eaton myasthenic syndrome, a recent study of 47 patients showed that medical therapy (including 3,4-DAP, prednisone, or azathioprine in various combinations) improved muscle strength and electrophysiologic variables in 88% of patients. Twenty percent of these patients achieved a sustained, complete medical remission, though only 4 were able to come off immunosuppressive therapy.<sup>26</sup>

Overall, these data suggest that medical treatment of Lambert-Eaton myasthenic syndrome (whether or not associated with malignancy) can provide substantial benefit to patients.

## Cancer prognosis in paraneoplastic Lambert-Eaton myasthenic syndrome

Lambert-Eaton myasthenic syndrome may precede the diagnosis of small-cell lung can-

cer, and it can be associated with either limited or extensive stages of the disease. In contrast to the paraneoplastic endocrine syndromes, in which successful treatment of the tumor effectively controls the symptoms, the severity of the neurologic symptoms is unrelated to the tumor volume and may not improve despite control of the malignancy. Likewise, the prognosis of patients with small-cell lung cancer does not appear to be affected by the presence or the absence of neurologic paraneoplastic syndromes.

## ■ CASE FOLLOW-UP

Our patient received four cycles of carboplatin and etoposide (VP-16) and had tumor remission on subsequent chest CT scans.

Initial therapy for Lambert-Eaton myasthenic syndrome included prednisone 60 mg every morning and pyridostigmine. The institutional review board granted approval for using 3,4-DAP; however, the patient had poor compliance and the pyridostigmine and 3,4-DAP were eventually stopped because they did not produce significant benefit.

Because her weakness continued, plasmapheresis was started. She received exchanges every other day for 7 days, once a week for 2 months, then every other week for 1 month. Her strength improved significantly, and prednisone was tapered at her request.

Two years after diagnosis, she continues to have weakness thought to be secondary to Lambert-Eaton myasthenic syndrome and deconditioning, but she is able to ambulate at home and is better overall. To date, she has no evidence of recurrence of her malignancy. ■

## ■ REFERENCES

1. **Brazis PW, Masdeu JC, Biler J.** Localization in Clinical Neurology, 4th ed. Philadelphia: Lippincott Williams & Wilkins, 2001:101–127.
2. **Pioro EP.** Motor neuron disorders. In: Levin KH, Lüders HO, editors. Comprehensive Clinical Neurophysiology. Philadelphia: W.B. Saunders, 2000:235–250.
3. **Bosch EB, Smith BE.** Disorders of peripheral nerves. In: Bradley WG, Daroff RB, Fenichel GM, Jankovic J, editors. Neurology in Clinical Practice, 4th ed. Philadelphia: Butterworth-Heinemann, 2004:2299–2402.
4. **Sanders DB, Howard JF Jr.** Disorders of neuromuscular transmission. In: Bradley WG, Daroff RB, Fenichel GM, Jankovic J, editors. Neurology in Clinical Practice, 4th ed. Philadelphia: Butterworth-Heinemann, 2004:2441–2462.
5. **Wirtz PW, Sotodeh M, Nijhuis M, et al.** Difference in distribution of muscle weakness between myasthenia gravis and the Lambert-Eaton myasthenic syndrome. *J Neurol Neurosurg Psychiatry* 2002; 73:766–768.
6. **Amato AA, Brooke MH.** Disorders of skeletal muscle. In: Bradley WG, Daroff RB, Fenichel GM, Jankovic J, editors. Neurology in Clinical Practice, 4th ed. Philadelphia: Butterworth-Heinemann, 2004:2463–2510.
7. **Chiou-Tan F, Tim RW, Gilchrist JM, et al.** Literature review of the usefulness of repetitive nerve stimulation and single fiber EMG in the electrodiagnostic evaluation of patients with suspected myasthenia gravis or Lambert-Eaton myasthenic syndrome. AAEM Quality Assurance Committee, American Association of Electrodiagnostic Medicine. *Muscle Nerve* 2001; 24:1239–1247.

New free online supplement to the  
*Cleveland Clinic Journal of Medicine*:

## Proceedings of the 2nd Annual Cleveland Clinic Perioperative Medicine Summit

Program • IMPACT Consults • Abstracts

Electronic Supplement 1, Volume 73,  
September 2006

Now available at:  
[www.ccjm.org/toc/2006periop.htm](http://www.ccjm.org/toc/2006periop.htm)

### Supplement Editors:

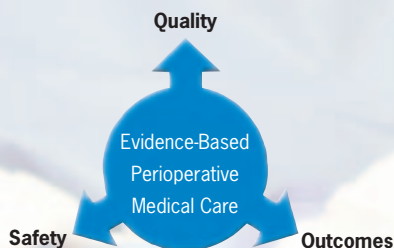Amir K. Jaffer, MD  
Franklin A. Michota, Jr., MD

### Supplement Features:

IMPACT Consults—Brief evidence-based answers to  
perioperative management challenges

Abstracts submitted from across the United States:

- Innovations in Perioperative Medicine
- Perioperative Clinical Vignettes
- Research in Perioperative Medicine



[www.ccjm.org/toc/2006periop.htm](http://www.ccjm.org/toc/2006periop.htm)

Limited quantity of print supplements available.  
To order, e-mail [dunaskk@ccf.org](mailto:dunaskk@ccf.org)

## STOJIC AND COLLEAGUES



8. **Levin KH.** Disorders of neuromuscular junction transmission. In: Levin KH, Lüders HO, editors. *Comprehensive Clinical Neurophysiology*. Philadelphia: W.B. Saunders, 2000:251–267.
9. **van Zwieten PA.** Adrenergic and cholinergic receptors. In: Mathias CJ, Bannister R, editors. *Autonomic Failure: a Textbook of Clinical Disorders of the Autonomic Nervous System*. New York: Oxford University Press, 1999:56–62.
10. **Sandroni P, Vernino S, Klein CM, et al.** Idiopathic autonomic neuropathy: comparison of cases seropositive and seronegative for ganglionic acetylcholine receptor antibody. *Arch Neurol* 2004; 61:44–48.
11. **Lang B, Vincent A.** Autoantibodies to ion channels at the neuromuscular junction. *Autoimmun Rev* 2003; 2:94–100.
12. **Kleopa KA, Teener JW, Scherer SS, Galetta SL, Bird SJ.** Chronic multiple paraneoplastic syndromes. *Muscle Nerve* 2000; 23:1767–1772.
13. **Leonovicz BM, Gordon EA, Wass CT.** Paraneoplastic syndromes associated with lung cancer: a unique case of concomitant subacute cerebellar degeneration and Lambert-Eaton myasthenic syndrome. *Anesth Analg* 2001; 93:1557–1559.
14. **Newsom-Davis J.** Therapy in myasthenia gravis and Lambert-Eaton myasthenic syndrome. *Semin Neurol* 2003; 2:191–198.
15. **McEvoy KM, Windebank AJ, Daube JR, Low PA.** 3,4-Diaminopyridine in the treatment of Lambert-Eaton myasthenic syndrome. *N Engl J Med* 1989; 321:1567–1571.
16. **Sanders DB, Massey JM, Sanders LL, Edwards LJ.** A randomized trial of 3,4-diaminopyridine in Lambert-Eaton myasthenic syndrome. *Neurology* 2000; 54:603–607.
17. **Oh SJ, Kim DS, Head TC, Claussen GC.** Low-dose guanidine and pyridostigmine: relatively safe and effective long-term symptomatic therapy in Lambert-Eaton myasthenic syndrome. *Muscle Nerve* 1997; 20:1146–1152.
18. **Lundh H, Nilsson O, Rosen I.** Treatment of Lambert-Eaton syndrome: 3,4-diaminopyridine and pyridostigmine. *Neurology* 1984; 34:1324–1330.
19. **Streib EW, Rothner AD.** Eaton-Lambert myasthenic syndrome: long-term treatment of three patients with prednisone. *Ann Neurol* 1981; 10:448–453.
21. **Dalakas MC.** Intravenous immunoglobulin in the treatment of autoimmune neuromuscular diseases. *JAMA* 2004; 291:2367–2375.
22. **Bain PG, Motomura M, Newsom-Davis J, et al.** Effects of intravenous immunoglobulin on muscle weakness and calcium-channel autoantibodies in the Lambert-Eaton myasthenic syndrome. *Neurology* 1996; 47:678–683.
20. **Newsom-Davis J, Murray NM.** Plasma exchange and immunosuppressive drug treatment in the Lambert-Eaton myasthenic syndrome. *Neurology* 1984; 34:480–485.
23. **Maddison P, Newsom-Davis J.** Treatment for Lambert-Eaton myasthenic syndrome. *Cochrane Database Syst Rev* 2005; 18:CD003279.
24. **O'Neill JH, Murray MF, Newsom-Davis J.** The Lambert-Eaton myasthenic syndrome. *Brain* 1988; 111:577–596.
25. **Chalk CH, Murray NM, Newsom-Davis J, O'Neill JH, Spiro SG.** Response of the Lambert-Eaton myasthenic syndrome to treatment of associated small-cell lung cancer. *Neurology* 1990; 40:1552–1556.
26. **Maddison P, Lang B, Mill K, Newsom-Davis J.** Long term outcome in Lambert-Eaton myasthenic syndrome without lung cancer. *J Neurol Neurosurg Psychiatry* 2001; 70:212–217.

ADDRESS: Bryan E. Tsao, MD, Department of Neurology, S90, Cleveland Clinic, 9500 Euclid Avenue, Cleveland, OH 44195; e-mail [tsaob@ccf.org](mailto:tsaob@ccf.org).